



## **Osteomyelitis (bone infection): Case study**

### **Osteomielite (infecção do osso): Estudo de caso**

DOI:10.56238/isevjhv2n2-012

Receiving the originals: 03/04/2023

Acceptance for publication: 24/04/2023

#### **Elizangela Gomes Façanha**

Subinspector of the Municipal Guard of Fortaleza.

Graduated in HR management from Universidade Estadual Vale do Acaraú.

Post-graduation "Lato-Sensu" in Nursing in Stomal Therapy by Estacio College.

Post-graduation "Lato-Sensu" in Psychology and mental health by FAMEESP.

Post-graduation "Lato-Sensu" in Public Management by FAMEESP.

Law student at Pitágoras University.

E-mail: eli-facanha29@hotmail.com

#### **ABSTRACT**

Osteomyelite, an infectious orthopedic pathology, constitutes a challenge for physicians orthopedic surgery, but it is difficult to program a valid therapeutic algorithm for each clinical situation, making it imperative to investigate the various aspects related to Its pathophysiology, and the most appropriate treatment protocol Despite several studies We Will demonstrate good results with the available techniques, there is no single approach consensual not that it says respect to the treatment of osteomyelite. In this way, the protocols medical and surgical, complement each other, hair that frequently num doente, is tour both. Cleaning and removing shaved tissue are the first steps of any treatment. Antibiotic medical therapy should be performed in infectious osteomyelites acute, subacute and chronic. Surgical therapy consists of lengthening debridement, Sequestrectomy and, if necessary, subsequent stabilization with a bone graft and coverage with known moles. Therapeutics of CRMO aims to control autoimmunity.

**Keywords:** Health, Infection, Life experience.

#### **1 INTRODUCTION**

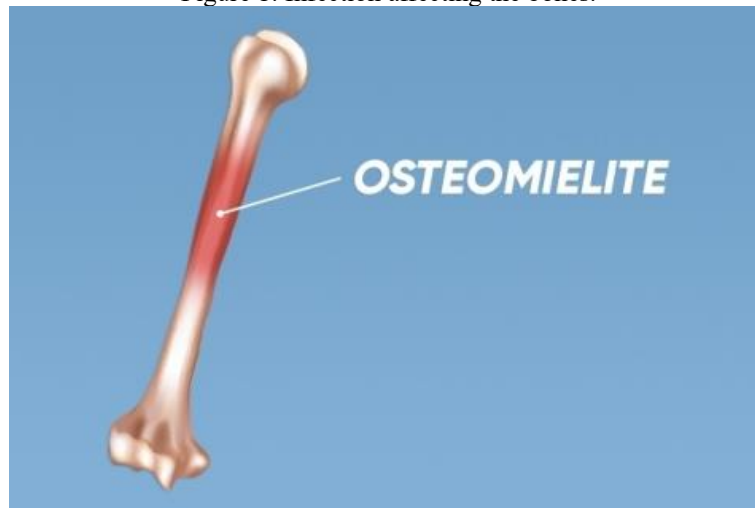Osteomyelitis, an infectious orthopedic pathology, was first described by Hippocrates, who recommended debridement and isolation using sterile materials of exposed fractures, referring to the risk of infection of bone tissue. Currently, despite the emergence of new diagnostic and therapeutic methods, osteomyelitis remains a challenge for orthopedic surgeons due to the lack of clinical trials of recognized scientific quality and the difficulty of programming a valid therapeutic algorithm for each clinical situation.

The need for a timely diagnosis, which allows for the use of treatments that the clinician considers most appropriate, makes it imperative to investigate the existence of strategies that can reduce the occurrence of osteomyelitis, as well as the various aspects related to its thiopathogenesis. The therapeutic options are vast and range from amputation of the infected limb

to surgical techniques that attempt to preserve the anatomy of the bone involved, not forgetting antibiotherapy.

The purpose of this article is to perform a brief theoretical review of the established knowledge about osteomyelitis and to describe the benefits and risks of the available treatments based on the real facts presented here (Figure 1).

Figure 1: Infection affecting the bones.



## 2 CLASSIFICATION

There are different classifications attributed to osteomyelitis, based on several aspects of the pathology. The most accepted one, currently established based on the duration of symptoms (acute, lasting less than two weeks; subacute, lasting between two weeks and three months; and chronic, when symptoms last for more than three months), defines two most frequent clinical entities, Acute Hematogenous Osteomyelitis and Chronic Osteomyelitis, as well as other situations that occur occasionally.

According to its mechanism of installation, osteomyelitis can spread hematogenously (it rarely causes chronic osteomyelitis in adults) or exogenously, the latter being associated with an open fracture, previous surgery (with or without implantation of prosthetic material), or a contiguous infectious source. Osteomyelitis may be associated with peripheral vascular insufficiency or diabetes mellitus. The host response to the disease further divides osteomyelitis into pyogenic and nonpyogenic.



## 2.1 HEMATOGENOUS ACUTE OSTEOMYELITIS

Acute Hematogenous Osteomyelitis is the most common type of bone infection and, as the name implies, has a hematogenous origin.

## 3 EPIDEMIOLOGY

The annual incidence of osteomyelitis is eight per 100,000 in developed countries. There is a downward gradient in incidence from developed to developing countries, with the complement of hygiene measures being identified as the main factor responsible for the decreased incidence in developed countries. It affects mainly the male pediatric population, and has a bimodal distribution affecting children under two years of age and children between eight and 12 years of age.

## 4 ETIOLOGY

The agent involved in most situations is *Staphylococcus aureus*, followed by *Streptococcus pyogenes* and *Streptococcus pneumoniae*. However, in children under the age of four, the most frequently isolated pathogen is the *Kingella Kingae* bacterium. *Salmonella* infections are common in developing countries and in individuals with hemoglobinopathies. It should be noted that there are also rare cases of methicillin-resistant *Staphylococcus aureus* (MRSA) infection, and that these are increasing. Contrary to the last two pathogens mentioned, *Haemophilus Influenza* has decreased considerably since vaccination programs have been put in place.

## 5 PATOGENESIS

In children, the infection usually develops in the metaphysis of the long bones. Concentration of bacteria leads to a local inflammatory reaction. Bone necrosis may then occur, accompanied by the formation of a subperiosteal abscess. This process can evolve to sequestrum, a term that translates as "dead bone", and can also give rise to chronic osteomyelitis.

Due to the existence of blood vessels running through the physis, this infection can spread to the epiphysis in children under the age of two. Consequently, this age group has a risk of limb shortening or angular deformity. When the child reaches two years of age, these vessels usually obliterate and the physis constitutes a barrier that prevents the extension of the infection; however, because the metaphyseal cortex is thicker, in these children there is a greater risk of reaching the diaphysis.

## 6 SYMPTOMATOLOGY

The most commonly reported complaint of patients is functional dysfunction of the affected limb. Pain, erythema and edema are also frequent manifestations, while fever may be present or absent in these situations. More specific complaints such as low back pain may be indicative of more unusual locations of the pathological process, in which case vertebral osteomyelitis could be present.

## 7 DIAGNOSIS

An accurate diagnosis is based on a thorough clinical history and a careful physical examination. The most specific laboratory markers for diagnosis and treatment monitoring are CRP and calcitonin, but the latter comes at a high cost. Other less specific markers are erythrocyte sedimentation rate and white blood cell count, which may be increased particularly if the microorganism involved is MRSA. About 2 to 3 weeks after the onset of symptoms, periosteal reaction and destruction of bone tissue becomes visible on bone X-ray, and the lesions take on the typical appearance of "rat bites".

Scintigraphy can also be useful if a long bone is affected or the location of symptoms is not precise, but the most effective method for diagnosing osteomyelitis is MRI. Confirmation of the diagnosis should also be obtained by percutaneous or fine needle sampling for culture and subsequent antibiogram. If necessary, to confirm the presence of *Staphylococcus aureus* or *Kingella Kingae*, PCR is indicated.

## 8 TREATMENT

All treatments directed at a bone infection should begin with careful debridement of the affected tissues and possibly drainage of abscesses, after which the prescription of an antibiotic is advised, the choice of which should be guided by microbiological cultures, local prevalence of pathogens, and patient characteristics. Usually, clindamycin is administered, targeting *Staphylococcus aureus*, or a cephalosporin, to which *Kingella Kingae* is sensitive.

Vancomycin is the most valid alternative to these drugs, and should be started if the infection is caused by MRSA. Several studies have investigated the appropriate duration of antibiotic therapy, establishing that it should be given for a shorter period of time.

Evidence has emerged, including Grade 2B, suggesting that uncomplicated acute osteomyelitis in children over three months of age should be treated with 3-4 days of intravenous antibiotic therapy and then replaced with oral antibiotics for about 20 days. However, for neonatal



osteomyelitis, there is currently no evidence to change the recommendation of at least four weeks of intravenous antibiotic therapy.

Currently, it is estimated that conservative medical treatment alone is effective, with surgery reserved for situations of abscess drainage or failure of medical therapy. Continuous monitoring of the patient is advised, and C-reactive protein levels should be assessed regularly, as absence of response for 2 to 3 days after initiation of intravenous antibiotic therapy may indicate that the pathogen is resistant to the antibiotic instituted. Finally, among the parameters that should be assessed at the end of therapy is the success in eradicating the infection, the patient's functional status, and the presence or absence of sequelae.

## **9 PROGNOSIS**

Currently it is estimated that the percentage of effectiveness of conservative medical treatment is around 90%. As for mortality, in more than 1000 children with osteomyelitis, there has been one death.

## **10 SUBACUTE HEMATOGENOUS OSTEOMYELITIS**

Subacute osteomyelitis is a more indolent infection and is more difficult to diagnose.

## **11 EPIDEMIOLOGY**

This pathology occurs in about one-third of patients with primary bone infection.

## **12 ETIOLOGY**

The organisms most often involved in this pathological situation are *Staphylococcus aureus*, *Staphylococcus epidermidis*, and *Kingella kingae*.

## **13 PATHOGENESIS (BRODIE'S ABSCESS)**

The most common form of onset is via hematogenous life, however, it may also occur by continuous spread from an infectious focus located in nearby tissues or by direct inoculation caused by a penetrating wound. A localized form of subacute osteomyelitis is called Brodie's abscess.

It occurs most frequently in the long bones of the lower limbs of young adults. It forms mainly in highly vascularized areas, so before physeal closure the metaphysis is most often the affected area; after physeal closure, abscesses mostly appear in the transition zone between the epiphysis and the metaphysis.



## 14 SYMPTOMATOLOGY

The symptoms, as already mentioned, are few and frustrating, but the most frequent symptom is functional limitation. Moderate pain may also be present; in the case of Brodie's abscess, the patient complains mainly of intermittent pain and edema localized to the affected region.

The disease appears to have a biphasic age distribution, often being asymptomatic in children under the age of four and showing a new peak incidence in older children, this time manifesting itself through an increase in temperature and systemic symptoms as well as in adults.

## 15 EVALUATION AND DIAGNOSIS

The evaluation of the patient begins with the detailed collection of the clinical history. Information such as previous focal or systemic infection may raise suspicion of infectious spread to a particular site, whether the event is recent or remote. History of previous trauma that led to a local skin or soft tissue complication is also relevant.

The occurrence of the fracture and its characteristics, such as degree of exposure and treatment instituted (surgery for local cleaning, fracture fixation, debridements, presence of an implant or foreign body), are fundamental in the initial approach to the patient.

## 16 DIAGNOSIS

Again, the diagnosis is based on a careful clinical history and a careful objective examination. Body temperature may be slightly elevated in some patients. At the laboratory level, C-reactive protein measurement is the most important indicator of the presence of subacute osteomyelitis, however, these values, and the white blood cell count, are often normal. The erythrocyte sedimentation rate is often greater than 20 mm/hr.

Radiography usually demonstrates surrounding soft tissue infection and, in the case of an abscess, these are presented as a lytic bone lesion surrounded by sclerosis. Since the differential diagnosis between subacute osteomyelitis and tumor lesions is sometimes difficult, resorting to MRI may be helpful. Blood and infectious tissue cultures should be performed, noting, however, that identification of a microorganism by obtaining cultures on usual media is relatively rare.

Often there is a need for genetic testing using the PCR method to conclude which pathogen is responsible.



## 17 SURGICAL TREATMENT

Surgical approaches in chronic osteomyelitis aim at the mechanical removal of infected and devitalized tissues. In some situations, the patient is not clinically able to proceed with surgical treatment.

It is important to emphasize that the maintenance of bone axial stability, whenever possible, should be preserved.

## 18 TREATMENT

The lesions are initially subject to percutaneous or surgical drainage, and biopsy and curettage are also performed. Treatment is based on the prescription of targeted antibiotherapy, such as cefuroxime and flucloxacillin, and surgery is reserved for aggressive lesions. In this pathology, it was not possible to establish a consensus regarding the duration of parenteral antibiotic regimens, but it should be noted that the duration of parenteral therapy has been reduced to about 4 to 5 days, and is then replaced by oral therapy.

Another issue that remains controversial is the institution of empirical therapy in subacute osteomyelitis before the results of the specimens and antibiogram are obtained.

## 19 PROGNOSIS

Usually, this pathology adopts a benign course, and it is not possible to establish a mortality rate for each study performed.

However, it was possible to establish factors associated with a worse prognosis of the disease, these being: the infecting organism being MRSA or S. Pneumonia, concomitant septic arthritis or abscesses, location of the pathology on the hip, microbiological identification of K.kingae, younger age, and delay in the institution of therapy.

## 20 CLINICAL CASE

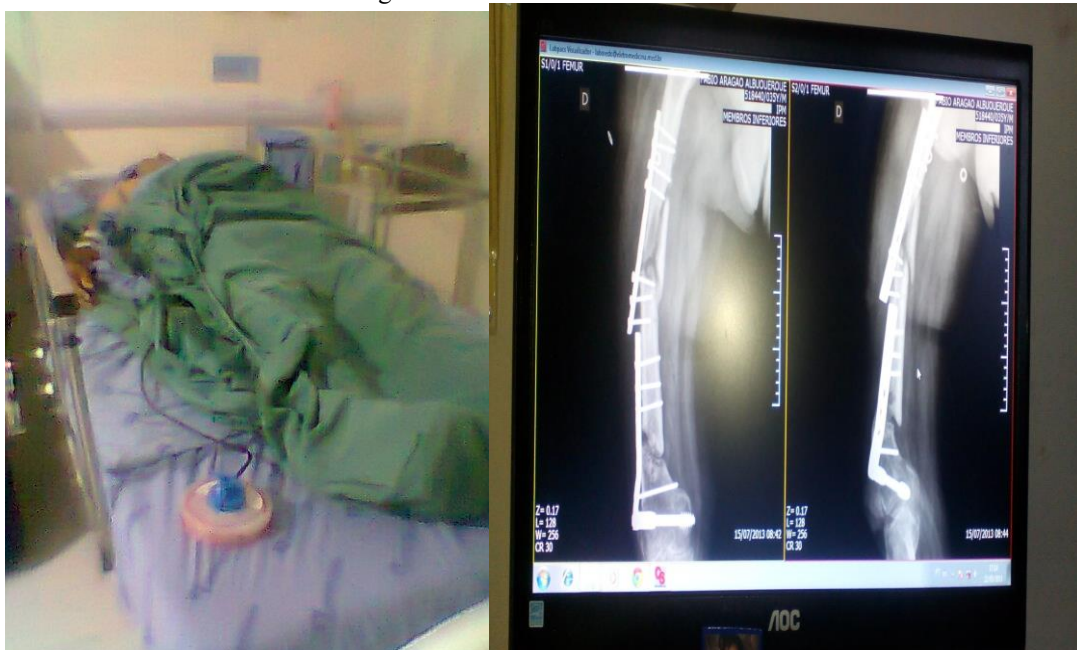### 20.1 IN A LIFE EXPERIENCE

I present here a brief history of emotional suffering, anguish faced as a result of a fracture of the right femur originated from a traffic accident that as soon as it was not treated properly due to negligent medical conduct evolving to a chronic osteomyelitis pseudoarthrosis and osteotomy. Patient affected by traffic accident on November 26, 2011, being to this day, year 2023 in 11 years of treatment and undergone several surgeries to treat infection and reconstruction of bone loss due to necrosis and no prediction of medical discharge.

At the time of the accident in 2011 the patient F.A.A., was 34 years old and several were the complications and triggering of various diseases due to difficulty in locomotion, morbid obesity and emotional and physical suffering before several hospitalizations and surgeries procedures which many were unsuccessful generating irreversible damage to the patient with permanent sequelae of the lower right limb.

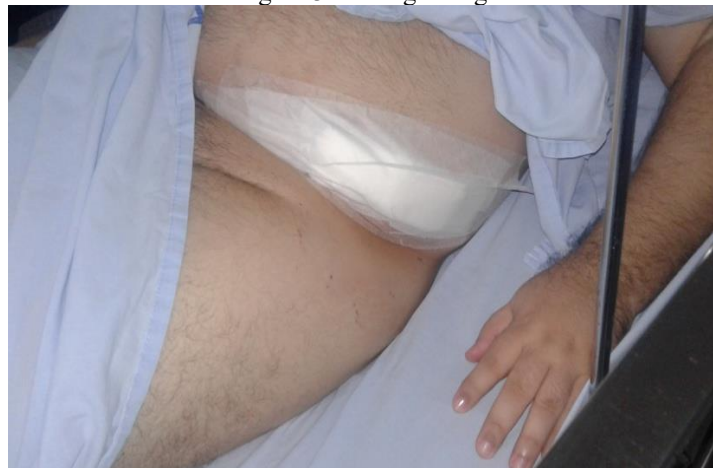Patient F.A.A., with segmental femur fracture due to a traffic accident. Surgery performed in November 2011 placing plates and screws up to the knee (Figure 2).

Figure 2: Femur Plates and Screws.



First bone graft performed in April 2012 due to bone non-consolidation in the right femur. (Figure 3).

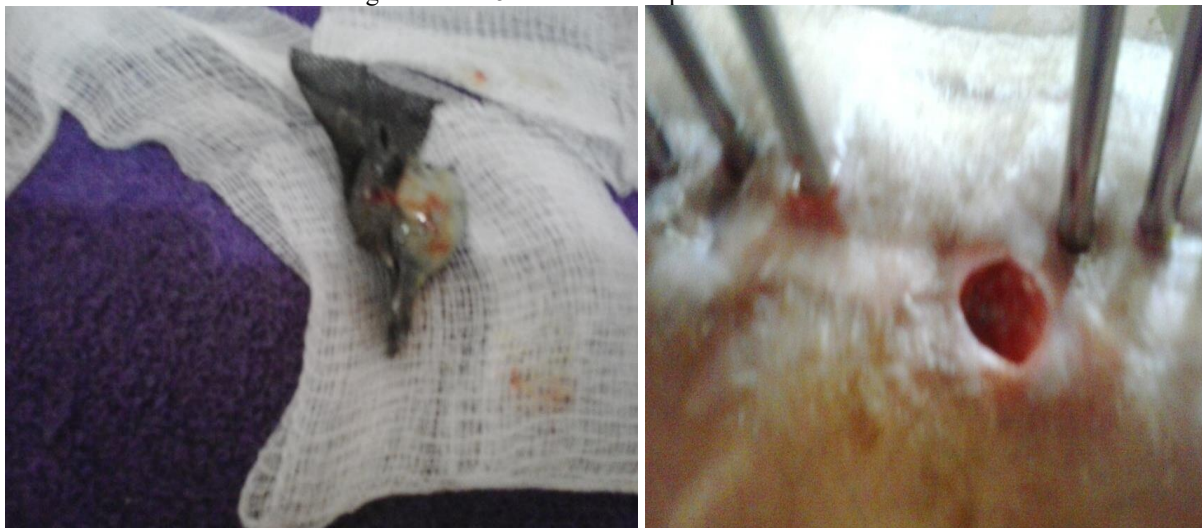
Figure 3: Bone grafting.



Patient already had chronic osteomyelitis and several surgical cleanings and superficial cultures with purulent secretion were performed, these procedures were unsuccessful, because the bone was already necrotic and even so a second bone graft removed from the pelvis was performed in August 2012, that is, new bone was placed where it was necrotic, resulting in a surgical inefficiency and according to the doctor who accompanied him at the time it would be an infection of low virulence and that the body would debilitate, so the bones were necrotic every day. Patient with open holes and fistulas resulting from the bone infection, being used dressing methods such as silvercel an antimicrobial cover and activated charcoal with silver, the activated charcoal absorbs the bacteria, removing them effectively from the lesion bed, resulting in an effective odor control in foul-smelling wounds.

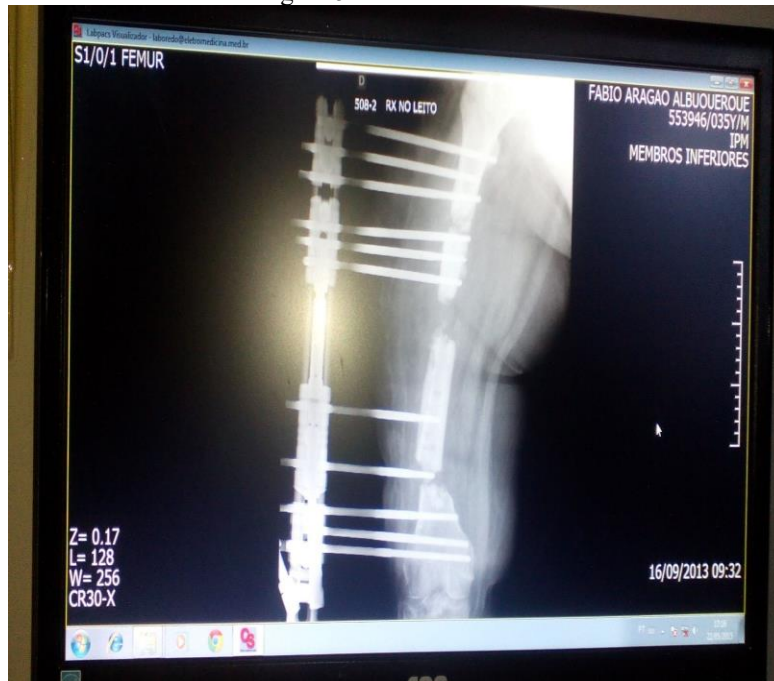The silver impregnated in the charcoal tissue exerts a bactericidal effect on microorganisms, helping to control wound infection (Figures 4 and 5).

Figures 4 and 5: Orifices with purulent secretion.



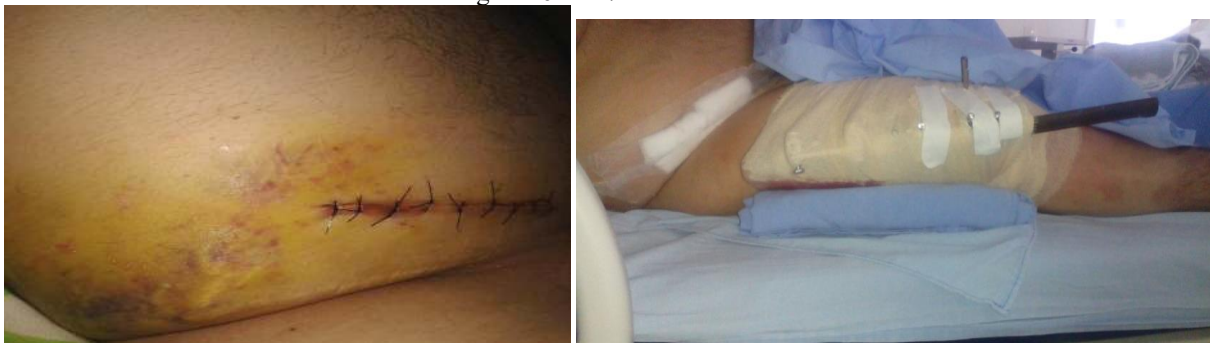Patient in August 2013 after surgery to remove plates and screws and placed external fixator performed the removal of necrotic bone and sent to the laboratory for culture of the same. With considerable shortening of the MID in 12 cm of bone loss verified through scanning of the lower limbs (Figure 5).

Figure 5: External fixator.



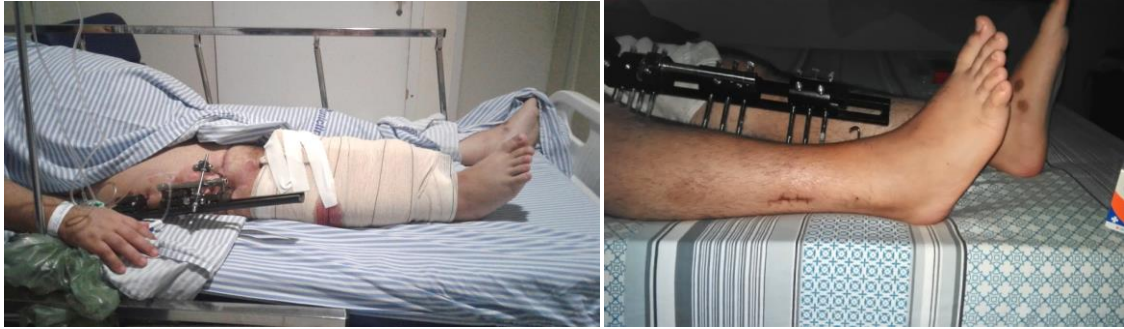Patient in January 2014 performed bone graft taken from the pelvis to begin the process of consolidation and bone reconstruction.(Figures 6 and 7).

Figures 6 and 7: Bone Graft.



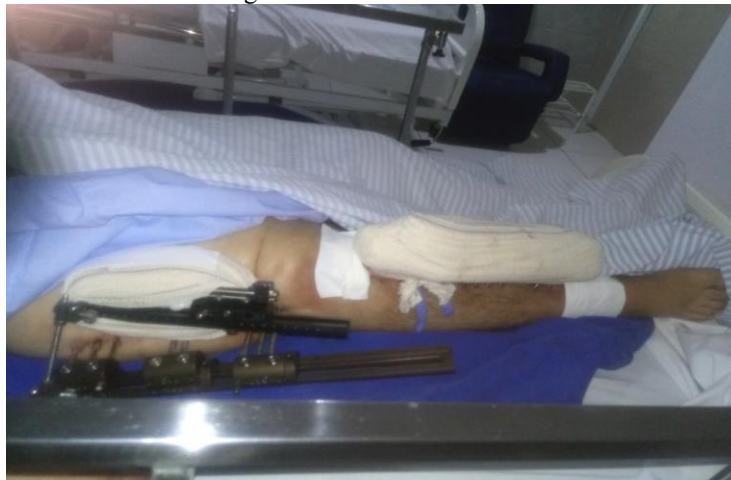Patient in February 2017 was performed the procedure of placing external fixator in the tibia/osteomyelitis due to the degree of shortening 12 cm of bone loss and thus start the stretching process this time in the tibia, because the femur was already very suffering.(Figures 8 and 9).

Figures 8 and 9: External fixator tibia.



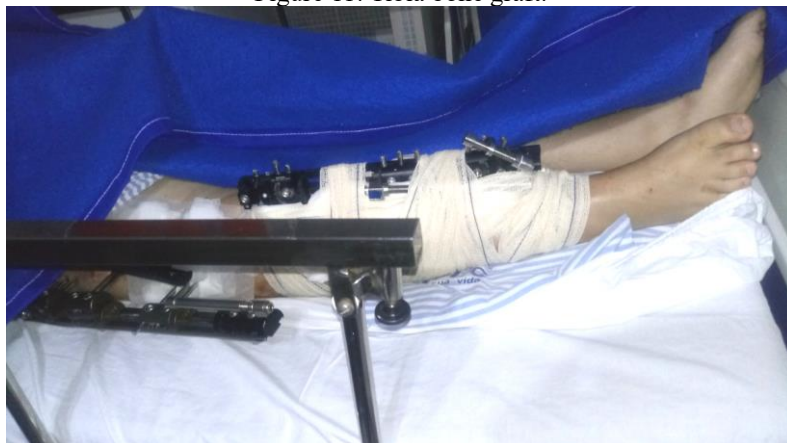Patient in February 2018 there was a need for placement of a second external fixator in the femur for continuity of lengthening and bone reconstruction leaving the patient with three fixators in his right lower MID (Figure 10).

Figure 10: External fixators.



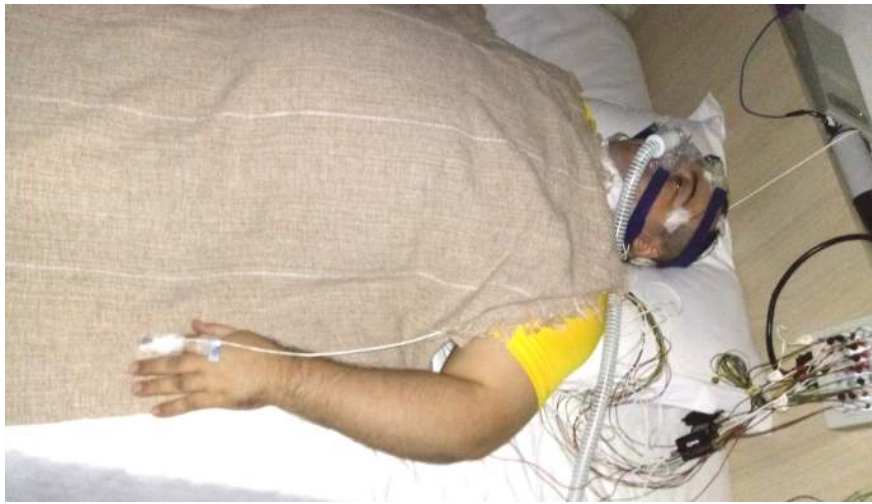Patient in January 2019 bone graft was performed on the tibia for the process of lengthening and bone reconstruction.(Figure 11).

Figure 11: Tibia bone graft.



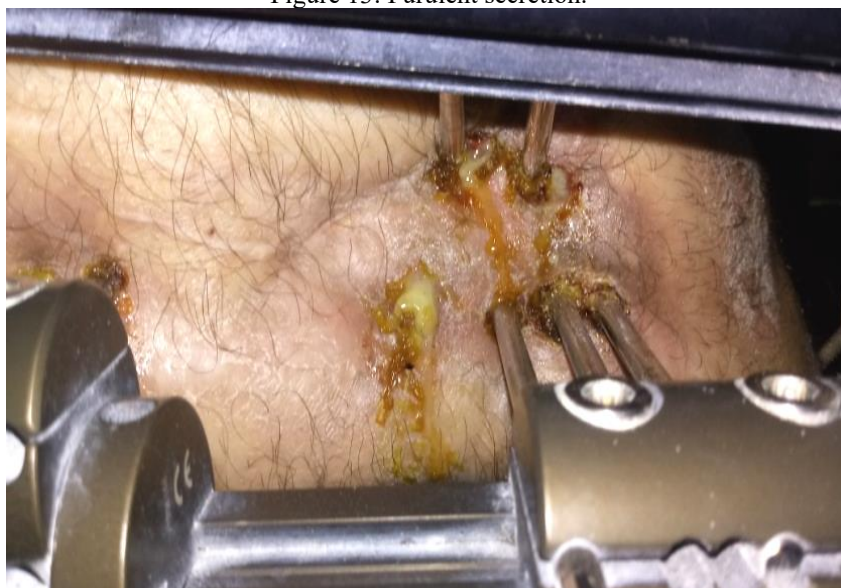Patient in April 2019 was performed a polysomnography with the use of CPAP due to sleep lapses resulting in a sleep apnea and hypopnea a breathing disorder related to upper airway obstruction and cessation of breathing for more than 10 seconds. As mentioned earlier in the project presented here several were the patient health complications involved by negligent medical conduct initially (Figure 12).

Figure 12: Polysomnography.



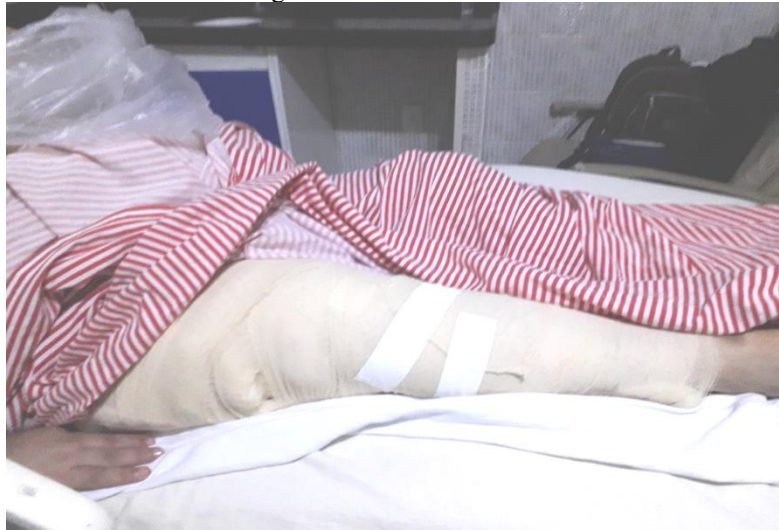In September 2019 the patient with purulent secretion being performed surgery for joint manipulation procedures under general anesthesia wires intraosseous pins and screws tenolysis tenodesis surgical femur and tibia. There were several painful surgical and home recovery procedures (Figure 13).

Figure 13: Purulent secretion.



The patient in October 2020 underwent the procedure of external fixator removal due to infected pseudoarthrosis and cleaning of osteomyelitis for a time interval as a rest for the patient to thus perform ACL surgery surgery done through small cuts and with the aid of arthroscopy, in order to facilitate postoperative and recovery because of injury to his ligaments due to screws placed in the initial treatment. (Figure 14).

Figure 14: Fixator removal.



## 21 FRACTURES AND INFECTIONS

Fracture-related osteomyelitis usually occurs in bone exposure scenarios or after surgical treatment (with or without implant placement). In exposed fractures, contamination is certainly present. The determinants associated with the evolution of contamination to infection are the host immune response, the ability of mechanical cleaning to decrease the bacterial concentration at the site, and debridement to leave healthy, viable tissue in the wound that is less susceptible to bacterial adherence.

## 22 DISCUSSION

The method of stretching over the rod was developed by Paley ET al.<sup>9</sup> in order to accelerate healing and the start of rehabilitation. Our study was not comparative. However, the external fixation technique on the rod showed satisfactory results regarding healing time, external fixator wear time, and knee joint mobility. The bone lengthening method introduced by Ilizarov is currently the method of choice in the treatment of limb discrepancy, regardless of its etiology. The major disadvantage described is the prolonged time of use of external fixation, especially in the consolidation time of the bone regenerate. This imposes complications of psychological character



to both the patient and his family. The use of the locked intramedullary nail associated with the external fixator allows the external fixator to be removed after the lengthening phase.

The healing period, which is at least twice as long as the lengthening period, can be completed with the use of the locked intramedullary nail alone. The benefit of this technique allows early joint mobility and protection of the regenerated bone. GarcíaCimbrello et al<sup>7</sup> in 1992 reported that in 100 patients treated with the traditional technique using the circular external fixator, in which 47 patients were submitted to lengthening, complications occurred, such as device intolerance in 6%, muscle contracture in 22% and two patients with fractures in the bone regeneration. They concluded that prolonged use of the external fixator contributed to the complications.

In our study, because we removed the fixator after lengthening, these complications did not occur. Several authors have described the advantage of bone lengthening through the association of fixators with locked intramedullary nails. In 2011, Sun ET al.<sup>14</sup> reported a retrospective comparative study on tibial bone lengthening in which they compared 176 patients (289 tibias) lengthened with (143) and without (146) associated intramedullary rod. They concluded that the group of rods with external fixators showed better results regarding bone healing time.

In 2012, Jain and Harwood,<sup>15</sup> in a systematic review that compared the traditional Ilizarov technique and the fixator technique associated with intramedullary rods in tibial lengthening, evaluated whether the healing time and the time of use of external fixators decreased. They concluded that there was no change in healing time, and the time of fixator use in the combined technique was shorter. The complications of the methods were similar. These results are in agreement with those obtained in our study. Mahboudian ET al. <sup>16</sup> in 2011, compared fixator on rod with telescopic rods in femoral bone lengthening. They reported that patients who used the rod fixator had fewer complications and better control of the lengthening velocity.

El-Husseini ET al. <sup>17</sup> in a prospective randomized clinical study compared lower limb bone lengthening (femur and tibia) using Ilizarov's method and the fixator technique associated with rods. They concluded that healing time was shorter in the fixator on rods group. In addition, they observed more complications in the group in which only the external fixator was used. In our study we did not make comparisons, and we cannot conclude that the healing time was shorter.

The rod lengthening technique is not without complications. In other descriptions related to femoral lengthening, when 20% of the total limb length was reached, they evolved with posterior knee subluxation or patellar subluxation. Although lengthening over stem reduces the period of



external fixation, caution is required to prevent the major complications cited. In our study we had some complications (28.7%), related to the osteotomy technique.

In four patients it was necessary to redo the osteotomies. We recommend that 17 intraoperative maneuvers with translation of the fragments, confirmed by radioscopy, facilitate the confirmation that the osteotomy was complete. In all patients we performed operative manipulation of the knee and in two cases we used arthroscopy. These maneuvers improve the range of motion of the knee. Conclusion The technique of femoral lengthening with monolateral external fixator over intramedullary nail is an effective method, provides a shorter time of use of the external fixator, better protection of the regenerated bone and early joint rehabilitation, but is not free of complications.

## 23 CONCLUSION

The subject of osteomyelitis has presented new updates in the medical literature and accumulation of knowledge, mainly regarding the better understanding of pathogenic phenomena and development of chronic postoperative infections, as well as new techniques and surgical treatment options. The definition, historical and most recently used classifications are well established and have been presented in this paper, as well as the pathogenic theories. Acute, subacute and chronic osteomyelitis are a prevalent pathology in pediatric and adult ages. On the other hand, chronic osteomyelitis is an extremely frequent complication in traumatic situations and, although in smaller numbers, post-surgically.

Therefore, it is quite pertinent to carry out research about its etiopathogenesis and the most enlightening diagnostic methods, to try to improve treatment. None of the current treatments are consensual, so it is imperative to evaluate the benefits and disadvantages of each methodology, and more than one therapeutic process may be combined in the same situation in an attempt to obtain a more complete result.

Thus, the various therapeutic options should be known by the clinicians who deal with the pathology, so that, given the various factors of the disease (such as classification, the microorganism involved, the role of autoimmunity, among others) and of the host (age, comorbidities), they can make an informed and appropriate choice. In recent years, therapeutic options have evolved rapidly, both in the medical field, with new antibiotics and immunomodulators, and in the surgical field, where amputations are no longer the only possible option, in order to try to preserve as much as possible the normal function of the affected anatomical area. Therefore, conservative surgeries of extended debridement and sequestrectomy,



followed by bone, muscle and skin reconstruction techniques have increasingly become the procedure used in cases of osteomyelitis.

In order to find more promising methods for the resolution of osteomyelitis, it would also be relevant to conduct research on therapeutic techniques through a greater number of randomized studies with clinical trials. Advanced treatments and techniques exist today, but unfortunately they are not financially accessible to most patients for the treatment of osteomyelitis and bone reconstruction in the case of necrotic bone.

The knowledge gathered allows establishing promising combined (clinical and surgical) treatment strategies that show satisfactory results in various scenarios and situations. As a consequence, the mastery of this topic by orthopedists and infectologists allows for better management of patients affected by chronic osteomyelitis of long bones. This work has brought together real information and innovations related to the disease chronic osteomyelitis and its treatment, and offers updating material to assist professionals involved in the treatment of chronic osteomyelitis in making therapeutic decisions.



## ACKNOWLEDGMENTS

In first place I want to thank God, for entrusting and enabling me with a mission so great and challenging to have the will and determination to become a professional in Stomal Therapy and Psychology and Mental Health areas of extreme importance in this journey of physical and mental illnesses and all those involved in the collaboration throughout the treatment and journey, which persists until today, 2023. To the patient mentioned here F.A.A., my husband in the exhibition and acceptance and encouragement of his images for the collaboration of the whole project. My son F.F.F.A., who at the time of the event was 11 years old and was crucial in the development and maturing of his emotional state and being my biggest help throughout the treatment and in the resolution of bureaucracies. Finally, I thank God for my dog Mel, whom you introduced to us when she was abandoned and I adopted her, and she has become a true therapy better than any medicine. I leave my deepest gratitude to Dr. Juvêncio O. Araújo Castro Orthopedics/Traumatology and external fixator specialist in his collaboration, in undoing everything that was done surgically and without success from the beginning and the encouragement always positive and above all Human in dealing with their patients. As well as the Doctor Dr. Luis A. Aires Leal who accompanies him clinically doctor of the Institute of Pension of the Municipality IPM and all the professionals involved in the team in home visits.



## REFERENCES

- Osteomielite crônica pós-operatória nos ossos longos – O que sabemos e como conduzir esse problema Lourenço Galizia Heitzmann<sup>1</sup> Raphael Battisti<sup>1</sup> Ayres Fernando Rodrigues<sup>1</sup> Juliano Valente Lestingi<sup>1</sup> Cinthya Cavazzana<sup>1</sup> Roberto Dantas Queiroz.
- Canale, S, Terry, Beaty JH. Ortopedia cirúrgica de Campbell. Décima segunda ed. Elsevier, Editor.
- Sanders J, Mauffrey C. Osteomielite de ossos longos em adultos: conceitos fundamentais Disponíveis em: <http://www.ncbi.nlm.nih.gov/pubmed/23672894>.
- Hake ME, Oh JK, Kim JW, Ziran B, Smith W, Hak D, ET al. Dificuldades e desafios. Diagnosticar e tratar a osteomielite pós-traumática de ossos longos. Eur J Orthop Surg Traumatol [Internet]. 2014; 25: 1-3. Disponível em: <http://link.springer.com/10.1007/s00590-014-1576-z>.
- Peltola M. Osteomielite Aguda em Crianças. N Engl J Med.
- Rua M, Puna R, Huang M, Crawford H. Pediatric Acute Hematogenous. Osteomielite. 2014; 00 (00): 1–6.
- Montanaro L, Testoni F, Poggi A, Visai L, Speziale P, Arciola CR. Emergindo. Mecanismos patogênicos da osteomielite implantada por Staphylococcus aureus. Int J Artif Organs. 2011; 34 (4): 781–8.
- Howard-Jones AR, Isaac D. Sistemática revisão da duração e escolha da antibioticoterapia sistêmica para osteomielite bacteriana hematogênica aguda em crianças. J Paediatr Child Health. 2013; 49: 760–8.
- Shetty RP, Mathew M, Smith J, Morse LP, Mehta J. A., Currie BJ. Manejo da osteomielite melioidose e artrite séptica. Articulação óssea J [Internet]. 2015; 97- B (2): 277– 82. Disponível em: <http://www.bjj.boneandjoint.org.uk/cgi/doi/10.1302/0301-620X.97b2.34799>.
- Tamma PD, Milstone AM. Terapia antibiótica ambulatorial para osteomielite aguda em crianças Equilibrando segurança e eficácia Educação médica consciente de alto valor e custo. 2015
- Ceroni D, Belaieff W, Cherkaoui A, Lascombes P, Dayer R, Schrenzel J, ET al. Epifisária Primária ou Subaguda Apofisária. 2014; 1570–5. 27
- Dartnell J, Ramachandran M, Katchburian M. Haematogenous aguda e subaguda osteomielite pediátrica: Uma revisão sistemática da literatura. J Bone JT Surg - BR Vol. 2012; 94-B: 584–95.
- Abdulahdi Ma, White AM, Pollock AN. NO Abscesso de Brodie. 2012; 28 (11): 1249– 51,36.
- De Souza MDSQA, de Souza CA, Cunha LMP, de Souza AQA, de Moraes MS, Rabenhorst SHB. Um novo olhar sobre o desenvolvimento da osteomielite - Foco no CCR5DELTA32. Estudo em pacientes do Nordeste do Brasil. Infect Genet Evol [Internet]. Elsevier B.V.; 2015; 31 (janeiro): 61–3. Disponível em: <http://linkinghub.elsevier.com/retrieve/pii/S1567134815000167>.
- Gamaletsou MN, Rammaert B, Bueno M., Moriyama B, Sipsas N. V., Kontoyiannis DP, ET al. Osteomielite por Aspergillus: Epidemiologia, manifestações clínicas, manejo e resultado. J



Infectar [Internet]. Elsevier Ltd; 2014; 68 (5): 478–93. Disponível em: <http://dx.doi.org/10.1016/j.jinf.2013.12.008>.

Slenker AK, Keith SW, Horn DL. Duzentos e onze casos de osteomielite por Candida: 17 relatos de casos e uma revisão da literatura. *Diagn Microbiol Infect Dis* [Internet]. ELSEVIERINC. 2012; 73 (1): 89–93. Disponível em: <http://dx.doi.org/10.1016/j.diagmicrobio.2012.02.004>.

Baykam N, Clínica CM, Treinamento AN, Doenças I. Osteomielite vertebral: características clínico e diagnóstico. 2014; 1–6.

Bariteau JT, Waryasz GR, McDonnell M, Fischer S a, Hayda CR a, Born CT. Osteomielite fúngica e artrite séptica. *J AM Acad Orthop Surg* [Internet]. 2014; 22: 390–401. Disponível em: <http://www.ncbi.nlm.nih.gov/pubmed/24860135>.

Treglia G, Sadeghi R, Annunziata S, Zakavi SR, Caldarella C, Muoio B, ET al. Desempenho diagnóstico da tomografia por emissão de pósitrons FluorineFluorodeoxyglucose para o diagnóstico de osteomielite relacionada ao pé diabético: uma revisão sistemática e uma meta-análise. *Pé* [Internet]. Elsevier Ltd; 2013; 23 (4): 140–8. Disponível em: <http://dx.doi.org/10.1016/j.foot.2013.07.002>.

Lesens O, Desbiez F, Theis C, Ferry T, Bensalem M, Laurichesse H, et al. Osteomielite diabética por *Staphylococcus aureus*: tratamento médico ou cirúrgico? Uma coorte retrospectiva francesa e espanhola. *Int J Feridas dos extremos baixos* [Internet]. 2014; Disponível a partir de: <http://ijl.sagepub.com/cgi/doi/10.1177/1534734614559931>.

Lo C. Antibióticos para o tratamento da osteomielite crônica em adultos (revisão). 2013; (9). Aragon-Sanchez J, Lazaro-Martinez JL, Alvaro-Afonso FJ, Molines-Barroso R. Cirurgia conservadora de osteomielite diabética do antepé: Como posso operar este paciente sem 28 amputações? *Int J Feridas dos extremos baixos* [Internet]. 2014; Disponível em: <http://ijl.sagepub.com/cgi/doi/10.1177/1534734614550686>.

Tan Y, Wang X, Li H, Zheng Q, Li J, Feng G, et al. A eficácia clínica da terapia de fechamento assistido a vácuo no tratamento da osteomielite em adultos. *Arch Orthop Trauma Surg*. 2011; 131: 255–9. Karger C, Kishi T, Schneider L, Fitoussi F, Masquelet a. C. Tratamento de defeitos ósseos pós-traumáticos pela técnica de membrana induzida. *Orthop Traumatol Surg Res* 37 [Internet]. Elsevier Masson SAS; 2012; 98 (1): 97–102. Disponível em: <http://dx.doi.org/10.1016/j.otsr.2011.11.001>.

N. M; DR. WL. EJ. K. O Método de Ilizarov em Nonunion, Malunion e Infecção de Fractures.pdf.

Ferguson PJ, Sandu M. Compreensão atual da patogênese e gestão de Osteomielite multifocal recorrente crônica. *Curr Rheumatol Rep*. 2012; 14: 130–41.

Kelly DM. Anomalias congênitas da extremidade inferior. In: Canale ST, Beaty JH, editores. *Ortopedia cirúrgica de Campbell*. 11ª ed. St Louis: Mosby; 2007. P. 1048–9.

Fleming B, Paley D, Kristiansen T, Pope M. Uma análise biomecânica do fixador externo de Ilizarov. *Clin Orthop Relat Res*. 1989; 241: 95–105.



Kummer FJ. Biomecânica do fixador externo de Ilizarov. *Clin Orthop Relat Res.* 1992; 280: 11–4.

Ilizarov GA. *Osteosíntesis: técnica de Ilizarov.* Madrid: Ediciones Norma; 1990.

Ilizarov GA. O efeito do estresse-tensão na gênese e crescimento dos tecidos. Parte I. A influência da estabilidade da fixação e preservação dos tecidos moles. *Clin Orthop Relat Res.* 1989; 238: 249–81.

Ilizarov GA. O efeito do estresse-tensão na gênese e crescimento dos tecidos: Parte II. A influência da taxa e frequência de distração. *Clin Orthop Relat Res.* 1989; 239: 263–85.

García-Cimbrelo E, Olsen B, Ruiz-Yagüe M, Fernandez-Baíllo N, técnica de MunueraMartínez L. Ilizarov. Resultados e dificuldades. *Clin Orthop Relat Res.* 1992; 283: 116–23.

Song HR, Oh CW, Mattoo R, Park BC, Kim SJ, Park IH, ET al. Alongamento femoral sobre haste intramedular com fixador externo: risco de infecção e problemas no joelho em 22 pacientes com seguimento de dois anos ou mais. *Acta Orthop.* 2005; 76 (2): 245–52.

Paley D, Herzenberg JE, Paremain G, Bhave A. Alongamento femoral sobre uma haste intramedular. Uma comparação de casos semelhantes com o alongamento femoral de Ilizarov. *J Bone Joint Surg AM.* 1997; 79 (10): 1464–80.

Simpson AH, Cole AS, Kenwright J. Perna alongando-se sobre uma unha intramedular. *J Bone Joint Surg Br.* 1999; 81 (6): 1041–5. 11. Bost FC, Larsen LJ. Experiências com 29 alongamentos do fêmur sobre haste intramedular. *J Bone Joint Surg AM.* 1956; 38-A (3): 567– 84.

Min WK, Min BG, Oh CW, Song HR, Oh JK, Ahn HS, ET al. Vantagem biomecânica do alongamento do fêmur com fixador externo sobre haste intramedular. *J Pediatr Orthop B.* 2007; 16 (1): 39–43.

Raschke MJ, Mann JW, Oedekoven G, Claudi BF. Transporte segmentar após pregagem intramedular não sonada. Relatório preliminar de um sistema de monotrilha. *Clin Orthop Relat Res.* 1992; 282: 233–40.

Sun XT, Easwar TR, Manesh S, Ryu JH, Song SH, Kim SJ, ET al. Complicações e resultado do alongamento tibial pelo método de Ilizarov com ou sem haste intramedular suplementar: um estudo comparativo pareado. *J Bone Joint Surg Br.* 2011; 93 (6): 782–7.

Jain S, Harwood P. O uso de haste intramedular altera a duração da fixação externa e a taxa de consolidação em procedimentos de alongamento tibial? Uma revisão sistemática. *Estratégias Trauma Limb Reconstr.* 2012; sete (3): 113–21.

Mahboubian S, Seah M, Fragomen AT, Rozbruch SENHOR O alongamento femoral com alongamento sobre uma haste tem menos complicações do que a distração cinética esquelética intramedular. *Clin Orthop Relat Res.* 2012; 470 (4): 1221–31.

El-Husseini TF, Ghaly NA, Mahran MA, Al Kersh MA, Emar KM. Comparação entre alongamento sobre a haste e alongamento de Ilizarov convencional: um estudo clínico prospectivo randomizado. *Estratégias Trauma Limb Reconstr.* 2013; Oito (2): 97–101.



Kocaoglu M, Eralp L, Kilicoglu O, Burc H, Cakmak M. Complicações encontradas durante o alongamento sobre uma haste intramedular. J Bone Joint Surg AM. 2004; 86 (11): 2406–11.