



Current techniques in bariatric surgery and their benefits: A literature review

Atuais técnicas em cirurgia bariátrica e seus benefícios: Uma revisão da literatura

DOI: 10.56238/isevjhv2n4-015

Receiving the originals: 13/07/2023

Acceptance for publication: 04/08/2023

Ana Laura dos Santos Taveira

Medical student.

Universidade de Franca - UNIFRAN.

Guilherme Giacomeli Eiras

Medical student.

Universidade de Franca - UNIFRAN.

Heitor Augusto Ferrari Granero

Medical student.

Universidade de Franca - UNIFRAN.

Lucas Faria Rodrigues

Medical student.

Universidade de Franca - UNIFRAN.

Maria Antonia Camillo Rodrigues

Medical student.

Universidade de Franca - UNIFRAN.

Caio Felipe Pugliesi de Souza

Medical student.

Universidade de Franca - UNIFRAN.

Maria Eduarda Freitas Bertoluci

Medical student.

Universidade de Franca - UNIFRAN.

Gabriel Turquetto Fernandes Andrade

Medical student.

Universidade de Franca - UNIFRAN.

Andréa de Oliveira Cecchi

Post Doctorate.

Georgetown University Medical Center.

ABSTRACT

Introduction: Bariatric, restrictive and mixed (predominantly restrictive or malabsorptive) surgery is a therapy to reduce weight and control associated diseases. This literature review discusses the



relevance of procedures approved by the Federal Council of Medicine (CFM) according to bibliographic references of significant scientific evidence. Objectives: To review the techniques currently used in bariatric surgery, their advantages and disadvantages. Methods: Literature review of the techniques used in bariatric surgery, by descriptors in Portuguese (techniques in bariatric surgery, gastric banding, vertical gastrectomy, Roux-en-Y gastric bypasses and biliopancreatic bypass). Results: Gastric banding is a silicone prosthesis wrapped around the stomach, which generates weight gain. Vertical gastropasty reduces the stomach by means of a suture mediated by a ring, with good results but high recurrence. The intragastric balloon is the insertion of a silicone prosthesis with methylene blue, which must be removed after 6 months. Gastric by-pass has low mortality and high efficacy, and is the most widely used in Brazil. Vertical gastrectomy, on the other hand, preserves the small intestine and partially the stomach, and its low post-operative mortality rate determines its frequent indication. The Scopinaro technique accounts for 5% of procedures carried out in Brazil, while the duodenal switch or vertical gastrectomy with intestinal detour generates nutritional deficiency. Conclusion: When comparing surgical methods, it is up to the surgeon and the team to decide which is best for the patient. However, regardless of the technique used, scientifically it is the approach with the most positive long-term results compared to clinical approaches.

Keywords: Bariatric surgery, Obesity, Weight loss, Techniques in bariatric surgery.

1 INTRODUCTION

Bariatric surgery is the term used to refer to surgical therapy for obesity. This therapy encompasses various techniques that have the same objective: to reduce the weight of obese patients and control associated diseases.(1) However, not all cases of obesity are indicated for surgery, but only the most severe and refractory to conventional treatment(2), such as patients with a Body Mass Index (BMI) of 35kg/m^2 and who have comorbidities.(3) In addition, patients must have at least 5 years of outpatient follow-up in which all therapeutic attempts have failed. In addition, none of the specific surgical contraindications for bariatric surgery, such as renal failure and cirrhosis of the liver, must be present.(4) Bariatric surgery often has significant success, as documented in the literature, because it is able to reduce the patient's weight while providing them with a better quality of life and reducing the intrinsic comorbidities of obesity.(1) With this, it is clear that bariatric surgery is a therapy of last resort, for extreme cases, but it does have significant therapeutic success.(4)

Before going into the surgical techniques themselves, it is important to understand some concepts about obesity. Obesity is one of the biggest public health problems today, since the comorbidities associated with it are among the leading causes of death in the world. It is also known that, since the last century, the prevalence of obesity in the world population, especially in developed Western countries, has increased significantly and continues to grow.(5) Several studies associate this fact with the drastic changes in human lifestyle in recent decades, with an increase



in sedentary lifestyles and consumption of ultra-processed foods with a high carbohydrate and fat content. In addition, data from the World Health Organization (WHO) indicate an increase in public spending not only on treatment, but also on prevention of obesity, pointing to considerable political interest in the matter.(6) All these factors generate a need for effective ways to manage this disease.

Obesity is defined by excess fat mass, and BMI is the most widely used method for assessing and classifying it. BMI classifies obesity into: overweight, grade 1, grade 2 and grade 3 (morbid obesity).(6) As the grade increases, as well as the time spent in this condition, the symptoms and diseases associated directly and indirectly with obesity tend to become more significant. Among the main symptoms/diseases we can mention: metabolic syndrome, type 2 diabetes, dyslipidemia, stroke, hypertension, heart failure, dyspnea, obstructive sleep apnea, gastroesophageal reflux disease, cholelithiasis, abdominal hernias, urinary incontinence, immobility, low back pain, osteoarthritis in the knees and hips and depression.(7)

The pathophysiological mechanisms that explain the genesis of obesity manifestations are complex and often independent. However, it is worth noting that obesity is a multifactorial disease, i.e. both environmental and genetic factors are associated with its etiology.(6) Furthermore, alterations in insulin resistance, the endothelium, the sympathetic nervous system and renal and adrenal function are very important factors in the pathogenesis of the disease and explain a large part of the alterations observed in the typical clinical picture of the disease.(6)

Knowing this, it is important to emphasize that most cases of obesity can be treated on an outpatient basis with lifestyle changes, which include adherence to a regular exercise protocol and specific diet plans for weight loss.(8) Medications can also be used concomitantly with lifestyle changes, however, even with this multifactorial approach, therapeutic failure is very high in severe patients. Around 95% of them, despite achieving significant weight loss, end up returning to their initial weight.(9) Furthermore, mortality in this group of patients is extremely high when compared to non-obese patients in the same age group.(10)

In contrast, treatment failure after bariatric surgery for patients in the same severity classification is significantly lower. Some studies claim that only 50% of patients return to obesity after the drastic weight loss that follows surgery. However, in these cases, failure was associated with a lack of nutritional and psychological follow-up, as well as non-adherence to regular follow-up appointments. Thus, the existence of bariatric surgery is justified not only by the high mortality and morbidity of severe cases of obesity and the failure of conventional treatment, but also by its

potential for therapeutic success when all the follow-up and guidance is followed during the years after surgery.(10)

With regard to the various bariatric techniques, it is worth mentioning a brief historical context. The first surgical interventions began to be studied in the 1950s when disabsorptive procedures were created.(3) In 1986, Fobi created the gastrointestinal *by-pass*, a procedure that avoided a stomach incision by introducing a silicone ring with the function of reducing the gastric cavity. In 1990, Capella proposed a similar surgical procedure, with gastroplasty by stapling the stomach, associated with intestinal bypass. Currently, the technique known as Capella, or Roux-en-Y gastroplasty with intestinal bypass, is considered the "gold standard".(1)

Given this context, bariatric surgery has been used since the 1950s as a solution to morbid obesity. As shown in Table 1, the procedures are divided into three types of techniques: restrictive and mixed (predominantly restrictive or malabsorptive). Disabsorptive procedures are performed by diverting a large part of the small intestine, which is responsible for absorbing nutrients, while restrictive procedures are performed by reducing the stomach cavity, interfering with hormonal dynamics and bringing satiety to the patient. Mixed types, on the other hand, involve surgical interference with both the small intestine and the stomach.(1)

The main techniques used in bariatric surgery include: the intragastric balloon, recognized as an endoscopic therapeutic method, which is an aid in the preoperative period(1); vertical gastrectomy, known as Sleeve surgery, widely used to control dyslipidemia and hypertension, in which the stomach remains at only 80 to 100ml of capacity; and finally, the *duodenal Switch*, which is a mixed surgery that uses vertical gastrectomy and intestinal detour, maintaining the physiology of gastric emptying.(11)

The surgeries considered restrictive are adjustable gastric banding, vertical gastroplasty with banding, vertical (or sleeve) gastrectomy and the intragastric balloon. The first technique consists of the laparoscopic insertion of a silicone device that gives the stomach an hourglass shape, while the second consists of suturing a certain area of the stomach, which forms a small reservoir that is restricted from emptying; Sleeve gastrectomy is characterized by the removal of a large part of the stomach, which is transformed into a tube; and finally, the intragastric balloon uses a silicone prosthesis which is introduced into the stomach endoscopically and filled with methylene blue and saline solution.(1) (11)

Among the mixed surgeries with a predominance of restrictive techniques, there is the Roux-en-Y (or Capella) gastric bypass, which is an invasive technique performed by stapling part of the gastric cavity and anastomosing the jejunal region to the gastric portion, thus reducing the



space for food and increasing the hormones that cause satiety due to this intestinal detour. (1) (11) They also include techniques that are predominantly malabsorptive, such as biliopancreatic diversion and its variations, such as the technique with horizontal gastrectomy and the technique with vertical gastrectomy and preservation of the pylorus. Among the mixed techniques, the *duodenal switch* technique is commonly performed and consists of a combination of vertical gastrectomy and intestinal detour, which removes part of the antrum and leaves the stomach in a "half-moon" shape, maintaining the anatomy and physiology of emptying the organ.(1) (11)

In this context, it is important to clarify that all techniques can bring benefits or harms to the patient. Therefore, this literature review will discuss the most relevant points of each procedure according to bibliographic references that used significant scientific evidence for the research.

2 METHODOLOGY

For this review of bariatric surgery techniques recommended by the Federal Council of Medicine (CFM) (12), we selected studies from 2011 to 2020, using relevant databases such as Scielo and Bireme, as well as the resolution established by the CFM, in addition to consulting the website of the Brazilian Society of Bariatric and Metabolic Surgery.(11)

To search the databases mentioned above, descriptors in Portuguese were used (bariatric surgery, bariatric surgery techniques, gastric banding, vertical gastrectomy, intragastric balloon, Roux-en-Y gastric bypass, biliopancreatic bypass).

After identifying all the studies found, articles from the last four years (2017-2020) were selected. Of these, the studies were analyzed for relevance and validity, selected according to the thematic cut for this literature review. The studies used include review articles, descriptive analytical, cross-sectional, retrospective and some are experimental, these with the due approval of the Ethics Committee of the institution itself and with the distribution of the Free Consent Form.

3 RESULTS AND DISCUSSION

3.1 RESTRICTIVE

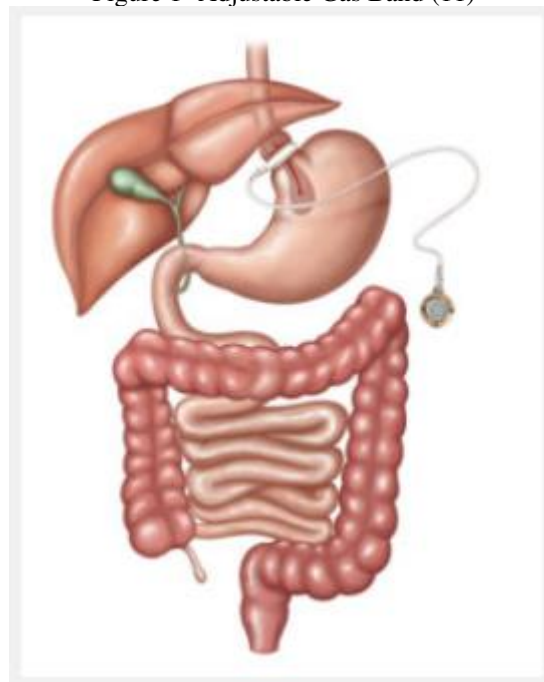
3.1.1 Gastric Bandage

Among restrictive surgeries, laparoscopic adjustable gastric banding is one of the alternatives for treating morbid obesity. The technique is based on the placement of a silicone prosthesis by video wrapping around the stomach, the only organ that will be altered, acquiring an hourglass shape, as shown in figure 1.(1)

It is called adjustable because the band's reservoir is calibrated in the postoperative period according to the patient's needs, by means of a percutaneous injection of liquid.(1) Restrictive techniques are suitable for patients with a BMI of less than 50 kg/m², and the band allows only the upper portion of the stomach to remain free, with a capacity of 30mL. It is considered a safe and effective technique for reducing initial weight, but there is a high chance of weight regain in cases of compulsive consumption of hypercaloric liquids and sweets, due to the patient's accommodation to the restriction.(13)

The bandage was brought to Brazil in 1996, but today its use is limited. One of its contraindications is the fact that the prosthesis develops rejection and complications for the patient after it is placed, as it is a foreign body inside the gastrointestinal tract.(11) Compared to other techniques (as it doesn't permanently alter the digestive system, it doesn't involve incisions and stapling of the stomach) it has long-term benefits for patients, as after its removal the anatomy of the organs involved remains preserved.(1)

Figure 1- Adjustable Gas Band (11)



4 VERTICAL GASTROPLASTY WITH BANDAGE

Vertical gastroplasty with bandaging or Mason's surgery was introduced in 1982, based on the fact that the small muscles of the stomach are more resistant to dilation, and so the possibility arose of reducing this area and then using rings to prevent possible enlargement.(2)

This is a restrictive type of surgery, which aims to reduce the gastric space to just 20 mL through a suture in the cardia and the outlet being mediated by a polypropylene ring. In this way, the patient is restricted to eating and the gastric contents are delayed, so that they are satiated with smaller quantities of food.(1) (2)

The results of this type of surgery after the first few years is a loss of 30% of body weight, but after 10 years of surgery the results become negative with a drop in body weight loss to 20%, as well as a high incidence of obesity recurrence after this time. The reason for this drop in body weight loss is the inappropriate diet that these patients acquire over time, starting to use hypercaloric liquid foods such as *milk shakes and condensed milk*, which pass through the stomach quickly.(1)

4.1 INTRAGASTRIC BALLOON

The intragastric balloon (IAB) model was first described by Nieben and Harboe, with the aim of helping to treat obesity by promoting a feeling of satiety and gastric fullness. However, the first model used was soon discarded as it showed numerous complications such as severe bleeding and intestinal obstruction.(14) (15)

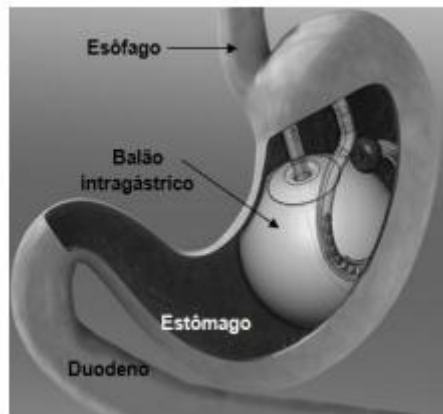
The current BIG was introduced at the end of the 1980s, when there was an improvement in the material used. The device used today consists of a silicone prosthesis that remains closed, which is filled with methylene blue and saline in a quantity of 450 to 700mL. The BIG is inserted endoscopically into the gastric fundus with the patient sedated, as shown in figure 2.(14) (15)

There are advantages to using BIG, such as the estimated weight reduction over a short period of six months of between 13 and 20 kg, and a decrease in BMI of up to 5-9 kg/m². Because of this, this treatment is recommended for patients who need to lose weight before surgery in order to reduce the anesthetic-surgical risk; patients who have not responded to less invasive alternatives such as clinical management through diet, exercise, drugs, behavioral change.(15) In addition, BIG has a high success rate with a low rate of side effects, and has been proven to help reduce comorbidities associated with high weight, improve the metabolic profile as well as transiently alter appetite-regulating hormones.(14) (15)

It's important to note that BIG isn't as effective as other surgical methods in the long term, since the balloon has to be removed after 6 months and weight gain relapses are common. In addition, even though there are few side effects, they can vary from mild to severe. Mild symptoms include vomiting, which tends to be transient, but when persistent, can lead to serious consequences such as dehydration and electrolyte imbalance. The most serious symptoms can

culminate in intestinal occlusions and perforations. BIG is also contraindicated in specific situations, such as in patients who have already undergone gastric resection or bariatric surgery; patients with decompensated psychiatric illnesses; patients who are pregnant or lactating; patients with uncompensated inflammatory bowel disease; and patients with esophago-gastro-duodenal diseases.(15)

Figure 2- Intra-gastric balloon (1)



5 PREDOMINANTLY RESTRICTIVE

5.1 GASTRIC *BY-PASS* (ROUX-EN-Y GASTRIC BYPASSES WITH OR WITHOUT A CONTAINMENT RING)

Roux-en-Y gastrojejunal bypass gastroplasty, popularly known as gastric bypass, created by Fobi and Capella, which falls within the mixed surgical procedures, is the most commonly performed technique in Brazil due to its low morbidity and mortality and high efficacy, especially in rapid weight loss.(1) Volume reduction, excluding the gastric fundus, occurs by excising the proximal stomach, leaving it with a capacity of approximately 20mL, which is then anastomosed to an isolated Y-shaped jejunal loop, which will divide the small intestine into a food loop and a biliopancreatic loop, as shown in Figure 3.(16)

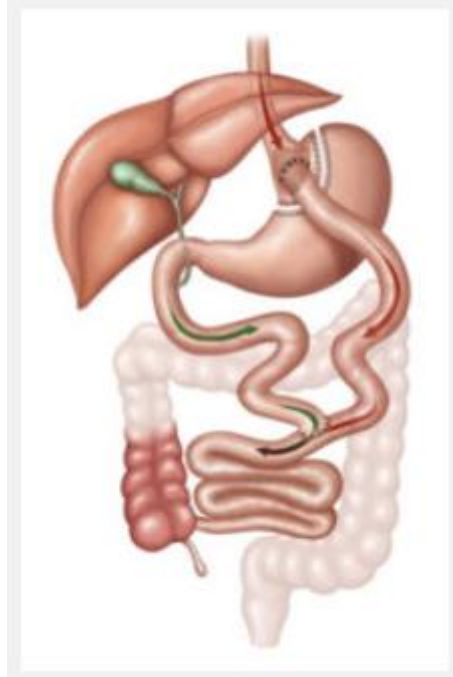However, the sum of stomach reduction and intestinal bypass favors the process of reducing hunger due to changes in hormones and causing satiety, such as the decrease in ghrelin, signaling of the glucagon-like peptide 1-(7-36)-amide (GLP-1) responsible for reducing gastric emptying and the decrease in intestinal peristalsis by PYY (1), leading to weight loss and control of comorbidities such as diabetes and hypertension.(11)

According to the SOS (*Swedish Obese Subjects*) study, advantages were found for the patient after bariatric surgery, such as improved quality of life, improved dyspnea, sleep apnea, lipid disorders, associated with a significant weight loss.(16)

In a study carried out with 56 patients in the 12-month post-operative period of gastroplasty in the city of Londrina, it was possible to verify their metabolic-nutritional profile, which showed a change in dietary pattern. Meat intolerance is noteworthy due to the deficit of hydrochloric acid and proteolytic enzymes essential in the stomach digestion process. It is therefore worth pointing out that reducing food intake is no substitute for eating healthier foods, making clinical nutritional monitoring essential in order to avoid metabolic changes and weight gain.(17)

In the mixed Roux-en-Y procedure, the ingestion of simple carbohydrates favors the so-called dumping syndrome, which is the rapid passage of these foods from the stomach to the intestine containing a large amount of sugar that ends up causing nausea, vomiting, gastric pain and symptoms similar to hypoglycemia.(1)

Figure 3 Gastric Bypass (gastroplasty with Roux-en-Y intestinal bypass) (11)



6 VERTICAL GASTRECTOMY

Vertical gastrectomy (VG) or the Sleeve method is a surgical technique that has been used since the year 2000 and is effective in controlling dyslipidemia and systemic arterial hypertension.(17) It is a mixed procedure, i.e. restrictive and partially disabsorptive, whose advantages are the preservation of the small intestine and part of the stomach, consequently, more stable absorption of medication and less risk of malabsorption, reducing the risk of vitamin deficiency.(18) The Sleeve method is a surgical technique that has been used since the year 2000.



GV was first performed by Hess in 1988, who used it as part of duodenal pancreatic replacement; Gagner performed it laparoscopically in 1999. This technique has become the most widely used intervention in our country for the management of obesity. Its low post-operative morbidity and its results in all comparable gastric bypasses, in relation to excess weight lost, have determined the high frequency of its indication.(19)

The advantage of not excluding the duodenum from food transit is that the absorption of iron, calcium and other nutrients is preserved. This avoids dumping syndrome, the risk of anastomotic ulcers and the formation of internal hernias. This data is particularly important for patients with anemia, especially women of childbearing age.(20)

The operative technique is not completely standardized in its operative times. The alternatives proposed generally leave the antropyloric area, to a greater or lesser extent, remove most of the gastric body vertically from the imaginary line dividing the antrum and gastric body, and completely eliminate the gastric fundus.(20)

For the surgical technique, shown in figure 4, GV begins with ligation of the great curvature vessels, with the pylorus as the anatomical reference. Devascularization, like gastrectomy, begins at the level of the pylorus. It is performed with ultrasonic energy and extends from the pylorus to the esophagogastric angle. All the coalescences of the posterior wall of the stomach with the adjacent structures are sectioned so that the stapling occurs symmetrically between the posterior and anterior walls, thus avoiding torsion of the gastric tube.(20)

After this procedure, stapling begins from the pylorus towards the gastric antrum which, because it is thicker, needs a black or green filler. When making the gastric tube, only the first two shots are not shaped with the Fouchet probe that will be placed next.(20)

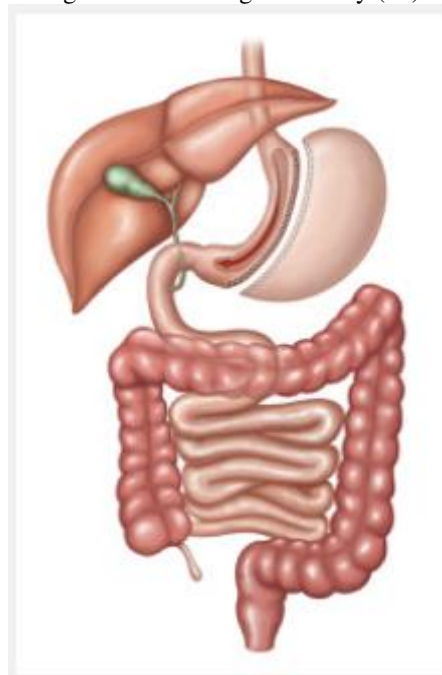At this point in the surgical procedure, a 32 F Fouchet probe is inserted through the mouth into the duodenal lumen, thus bypassing the pylorus. Stapling with a purple or blue load is used from the angular incisure onwards, taking special care not to cause stenosis at this level, which is achieved by making the stapling tight to the modeling probe, observing the anterior and posterior walls of the stomach to make them symmetrical. This is followed by sectioning towards the cardia with a blue load.(20)

Stapling at this angle requires good visualization when placing the stapler in order to avoid stenosis of the distal oesophagus and excessive devascularization, leading to the appearance of a fistula at this level(20).

To complete the procedure, in all cases the staple line is sutured with a 3-0 prolene thread and the peritoneal cavity is drained using a sump-type drain.(20)

Postoperatively, patients are maintained until they are hospitalized with adequate tolerance to oral fluids, no pain, no nausea and normal gait. Receive a proton pump inhibitor for 90 days and prophylaxis of thromboembolic events with enoxaparin for at least 10 days beyond hospitalization. Vitamin-mineral and protein supplementation is recommended for one year. Re-evaluations with the surgeon and the entire multi-professional team are carried out every three months until the two-year mark. After that, an annual consultation is recommended.(21)

Figure 4- Vertical gastrectomy (11)



7 PREDOMINANTLY MALABSORPTIVE

7.1 SCOPINARO TECHNIQUE (BILIOPANCREATIC DIVERSION WITH HORIZONTAL GASTRECTOMY WITH OR WITHOUT DISTAL GASTRIC PRESERVATION)

Biliopancreatic diversion with horizontal gastrectomy with or without distal gastric preservation, also known as the Scopinaro technique, is predominantly malabsorptive. It accounts for 5% of bariatric surgical procedures performed in Brazil.(1)

This is characterized by a reduction in gastric capacity, loss of pyloric control of gastric emptying and malabsorption due to the bypass of too much of the small intestine. In other words, the technique consists of a partial biliopancreatic *bypass* with distal gastrectomy.(1) It is extremely complex and should only be performed by trained professionals, but it has a high degree of resolvability of comorbidities.(1)



As a result, the action of enzymes involved in the nutrient absorption process is reduced. By removing the distal stomach, the risk of gastric ulcers is reduced. The patient must then control their intake of fats, whether of animal or vegetable origin, which lead to foul-smelling stools and flatulence. This is due to the presence of unabsorbed waste in the colon, which generates bacterial proliferation and fermentation. In addition, protein and calcium intake should also be cautious in order to prevent bone pathologies.(1)

In addition to these factors, there may be complications such as protein malnutrition, iron deficiency anemia and deficiencies in calcium, zinc, essential fatty acids and vitamins. Postprandial nausea and diarrhea are observed, and these symptoms are related to early dumping syndrome.(3)

7.2 DUODENAL SWITCH (BILIOPANCREATIC DIVERSION WITH VERTICAL GASTRECTOMY AND PYLORIC PRESERVATION)

In 1990, a mixed technique emerged, predominantly malabsorptive, known as Biliopancreatic Diversion with Vertical Gastrectomy and Preservation, or just Duodenal Switch, named after the intestinal detour that is performed during surgery.(1) (3)

Thus, in a schematically similar way to "Roux-en-Y gastroplasty", it is possible to divide the technique didactically into two main procedures, illustrated in figure 5. Firstly, the vertical gastrectomy, in which a large part of the fundus of the stomach is removed, so that the remainder resembles the shape of a vertical tube, hence its restrictive component. Secondly, intestinal detour, which characterizes the malabsorptive component, where the communication between the duodenum and stomach, as well as a distal portion of the jejunum, are surgically sectioned, so that there are four ends left to be connected.(11) One end is the upper duodenal part which is sutured, leaving three, two of which are connected to each other: the antrum of the stomach and the distal end of the jejunum. This leaves only the proximal end of the jejunum, which carries the biliopancreatic secretion, and which is connected to the ileum, close to the ileocecal valve, where this secretion first comes into contact with the chyme.(1) (3) (11)

With this in mind, this technique has the great advantage of excellent efficacy for weight loss even years after surgery, as well as helping to control comorbidities such as type 2 diabetes.(2) However, it is a highly complex surgery, which subjects the patient to nutritional deficiency and consequent bone demineralization, as well as generating unpleasant situations such as diarrhea and increased frequency of bowel movements. The detour is an intestinal bypass that aims to prolong the time that food remains without contact with the biliopancreatic secretion, which leads to

increased satiety, reduced hunger and at the same time can cause intolerance to high-calorie foods.(1) (3)

Figure 5- Duodenal Switch (11)

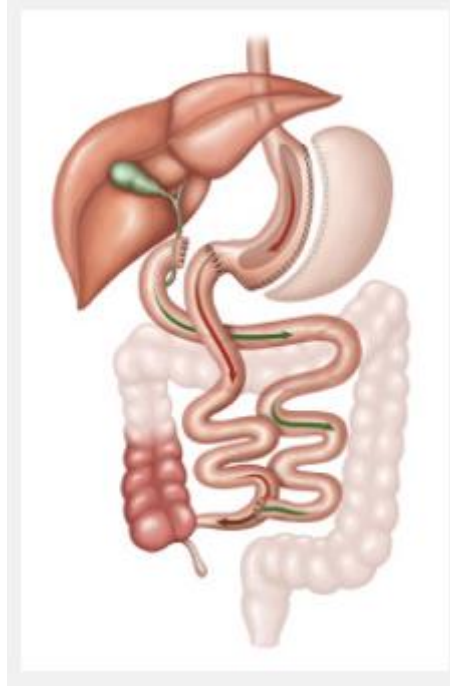


Table 1- Techniques in bariatric surgery (1)

Classification	Techniques
Restrictive	Gastric bandaging Vertical gastropasty with bandage Intragastric balloon
Predominantly restrictive	Roux-en-Y gastric bypasses with or without containment ring Vertical gastrectomy
Predominantly malabsorptive	Biliopancreatic diversion with horizontal gastrectomy with or without distal gastric preservation Biliopancreatic diversion with vertical gastrectomy and pyloric preservation

8 CONCLUSION

From the above, it can be seen that there are treatments that are more or less efficient. This analysis of the literature was based on the techniques approved by the CFM. Furthermore, it is worth noting that, regardless of the surgical technique used, scientific data shows that this approach



is more likely to achieve positive results in the long term when compared to clinical approaches alone.

It is not possible to determine the existence of greater effectiveness in the description and comparison of each surgical method, so it is up to the surgeon and the team to analyze in a particular way which situation best fits the reality of each patient, based on the available evidence.



REFERENCES

- Zeve JLM, Novais PO, Oliveira Júnior N. Técnicas em cirurgia bariátrica: uma revisão da literatura. *Revista Ciência & Saúde*. 2012 jul./dez.: p. 132-140.
- Castro Filho HF, Castro Neto HF. O momento atual da cirurgia bariátrica. *PROACI/SEMCAD*.: p. 97-125.
- Bacchi RR, Bacchi KMS. Cirurgia bariátrica: Aspectos clínicos e nutricionais. *Motricidade*. 2012;8(2):89-94. Recuperado de: <https://www.redalyc.org/articulo.oa?id=273023568098>.
- Fandiño J, Benchimol AK, Coutinho WF, Appolinário JC. Cirurgia bariátrica: aspectos clínico-cirúrgicos e psiquiátricos. *Rev. psiquiatr. Rio Gd. Sul [Internet]*. 2004 Apr [cited 2021 May 16] ; 26(1): 47-51. Available from: <http://dx.doi.org/10.1590/S0101-81082004000100007>.
- Revista Brasileira de Obesidade, Nutrição e Emagrecimento*, São Paulo. Suplementar 2. v.11. n.68. p.653-660. Jan./Dez. 2017. ISSN 1981-9919.
- Seravalle G, Grassi G. Obesity and hypertension. *Pharmacol Res*. 2017 Aug;122:1-7. doi: 10.1016/j.phrs.2017.05.013. Epub 2017 May 19. PMID: 28532816. Available from: Obesity and hypertension - PubMed (nih.gov).
- Long DL. et al. *Medicina Interna de Harrison*. 18 ed. Porto Alegre, RS: AMGH Ed., 2013. 2v.
- Revista Brasileira de Obesidade, Nutrição e Emagrecimento*, São Paulo. v.12. n.74. p.692-698. Nov./Dez. 2018. ISSN 1981-9919.
- Tonatto Filho AJ, et al. BARIATRIC SURGERY IN BRAZILIAN PUBLIC HEALTH SYSTEM: THE GOOD, THE BAD AND THE UGLY, OR A LONG WAY TO GO. YELLOW SIGN! ABCD. *Arquivos Brasileiros de Cirurgia Digestiva (São Paulo) [online]*. 2019, v. 32, n. 04 [Acessado 2 Outubro 2021] , e1470. Disponível em: <<https://doi.org/10.1590/0102-672020190001e1470>>. Epub 20 Dez 2019. ISSN 2317-6326. Available from: <https://doi.org/10.1590/0102-672020190001e1470>.
- Magro, DO, Geloneze B, Delfini R, Pareja BC, Callejas F, Pareja JC. *Long-term Weight Regain after Gastric Bypass: A 5-year Prospective Study*. *Obesity Surgery*, 2018.18(6), 648–651. Available from: doi:10.1007/s11695-007-9265-1.
- Sociedade Brasileira de Cirurgia Bariátrica. [Online].; 2017 [cited 2021 08 02. Available from: <https://www.sbcm.org.br/tecnicas-cirurgicas-bariatrica/>
- Ribeiro MLDB. Resolução CFM N° 2.131/2015, Brasília, seção I,p.287. Disponível em: <https://sistemas.cfm.org.br/normas/visualizar/resolucoes/BR/2015/2131>. Acesso em: 2 out. 2021.
- Reis TN, Silva MMF, Silveira VFSB, Andrade RD. Resultados da cirurgia bariátrica a longo prazo. *Ciência et Praxis*. 2012; 6(10).



Teixeira AV. O balão intra-gástrico no tratamento da obesidade. *cadernosdesaude* [Internet]. 1Dez.2011 [citado 3Out.2021];4(Especial):49-4. Available from: <https://revistas.ucp.pt/index.php/cadernosdesaude/article/view/3035>.

Carvalho MR, et al. Balão Intra-gástrico no tratamento da obesidade Mórvida. *Acta Med Port*. 2011; 24, 489-498.

Gonçalves CS, Carvalho DR, Souza GC, Zanola LG, Santos LA, Resende MA, Souza G. Cuidados da equipe de enfermagem ao paciente em pós-operatório de bypass gástrico em y de roux. *Revista Eletrônica Acervo Saúde*. (2019) (21), e636. Available from: <https://doi.org/10.25248/reas.e636.2019>.

Costa M, Della L, et al. Repercussão da perda de peso sobre parâmetros nutricionais e metabólicos de pacientes obesos graves após um ano de gastroplastia em Y-de-Roux. *Revista do Colégio Brasileiro de Cirurgiões* [online]. 2010, v. 37, n. 2 [Acessado 3 Outubro 2021] , pp. 096-101. Disponível em: <<https://doi.org/10.1590/S0100-69912010000200005>>. Epub 07 Jun 2010. ISSN 1809-4546. <https://doi.org/10.1590/S0100-69912010000200005>.

Ministério da Saúde. PORTARIA N°425. Brasília, 2013. Seção 1, p.59. Disponível em: https://bvsmms.saude.gov.br/bvs/saudelegis/gm/2013/prt0425_19_03_2013.html Acesso em 2021.

Aretxabala UX, Leon CJ, Wiedmaier TG, Maluenda GF, Rossi FR, Benavides CC. Gastrectomía vertical posterior a retiro de banda gástrica. *RevChilCir* [Internet]. 2010 Dic [citado 2021 Oct 03] ; 62(6): 582-586. Disponible en: http://www.scielo.cl/scielo.php?script=sci_arttext&pid=S0718-40262010000600007&lng=es.

Nassif, Nunes PA, et al. Modificação técnica para a gastrectomia vertical. *ABCD. Arquivos Brasileiros de Cirurgia Digestiva (São Paulo)* [online]. 2013, v. 26, suppl 1 [Acessado 3 Outubro 2021] , pp. 74-78. Disponível em: <<https://doi.org/10.1590/S0102-67202013000600016>>. Epub 24 Jan 2014. ISSN 2317-6326.

Ramos AC, et al. TECHNICAL ASPECTS OF LAPAROSCOPIC SLEEVE GASTRECTOMY. *ABCD. Arquivos Brasileiros de Cirurgia Digestiva (São Paulo)* [online]. 2015, v. 28, n. Suppl 1 [Accessed 3 October 2021] , pp. 65-68. Available from: <<https://doi.org/10.1590/S0102-6720201500S100018>>. Epub 2015. ISSN 2317-6326.