



Diagnosis and management of diaphragmatic pericardial hernia: A case report

Diagnóstico e manejo de hérnia pericárdio diafragmática: Um relato de caso

DOI: 10.56238/isevjhv2n4-024

Receiving the originals: 25/07/2023

Acceptance for publication: 16/08/2023

Raíssa Paes Francino

Abraão Rodrigues Valentim do Prado

Eduarda Gomes Martins

Izadora Furlan

Mirelly Aparecida Nolasco Frinhani

Rebeca Alves Pestana

Paula Gomes Martins

ABSTRACT

INTRODUCTION Diaphragmatic hernias can be congenital or acquired. Congenital diaphragmatic hernia is a relatively common malformation and can be diagnosed in the prenatal period using ultrasound. After birth, computed tomography is the most accurate diagnostic test and helps to assess the anatomical relationships between the viscera. Traumatic diaphragmatic hernia (TDH) is characterized by the passage of part of the abdominal contents into the thoracic cavity through trauma to the thoracoabdominal transition. Pericardial diaphragmatic hernia is a direct communication between the pericardium and the peritoneal cavity, through a defect in the diaphragm. It can be congenital or associated with diaphragmatic rupture after trauma. **CASE PRESENTATION:** V.B, 57, complaining of chronic constipation, presented with a hiatus hernia on chest X-ray and CT scan. The images showed herniation of fat content and intestinal loops into the chest through the anteromedial wall of the left hemidiaphragm, compressing the medial aspect of the lingula, with no evidence of complications. On April 6, 2023, she underwent diaphragmatic herniorrhaphy via the thoracic route. She returned for post-operative follow-up complaining of nausea, vomiting and asthenia. A new total abdominal tomography scan showed the presence of an anterior diaphragmatic hernia on the left. Subsequently, she underwent a thoracic surgical approach with a proposal to correct the diaphragmatic hernia. However, an inventory of the cavity revealed plication of the lateral diaphragm without herniation points. The decision was therefore made to open the pericardium, showing a diaphragmatic pericardial hernia, with a 0.5 cm ring containing the epipelon, transverse colon and stomach in the pericardium. Adhesions were lysed and the contents returned to the abdominal cavity. The patient evolved satisfactorily in the postoperative period. **DISCUSSION:** Both diaphragmatic hernia and pericardial diaphragmatic hernia can be serious and require immediate medical intervention. They are rare pathologies that can be confused with other respiratory or cardiac diseases, making it difficult for doctors to diagnose them. Surgery is necessary to repair the hernia and reduce the risk of complications, which increase over time. **FINAL CONSIDERATIONS:** This case report highlights the complexity and importance of early and accurate diagnosis of diaphragmatic hernias, including



the rare pericardial diaphragmatic hernia. Diaphragmatic hernia, whether congenital, acquired through trauma or associated with diaphragmatic rupture, can result in painful complications if not recognized and controlled. The clinical situation presented in this case, in which a pericardial diaphragmatic hernia was identified during the postoperative period of a thoracic diaphragmatic hernia, highlights the importance of continuous surveillance after surgical intervention.

Keywords: Congenital diaphragmatic hernia, Pericardium, Thoracic surgery.

1 INTRODUCTION

Diaphragmatic hernias can be congenital or acquired. Congenital diaphragmatic hernia is a relatively common malformation, present in one to five babies per thousand live births. It appears to be more common in men and less common in blacks, and can be diagnosed in the prenatal period through ultrasound. In the presence of this comorbidity, respiratory and cardiac functions can be compromised at birth and cause significant morbidity for the child. Postnatal symptoms include respiratory discomfort due to poor oxygenation, a hollowed-out abdomen with sternal protrusion and displacement of the heart sounds to the contralateral side. These characteristics can appear at any age or even be a finding during routine examinations. Typically, radiological images show intrathoracic loops with contralateral deviation of the mediastinum. In some cases, complications such as obstruction or volvulus may arise. Computed tomography is the exam that allows for the most accurate diagnosis and helps assess the anatomical relationships between the viscera¹. Most adult patients have chronic symptoms, which include dyspnea, pleural effusion, chest pain, vague abdominal pain, postprandial fullness, nausea and vomiting².

Traumatic diaphragmatic hernia (TDH) is characterized by the passage of part of the abdominal contents into the thoracic cavity through trauma to the thoracoabdominal transition. Injuries can result from blunt trauma, when a sudden increase in intra-abdominal pressure is transmitted to the diaphragmatic domes, such as in car accidents and bruises; or penetrating trauma, which is more common and is usually caused by blunt weapons or firearm projectiles. They can be classified into three phases: acute, when the injury is identified and treated soon after the traumatic event; latent, in which the patient may present gastrointestinal or respiratory symptoms months or years after the trauma; and late, characterized by complications of HDT, such as obstructions and strangulation of hollow viscera³.

Diaphragmatic rupture is an uncommon condition caused by severe thoracoabdominal trauma^{1,2}. Pericardial-diaphragmatic hernia is even rarer, occurring in 0.2% to 3.3% of rupture cases³. It is a direct communication between the pericardium and the peritoneal cavity, through a

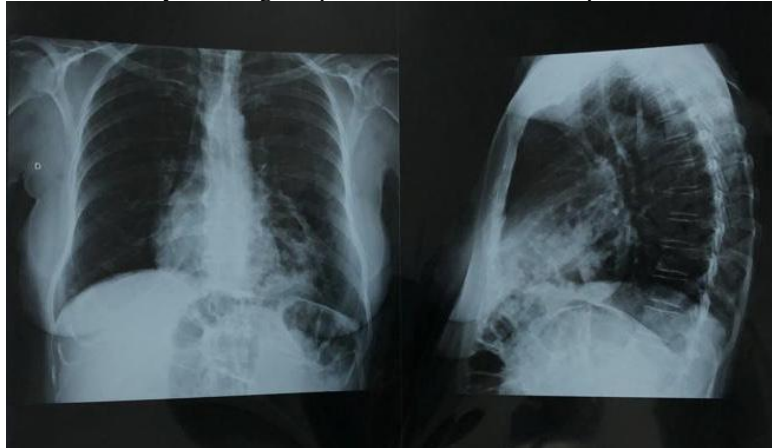
defect in the diaphragm. It can be congenital, due to a failure in the development of the transverse septum, or associated with diaphragmatic rupture after trauma⁴ .

2 CASE REPORT

V.B, 57 years old, with a history of fracture of the femur and pelvis in September 2021 and the need for a surgical approach by orthopedics, was referred to the gastroenterology service due to the presence of intestinal herniation in the thoracic region evidenced on chest X-ray and computed tomography. The patient's only complaint was chronic constipation, requiring daily use of lactulose and plantago.

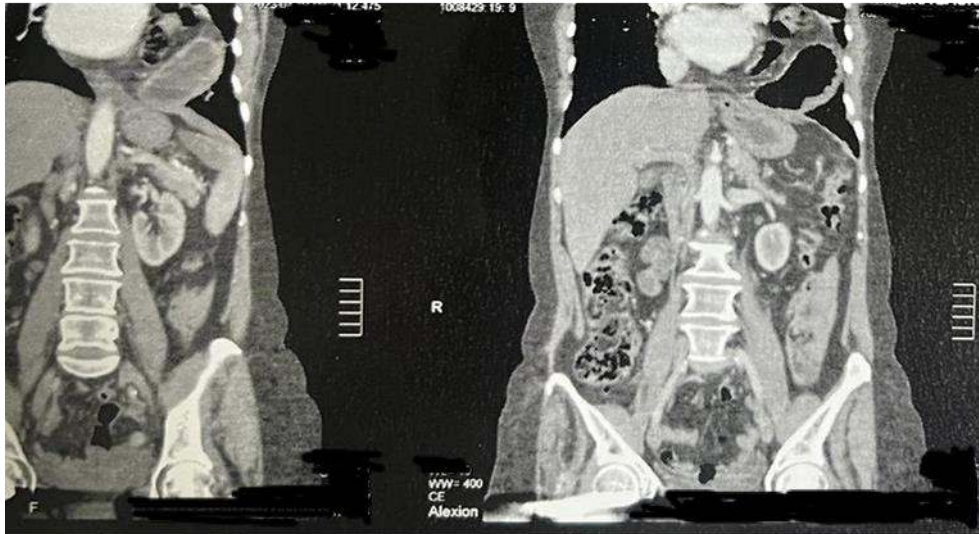
On imaging tests, the patient had a chest X-ray showing a hiatus hernia with colonic loops inside the left thoracic cavity, as shown below (Figure 1).

Figure 1 - Chest X-ray showing the presence of intestinal loops inside the chest cavity



In addition to a chest CT scan carried out on 07/06/2022, showing herniation of fat content and intestinal loops into the chest through the anteromedial wall of the left hemidiaphragm, compressing the medial aspect of the lingula, with no evidence of complications (Figure 2).

Figure 2 - Chest computed tomography



On April 6, 2023, she underwent diaphragmatic herniorrhaphy via the thoracic route, and intraoperatively identified the presence of a pleural effusion on the left associated with a hiatus hernia with a hernial ring of approximately 3 cm with visceral content.

The patient was referred to the intensive care unit in the immediate post-operative period, discharged from the ward to the ward on the second post-operative day and discharged from hospital on the third post-operative day.

He returned for post-operative follow-up complaining of nausea and vomiting for a week and asthenia. A new upper digestive endoscopy was then requested and clinical treatment was started with omeprazole 20 mg in the morning and domperidone 10 mg.

The patient sought care from a gastroenterologist in his city of origin, when he underwent a new total abdominal CT scan on April 19, 2023, which showed the presence of an anterior diaphragmatic hernia on the left, with herniation of adipose content, colonic loops and part of the gastric chamber, which was rotated, with torsion of the vessels and slight densification of the adjacent adipose planes, determining partial atelectasis of the lingula and left lower lobe.

With the imaging exam, he sought emergency care, where he was admitted to hospital with an indication for a surgical approach.

On April 24, 2023, she underwent a thoracic surgical approach with the proposal of correcting a diaphragmatic hernia. However, an inventory of the cavity revealed plication of the lateral diaphragm without herniation points. The decision was therefore made to open the pericardium, showing a pericardial diaphragmatic hernia, with a 05 cm ring containing the epipelon, transverse colon and stomach in the pericardium. Adhesions were lysed and the contents returned to the abdominal cavity.



The patient evolved satisfactorily in the postoperative period, and was discharged on the third postoperative day with a scheduled return to the thoracic surgery outpatient clinic for follow-up.

3 DISCUSSION

Diaphragmatic hernia occurs when part of the abdominal contents or organs move into the thorax through a hole in the diaphragm⁴. On the other hand, pericardial diaphragmatic hernia is an even rarer condition and occurs when there is communication between the pericardium and the peritoneal cavity⁵. Both conditions can be serious and require immediate medical intervention. They are rare conditions that can easily be confused with other respiratory or heart diseases, which makes it difficult for doctors to diagnose them.⁶

In this report, we present an unusual case in which, during the postoperative period of thoracic diaphragmatic herniorrhaphy and with the persistence of symptoms, it was possible to diagnose a diaphragmatic pericardial hernia in addition to the diaphragmatic hernia. Early diagnosis is essential to prevent serious complications, such as torsion of the herniated organ or intestinal preservation. In the case reported, the patient had torsion of the vessels and slight densification of the adjacent fat planes, showing a more serious condition⁷.

Surgery is necessary to repair the hernia and reduce the risk of complications, which increase over time. Furthermore, it is important for doctors to consider the possibility of diaphragmatic or pericardial diaphragmatic hernia in patients with unexplained respiratory or cardiac symptoms, especially those accompanied by abdominal pain and other gastrointestinal manifestations. Early diagnosis is essential for successful treatment and to minimize negative outcomes for the patient⁸.

4 CONCLUSION

In this case report, we highlight the complexity and importance of early and accurate diagnosis of diaphragmatic hernias, including the rare pericardial-diaphragmatic hernia. As mentioned, these conditions represent experimental challenges due to their rarity and the diversity of symptoms that can mimic other respiratory or cardiac conditions¹.

Diaphragmatic hernia, whether congenital, acquired through trauma or associated with diaphragmatic rupture, can result in painful complications if not recognized and controlled. Its diagnosis often requires a multimodal approach, including advanced imaging tests such as CT scans, which provide a detailed view of the anatomical structures involved¹.



The clinical situation presented in this case, in which a pericardial diaphragmatic hernia was identified during the postoperative period of a thoracic diaphragmatic hernia and intraoperatively of a reoperation, highlights the importance of continuous surveillance after surgical intervention. The presence of persistent or new symptoms should be investigated in order to avoid possible complications and ensure timely therapeutic action⁸.

Surgery has emerged as the main treatment for these conditions, aimed at correcting the hernia and restoring normal anatomy. In the case reported, surgical reapproach was necessary to correct the pericardial diaphragmatic hernia, highlighting the importance of an individualized approach and the medical team's ability to adapt treatment according to intra-surgical findings². In short, this case report highlights the need for a high index of suspicion and in-depth assessment in patients with unexplained respiratory, cardiac or gastrointestinal symptoms, especially when accompanied by signs of hernia or abdominal protrusion. Successful treatment depends on early diagnosis, an interdisciplinary approach and the appropriate choice of therapeutic interventions, in order to ensure the patient's full recovery and possible complications are minimized. The constant search for advances in the understanding and treatment of these rare conditions is essential to improve medical care and the quality of life of hospitalized patients¹.



REFERENCES

- Bianchi E, Mancini P, De Vito S, Pompili E, Taurone S, Guerrisi I, Guerrisi A, D'Andrea V, Cantisani V, Artico M. Congenital asymptomatic diaphragmatic hernias in adults: a case series. *J Med Case Rep.* 2013 May 13;7:125. doi: 10.1186/1752-1947-7-125. PMID: 23668793; PMCID: PMC3668166.
- Hemanth Rathod R, Rajan YR, Potluri V. Congenital Right Diaphragmatic Hernia Presenting in Adult Life: A Rare Case. *Cureus.* 2022 Nov 6;14(11):e31168. doi: 10.7759/cureus.31168. PMID: 36483901; PMCID: PMC9725177.
- Kalil M, TCBC-ES, Rodrigues JBSR, Lima MB, Pancini TR, Lugão RS, et al. Hérnia diafragmática traumática: relato de dois casos com 20 e 52 anos de evolução. *Relatos Casos Cir.* 2016;(2):1-4
- Garcia LDS, de Melo ASA, Cañete LAQ. Traumatic rupture of the diaphragm with pericardial diaphragmatic hernia. *Radiol Bras.* 2018 Sep-Oct;51(5):347-348. doi: 10.1590/0100-3984.2017.0060. PMID: 30369673; PMCID: PMC6198840.
- Garcia LDS, de Melo ASA, Cañete LAQ. Traumatic rupture of the diaphragm with pericardial diaphragmatic hernia. *Radiol Bras.* 2018 Sep-Oct;51(5):347-348. doi: 10.1590/0100-3984.2017.0060. PMID: 30369673; PMCID: PMC6198840.
- Lee JH, Kim SW. Small bowel strangulation due to peritoneopericardial diaphragmatic hernia. *J Cardiothorac Surg.* 2014 Apr 2;9:65. doi: 10.1186/1749-8090-9-65. PMID: 24694166; PMCID: PMC4230424.
- Nagy KK, Barrett JA. Diaphragm. In Rao R. Ivatury/ C.Gene Cayten: *The textbook of penetrating trauma.* 1 edição. Williams & Wilkins, USA, Cap. 45, 1996; pág.564-570.
- Degiannis E, Levy RD, Sofianos C, Potokar T, Florizoone MG, Saadia R. Diaphragmatic herniation after penetrating trauma. *Br J Surg.* 1996 Jan;83(1):88-91. doi: 10.1002/bjs.1800830128. PMID: 8653376
- Öz N, Kargı AB, Zeybek A. Co-existence of a rare dyspnea with pericardial diaphragmatic rupture and pericardial rupture: a case report. *Kardiochir Torakochirurgia Pol.* 2015 Jun;12(2):173-5. doi: 10.5114/kitp.2015.52865. Epub 2015 Jun 30. PMID: 26336505; PMCID: PMC4550023.