



## Secretin magnetic resonance cholangiopancreatography (s-MRCP) in the diagnosis of early chronic pancreatitis: Why not?

DOI: 10.56238/isevjhv2n6-002

Receipt of originals: 06/10/2023

Publication Acceptance: 11/24/2023

**Antonio Duarte Cabral**

ABC School of Medicine (FMABC)

**Juliana de Vasconcellos Barbosa**

ABC School of Medicine (FMABC)

**Maria Rita Vieira dos Santos Cunha**

ABC School of Medicine (FMABC)

**Ethel Zimberg Chehter**

ABC School of Medicine (FMABC), Santo André, SP, Brazil

### ABSTRACT

Chronic pancreatitis is a syndrome with several conditions, resulting in similar phenotypic manifestations. Pancreatic biopsy would be the gold standard for its diagnosis, but it is often not possible to perform it. When chronic pancreatitis is suspected, early diagnosis facilitates proper management and prevents complications. In this context, secretin-induced magnetic resonance cholangiopancreatography (s-MRCP) is one of the tests used. This study aims to understand the accuracy and efficiency of s-MRCP in the early diagnosis of chronic pancreatitis, comparing its results with those of other methods used for this purpose, also analyzing its cost-benefit. A systematic review according to PRISMA recommendations was conducted. The data from each article used were summarized in a table with the following topics: DOI; first author; year; place of performance; type of study; target population; importance of s-MRCP; other methods and conclusions. Articles with adults over 18 years of age were included; in English or Spanish; talk about s-MRCP; studies starting in 2018; articles comparing researched techniques. Articles such as case reports, editorials and editors' opinions, and animal studies were excluded. Articles from previous years have been added to expand the scarce literature. S-MRCP is a minimally invasive test that analyzes pancreatic structure and function, presenting diagnostic results comparable to and even superior to those of other methods. She faces difficult access to specialized professionals in addition to the high costs of equipment and secretin. However, as early diagnosis can contain the evolution of the disease, avoiding costs with future treatment, investing in this test is valid and necessary.

**Keywords:** Magnetic resonance cholangiopancreatography, Pancreas, Secretin, Early chronic pancreatitis, Secretin-enhanced magnetic resonance cholangiopancreatography.

### 1 INTRODUCTION

The pancreas is a retroperitoneal gland accessory to digestion, located overlying and transversely to the bodies of the L1 and L2 vertebrae in the posterior wall of the abdomen. It is responsible for the production of exocrine (pancreatic juice, produced by acinar cells) and



endocrine (glucagon and insulin, produced by pancreatic islets) secretion. It is divided into head, neck, body, and tail. The head of the pancreas is the extended part of the gland surrounded by the C-shaped curvature of the duodenum, to the right of the superior mesenteric vessels and attached to the medial aspect of the descending and horizontal parts of the duodenum. The uncinate process is a projection of the head of the pancreas and extends medially to the left, posterior to the superior mesenteric artery. On its way to open in the descending part of the duodenum, the common bile duct is in a groove on the superior poster surface of the head or is inserted into its substance. The neck of the pancreas is short and is situated over the superior mesenteric vessels, which leave a groove on its posterior surface. The anterior aspect of the neck is covered by peritoneum. The body of the pancreas is a continuation of the neck and is located to the left of the superior mesenteric vessels, passing over the aorta and the L2 vertebra. The anterior surface of the body of the pancreas is covered by peritoneum and is situated on the floor of the omental pouch and forms part of the stomach bed. The posterior aspect has no peritoneum and is in contact with the aorta, superior mesenteric artery, left adrenal gland, left kidney, and left renal vessels. The tail of the pancreas is located anterior to the left kidney, where it is closely related to the splenic hilum and the left flexure of the cervix and is relatively mobile, passing between the layers of the splenorenal ligament along with the splenic vessels. The pancreatic duct begins at the tail of the pancreas and runs through the gland parenchyma to the head of the pancreas. From then on, it turns inferiorly and has an intimate relationship with the common bile duct. The pancreatic duct and common bile duct usually join together to form the short, dilated hepatopancreatic ampulla, which opens in the descending part of the duodenum at the summit of its greater papilla. In at least 25% of people, the ducts open in the duodenum separately. The arterial supply to the pancreas comes mainly from the branches of the splenic artery, which is very tortuous. Several pancreatic arteries form several arches with pancreatic branches of the gastroduodenal and superior mesenteric arteries.<sup>1</sup> Venous drainage of the pancreas is done by means of the corresponding pancreatic veins, tributaries of the splenic and superior mesenteric parts of the portal vein and most of them drain into the splenic vein.<sup>1,2</sup>

Pancreatic physiology can be characterized as complex, since this organ has both exocrine and endocrine functions, both essential in the digestion process and energy metabolism. The endocrine portion is histologically composed of cell clusters called islets of Langerhans, which are composed of different groups of cells, each responsible for the secretion of a hormone, namely:

---

<sup>1</sup> Abbreviations: (CP), chronic pancreatitis; (s-MRCP), secretin-enhanced magnetic resonance cholangiopancreatography; (ERCP) endoscopic retrograde cholangiopancreatography; (MRCP), magnetic resonance cholangiopancreatography; (EU), endoscopic ultrasonography (EU); (CT), computed tomography; (PD), pancreatic duct.



glucagon, insulin, somatostatin, vasoactive intestinal polypeptide, pancreatic polypeptide, gastrin and ghrelin. The exocrine portion, on the other hand, is made up of acinar cells, organized in the form of acini, responsible for the production and secretion of digestive enzymes. Initially, acinar cells store their inactive enzymes, in the form of zymogen granules, when stimulated, they are activated and the enzymes are released by exocytosis.<sup>2</sup> One of the triggers of this function is secretin, a substance secreted by the S cells of the duodenum, which acts on the pancreas by stimulating the release of bicarbonate and pancreatic juice, which is essential for food digestion.<sup>3</sup>

Chronic pancreatitis (CP) is a syndrome that includes a spectrum of conditions that result in similar phenotypic manifestations. Repetitive episodes of inflammation of varying intensity and duration in individuals with genetic, environmental, and anatomical risk factors generate irreversible damage to pancreatic tissue. Chronic inflammation, fibrosis, and destruction of exocrine ductal tissue (acinar cell) and endocrine ductal tissue (islets of Langerhans) characterize the histology of chronic pancreatitis, producing varying degrees of symptoms and structural and functional derangements of the gland.<sup>4</sup>

According to the Marseille-Rome classification, chronic pancreatitis can be divided into three forms: chronic calcific pancreatitis, chronic obstructive pancreatitis, and chronic autoimmune pancreatitis, with calcific pancreatitis being the most common. Chronic obstructive pancreatitis is a result of primary pancreatic duct injury or partial or complete ductal obstruction. Chronic autoimmune pancreatitis is a form in which inflammation responds rapidly to corticosteroids, and chronic calcific pancreatitis results in the development of intraductal stones, ductal strictures and distortions, pancreatic atrophy, and parenchymal calcifications.<sup>13</sup> Extensive destruction of the pancreatic parenchyma leads to steatorrhea and diabetes.

The most prevalent risk factors for chronic pancreatitis are alcohol consumption and (dose-dependent) smoking. Alcohol abuse is the most common etiology of CP, being diagnosed in 42 to 77% of patients. Idiopathic CP is the second most common type and affects 28% to 80% of people with the disease. Although alcohol and tobacco use are the most prevalent risk factors among adult patients with chronic pancreatitis, the cause of CP is thought to be associated with multiple susceptibilities.<sup>5,6</sup>

Considering a wider range of studies of varying methodological quality, based on heterogeneous populations, it is estimated that the incidence of chronic pancreatitis ranges from 4.4 to 14 per 100,000 people, with a prevalence of 36.9–52.4 per 100,000 people, with a male predominance by a factor of 1.5–4.6 and a median survival of 20 years. However, if only high-quality studies, such as Xiao's systematic review, are considered, the global pooled incidence of

chronic pancreatitis is ten cases (95% confidence interval 8-12) per 100,000 population per year. The regions with a high incidence (greater than 34 cases per 100,000 inhabitants per year) are North America and the Western Pacific.<sup>7, 8,10</sup>

The pathophysiology of chronic pancreatitis remains not completely elucidated. Although it is unlikely that all etiologies share the same mechanisms, the outcomes are similar.<sup>5</sup> Histologically, there is loss of the cell parenchyma, chronic inflammation, and fibrosis, caused, respectively, by cell necrosis or apoptosis, the effect of pro-inflammatory cytokines, and activation of stellate cells.<sup>6</sup> The main etiologies can be summarized in the acronym TIGAR-O, which stands for: T (toxic-metabolic), I (idiopathic), G (genetic), A (autoimmune), R (recurrence of acute pancreatitis), and O (obstruction).<sup>11</sup>

Chronic toxic-metabolic pancreatitis is associated with alcohol and tobacco use, hypertriglyceridemia, hypercalcemia, and chronic kidney disease, each independent of each other. Although the development of the disease is dose-dependent, there is no specific dose for its occurrence.<sup>12</sup> In this process, pathogenesis involves two main mechanisms, the injury of acinar cells by direct toxic-metabolic action and oxidative stress caused by the presence of free radicals. Also, in the case of alcoholic pancreatitis, in addition to damaging the acini, alcohol causes ductal injury and can stimulate the activation of stellate cells, causing a fibrotic process.<sup>6</sup>

Chronic idiopathic pancreatitis, on the other hand, can be classified into two groups, early-onset or late-onset. Those conditions that have an early onset manifest between the second and third decades of life and have a clinical picture of severe abdominal pain, but late development of structural and functional manifestations of pancreatitis. On the other hand, late-onset cases usually occur between the sixth and seventh decades of life and have pain as a less frequent symptom, but when the disease is discovered, structural and functional changes are usually already installed.<sup>13</sup>

There are several genetic mechanisms involved in the pathophysiology of chronic pancreatitis, the main ones being premature activation of trypsinogen or failure to inactivate trypsin in acinar cells, ductal obstruction due to inadequate bicarbonate flow and protein denaturation leading to the production of free radicals. The main and most studied alteration is the autosomal dominant mutation of the *PRSS1* gene, responsible for encoding the cationic trypsinogen enzyme. Recessive gene mutations may also be involved in this process, with the *SPINK1* and *CFTR* genes being the main ones.<sup>5</sup>

Autoimmunity is related to chronic inflammation and pancreatic fibrosis with good response to corticosteroid treatment. Chronic autoimmune pancreatitis (AIP) can be divided into two types: type 1 and type 2. Chronic autoimmune pancreatitis type 1 has as its pathophysiology



the accumulation of lymphoplasmacytic infiltrate with periductal IgG4 expression, without destruction of the pancreatic ducts, and is commonly associated with extra-pancreatic involvement. On the other hand, type 2 IPA is related to neutrophilic pancreatic infiltrate, associated with microabscesses and ductal involvement, but extra-pancreatic manifestations are rare. Both types can present with jaundice or acute pancreatitis, but the incidence of these manifestations varies depending on each type.<sup>14th</sup>

Chronic pancreatitis can also develop after a case of severe pancreatitis, usually associated with necrosis or the need for surgical intervention. In addition, the recurrence of episodes of acute pancreatitis can lead to the development of a chronic inflammatory condition of the pancreas, caused by the continuous secretion of pro-inflammatory cytokines or activation of stellate cells.<sup>15th</sup>

Pancreatic obstruction causes damming of pancreatic juice in the pancreatic duct, causing activation of digestive enzymes within the acini, consequently leading to tissue destruction and fibrosis. This obstruction can be caused by both benign and malignant factors. Among benign ones, there is ductal stenosis, presence of gallstones or calcifications, trauma, and pancreas divisum. Among the malignant causes, pancreatic adenocarcinoma and ductal ampullary carcinoma are the main ones.<sup>6</sup>

The clinical picture of chronic pancreatitis is not exuberant in all patients. Abdominal pain is the most prevalent symptom and the one that most affects quality of life. Although there is no single pattern of pain described, the pain of chronic pancreatitis is most often described as localized to the epigastrium with irradiation to the back, commonly associated with nausea and vomiting. Severe pain can be associated with anorexia, weight loss, and malnutrition. In the long term, with the progression of the disease, manifestations associated with exocrine and endocrine pancreatic insufficiency may arise, which manifest with poor digestion of fats, associated with steatorrhea and diabetes mellitus, respectively.<sup>16</sup>

When it comes to diagnosis, pancreatic biopsy would be the gold standard, but it is not possible to perform it most of the time. Thus, the diagnosis must come from some type of imaging test and this involves ultrasound, endoscopic retrograde cholangiopancreatography (ERCP), magnetic resonance cholangiopancreatography (MRCP), endoscopic ultrasonography (EU) or computed tomography (CT).

Ultrasonography shows changes in parenchymal texture, pancreatic size, shape, and contour, dilation of the pancreatic and main bile ducts, calcifications, presence of fluid collections, and patency of the portal venous system.<sup>21</sup> Pancreatic atrophy, despite being a late feature of chronic disease, may not be apparent because peripancreatic fat and fibrotic gland tissue are



visualized as hyperechoic structures. In addition, the addition of a color Doppler to the examination may allow the identification of pseudoaneurysms, presence of collateral pathways, and thrombosis of the portal system.<sup>21</sup>

In ERCP, the changes seen are concentrated in the main pancreatic duct and lateral branches. Among them, ectasia of the lateral branch of the pancreatic duct, multifocal dilatations, the main duct and lateral branches with irregular structures and contours, as well as filling defects, such as stones, mucinous plugs or debris, and pseudocysts stand out.

MRCP is a non-invasive test that provides projection images of the bile ducts and pancreatics and combines the advantages of cross-sectional imaging techniques such as ultrasound and CT. However, its role in chronic pancreatitis is still controversial, since it has a lower spatial resolution, not allowing the evaluation of mild pancreatitis abnormalities. The differential in this technique is the possibility of administering secretin for a better visualization of morphological characteristics in patients with suspected chronic pancreatitis.<sup>21</sup> In these cases, there would be no ductal alteration if only ultrasound or CT were performed, and secretin stimulation would provide additional data, as will be discussed later.

UE is a more appropriate and sensitive technique for diagnosing parenchymal and ductal changes, especially in the early stages of chronic pancreatitis.<sup>21</sup> In this sense, it is a technique widely used when CT and MRI are negative or doubtful in patients with this clinical suspicion. However, the alterations identified through this technique are not necessarily due to pancreatitis, but to normal aging, smoking, alcohol consumption, obesity and diabetes.

On CT scans, the findings are dilatation of the main pancreatic duct, parenchymal atrophy, pancreatic calcifications, and pseudocysts. Although atrophy is more common in chronic pancreatitis, CT can occasionally identify pancreatic enlargement due to extensive interlobular and periductal fibrosis.<sup>21</sup>

In addition, as the objective of this review is more related to the evaluation in the case of suspected early chronic pancreatitis, it is also necessary to detail the diagnosis at an early stage, in which the development of complications can be prevented by appropriate management. In this context, several tests and examinations are under development, such as pancreatic function tests with secretin, pancreatic elastography, new biomarkers of early chronic pancreatitis, genetic markers, and the main focus of this review, Secretin-induced Magnetic Resonance Cholangiopancreatography (s-MRCP).

Secretin pancreatic function tests are one of the oldest tests involved in the diagnosis of pancreatic diseases and are highly accurate in excluding patients with early chronic pancreatitis,



with a negative predictive value of 97%. In addition, they were combined with other exams, such as endoscopy, offering structural and functional evaluations in the same session.<sup>21</sup>

Pancreatic tension wave elastography, on the other hand, when combined with endoscopic ultrasound, has been shown to be an accurate method for detecting fibrosis compared to histology. Another elastography modality, shear wave ultrasound using transabdominal US, can also be used to diagnose chronic pancreatitis early, objectively and noninvasively.<sup>18th</sup>

The new biomarkers, such as microRNAs, involve nanovesicles in cell-to-cell communication and in the regulation of different biological processes, being present during normal and pathological states. MicroRNAs, which are inside exosomes, have distinct shapes and appear at different stages of development of chronic pancreatitis.

Genetic markers involve a list of genes associated with pancreatitis and can be used for risk assessment.<sup>18th</sup>

Returning to the main point of this study, it is important to delve deeper into the secretin technique, starting with the fact that the effects of secretin change over time, reaching the maximum response depending on factors such as injection time. Secretin is administered intravenously, preferably with the use of long tubes to prevent the patient from moving around in the MRI unit. After secretin administration, it is recommended to irrigate the tube with a saline solution of approximately 20 ml.<sup>17th</sup>

Images should be acquired from a plane centered on the pancreatobiliary ductal system and the recommendation is to use images of heavily weighted 2D T2-weighted coronal plaques in the evaluation. An angled coronal plane is more effective and can be selected based on the radial plate that provided the best visualization of the main pancreatic duct on previous MRCP images.<sup>17</sup> Once this angle is chosen, it should remain the same throughout the secretin imaging to improve visualization of dynamic changes in the pancreatic ducts.<sup>17th</sup>

The sequences are performed quickly and allow for the acquisition of instantaneous images of the pancreatobiliary system as secretin takes effect. Apnea imaging is recommended every 30–60 seconds. This time interval allows titration with the patient's ability to perform apneas while also allowing for dynamic analysis. Taking images for 8 to 9 minutes is enough.

In addition, intravenous agents, such as hyoscine butylbromide or glucagon, can be used to try to decrease the motion artifact and improve the quality of the MRI or MRCP image.<sup>17</sup> However, the routine use of these agents is not recommended because they decrease peristalsis and limit the physiological filling of the duodenum with fluid after secretin administration.



In conclusion, s-MRCP, which is the subject of this review, detects subtle ductal changes and is more accurate than standard MRCP. In addition, it also provides an assessment of pancreatic exocrine function by detecting intensity changes in the second part of the duodenum after secretin administration.<sup>18th</sup>

## **2 OBJECTIVES**

### **2.1 PRIMARY OBJECTIVE**

The main objective of this study is to learn more about the accuracy of s-MRCP and to verify its efficiency for the early diagnosis of chronic pancreatitis.

### **2.2 SECONDARY OBJECTIVE**

To compare the results of s-MRCP with those of other methods used in the diagnosis of early chronic pancreatitis and to analyze its cost-benefit

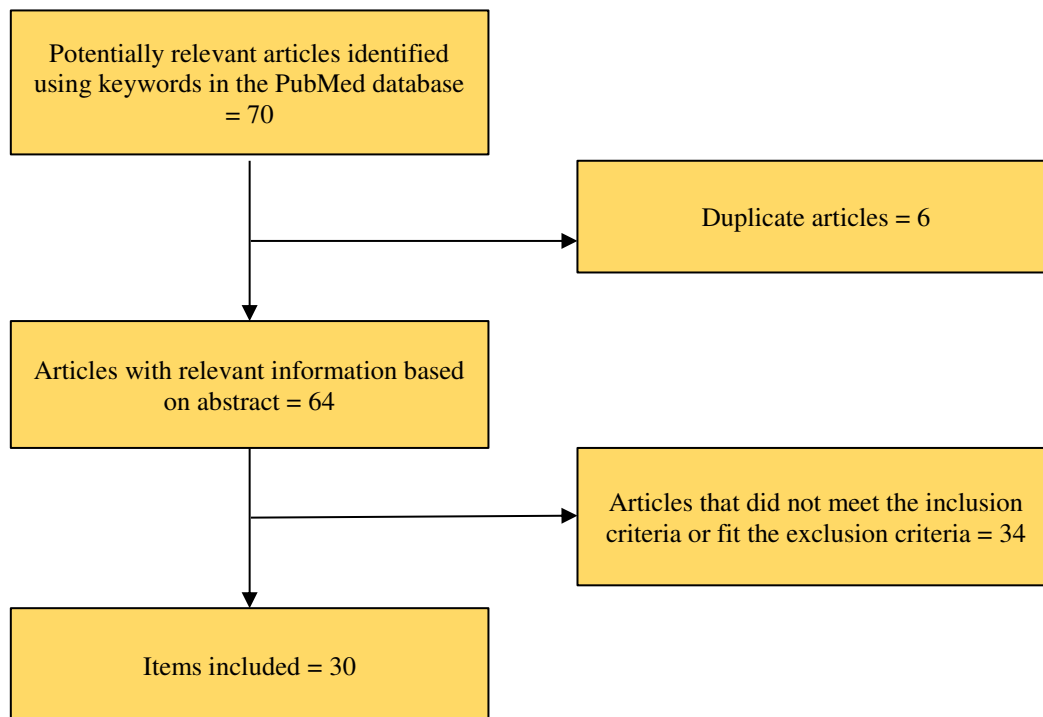
## **3 MATERIALS AND METHODS**

In the present study, a systematic review was conducted according to the recommendations of the summary of Main Items for Reporting Systematic Reviews and Meta-analyses, or PRISMA. It should be noted primarily that this study does not present a risk of bias, being only based on the risks of the studies contemplated in this article. Our study was not registered and the approval of the ethics committee is not necessary, as it is not a field study with patients. The literature search was carried out in the Pubmed and Google Scholar databases and in the books "Sleisenger and Fordtran's Gastrointestinal and Liver Disease- 2 Volume Set: Pathophysiology, Diagnosis, Management 11th Edition" and "Clinically Oriented Anatomy (Moore)", from 04/15/23 to 09/10/23, when the last source was consulted. The search was performed using the following keywords: sMR cholangiopancreatography; pancreas; secretin; early chronic pancreatitis; cholangiopancreatography, magnetic resonance and secretin and early diagnosis. An analysis of the articles was carried out by 3 independent researchers. The inclusion criteria for the selected articles were: adults over 18 years of age, in English or Spanish literature; talk about s-CPRM; studies from 2018 onwards; articles that compare the researched techniques and prioritize reviews. Articles such as case reports, editorials, and editor's opinions, as well as animal studies, were excluded. As the literature found was scarce, there was a need to expand the criteria to older articles, extending to studies more than 15 years old from the current date. As a result, a more extensive base of analysis was obtained between the methods, making it possible to gather articles

with recent and updated information, with a language that was understandable to the researchers, and with the patient profile that was explored in the review.

The studies identified by the search strategy above were selected for inclusion using a two-step process. First, each of the 3 researchers independently analyzed the titles and abstracts of each study, eliminating duplicate articles and articles with exclusion criteria. At the end of the selection, 30 articles were selected. In addition, the full text was written with other potentially relevant extra articles.

The form was made with the data from each article, which were included in a table that presented the following topics: DOI; name of the first author; year; place of conduction; type of study; target population (age and gender); importance of s-CPRM in the assessment of initial CP; other methods analyzed and conclusions. From the data in the file, other tables were constructed to facilitate the results found and the discussions of each one of them.



## 4 RESULTS

### 4.1 YEAR

Last 5 years	9 articles
5 -10 years	5 articles
10 -15 years	7 articles
More than 15 years	9 articles



Regarding the year of publication, when defining 5-year groupings, 9 articles on the subject were found in the last 5 years, 5 articles between 5 and 10 years ago from the present date, 7 articles between 10 and 15 years ago, and 9 articles were published more than 15 years ago. Initially, the purpose of the review was to encompass the most recent articles on the subject, however, due to the low publication rate, it was decided to extend the criteria of year of publication.

Greater than 50% female	5 articles
Greater than 50% male	4 articles
Not specified	21 articles

#### 4.2 SEX

Regarding the gender of the patients, only 5 of them specified that the study population was predominantly female and only 4 articles obtained a majority male population. Most of the tabulated articles, 21 of them, did not make it clear what the gender of the participants was.

#### 4.3 AGE

The mean age of the patients in the studies analyzed was 46.88 years.

#### 4.4 VENUE

USA	16 articles
England	3 articles
Germany	2 articles
Denmark	1 item
Hungary	1 item
Austria / Portugal	1 item
Japan	1 item
China	1 item
India	1 item
Korea / USA	1 item
Belgium	1 item



Multicenter	1 item
-------------	--------

16 articles were carried out in study centers in the United States, 3 articles in England and 2 articles in Germany. The other studies were each conducted in a different country, one of which was multicenter.

Considering a continental division, 17 articles were written in America, all in the United States, 9 in Europe and 4 in Asia.

In addition to the multicenter study, 1 study was developed jointly by the United States with Korea and 1 by Austria with Portugal.

#### 4.5 TYPES OF STUDY

Narrative Review	14 articles
Clinical Trial	1 item
Systematic Review	4 articles
Multicenter Study	1 item
Cross-sectional study	10 articles

Regarding the types of studies analyzed in this review, 14 articles are narrative reviews and 4 are systematic reviews. 1 study is of the clinical trial type and 1 study is multicenter. In addition, 10 are cross-sectional studies.

#### 4.6 IMPORTANCE OF S-CPRM

Visualizing the ductal anatomy	20 articles
Analysis of pancreatic function	17 articles

Regarding the importance of s-MRCP in the evaluation of the pancreas, the visualization of the pancreatic anatomy was classified as one of the main points evaluated by this technique in 20 articles. In addition, in 17 articles, the analysis of pancreatic function was an essential factor in assessing the importance of this method.

#### 4.7 OTHER METHODS REVIEWED

ERCP	12 articles
TC	6 articles
RM	9 articles
CPRM	11 articles
Pancreatic function test with secretin	4 articles
SELVES	8 articles
Other	6 articles

The methods, ERCP, CT, MRI, CPRM, pancreatic function test with secretin, EUS were cited in the analyzed articles to aid in the diagnosis of chronic pancreatitis. ERCP was analyzed in 12 articles, CT in 6, MRI in 9, MRS in 11 studies, pancreatic function test in 4, and EUS in 6. In addition to these methods, which were analyzed more frequently and in depth, the DWI signal, IVIM, T1 mapping, MR spectroscopy, and MRI elastography were also analyzed.

#### 4.8 EFFICIENCY OF S-CPRM FOR EARLY DIAGNOSIS OF CHRONIC PANCREATITIS

Yes	20 articles
No	1 item
Inconclusive	9 articles

Regarding the efficiency of S-MRCP, 20 articles concluded that it is a good diagnostic method in the early stages of chronic pancreatitis. Only 1 article concluded negatively about its efficacy and 9 articles did not reach concrete answers about the effectiveness of the method, highlighting that more studies would be needed to affirm something.

## 5 DISCUSSION

### 5.1 YEAR

As this is a relatively recent examination, developed in the last two decades<sup>45</sup>, the initial purpose of this review was to use only the most current articles published in the last 5 years. However, we found few articles published in this time interval that fit the inclusion criteria, so we increased the time interval of the studies included in this study. By separating the 30 articles analyzed into two groups, it was possible to associate each of the groups with the main conclusions



of the studies. In the group of articles published more than 10 years ago, a common theme in their conclusion is the hope of good results. Multiple articles presented positive initial results and point to the need for further studies to confirm them. The most recent articles, on the other hand, specifically show the benefits and specificities of the method, but report the need for an international consensus for the diagnosis of early chronic pancreatitis.

## 5.2 SEX

In this sample, something unexpected was found, the equality in the distribution between men and women, with five articles in which 50% of the analyzed population was female, four in which the majority was male and 21 in which the gender was not specified. A predominantly male population was predicted in the studies analyzed, since the prevalence of the disease, according to current estimates, is higher in this population by a factor of 1.5-4.6.<sup>10</sup> However, the number of articles analyzed in this study that contain information on the sex of the observed population is small, so this distribution is not necessarily equal between men and women. Because this distribution covers only this small sample, it is not possible to extrapolate such data.

## 5.3 AGE

The mean amount, duration of consumption, and cumulative alcohol exposure are the most important determinants of the increased risk of alcohol-related pancreatitis, which is the most common etiology of CP.<sup>9</sup> The dependence on chronic consumption for the development of the condition may justify a mean age of 46.88 for the diagnosis of patients. In addition, patients in the initial stage of the disease are mostly asymptomatic and without characteristic findings of CP in routine imaging tests<sup>10</sup>, which means that a more specific test is performed late. This corroborates the need for a test that is capable of diagnosing the disease in its early stage, especially for those who are in a group considered to be at risk.

## 5.4 VENUE

The patient is the subject who can satisfy the needs and interests of a medical investigator in his or her research. This fact becomes more evident and takes on particularities when considering research projects involving clinical trials in developing countries. In these countries, the target populations have little access to health services, little understanding of the risks of the study, and also less ability to take legal action in the event of damage.<sup>46</sup> From this analysis, it is clear why most research, whether done with patients or based on previous articles that used patients, focuses on developed and economically privileged countries, such as



the USA, England, and Germany. In developing countries, all these issues still hinder scientific development in several areas, such as the availability of research centers, resources to finance research, lack of patients to undergo studies, and ethical issues involving scientific work.

## 5.5 TYPES OF STUDY

Most of the studies found were classified as secondary, according to the originality of the study. Secondary studies are those that seek to establish conclusions from primary studies, with records common to them. They include non-systematic reviews of the literature, systematic reviews with and without meta-analysis, and review articles. They include guidelines offering guidance for clinical medicine, as well as decision analysis and economic analysis studies. They also constitute the majority of publications in medical textbooks.<sup>47th</sup>

In addition, some cross-sectional studies were found, i.e., those models that present themselves as a photograph or instantaneous cut that is made in a population by means of a sampling, examining the presence or absence of exposure and the presence or absence of the effect (or disease) in the members of the casuistry or sample. Its main advantages are the fact that they are low-cost and that there are practically no follow-up losses.<sup>47th</sup>

Only 1 study was a clinical trial, i.e. one involving patients (humans), where the investigators assign eligible people to intervention groups.<sup>47th</sup>

Therefore, it is necessary to consider that the s-CRPM is a relatively expensive test. In addition, less familiarity with its indications, examination technique, and interpretation of images also contribute to its limited use.<sup>24</sup> This cost factor is a determining factor in the choice of scientific research, which explains the findings predominantly of low-cost studies, such as cross-sectional studies, or studies that seek to establish conclusions based on primary studies, such as reviews and multicenter studies.

## 5.6 IMPORTANCE OF S-CPRM

Secretin-enhanced magnetic resonance cholangiopancreatography provides a non-invasive way to assess pancreatic duct anatomy and exocrine pancreatic function. In addition, it can detect subtle changes in these two variables, which allows the diagnosis of pancreatic diseases early rather than in the terminal stage.<sup>24th</sup>



Visualization of the pancreatic duct (PD) is of extreme significance for the detection and characterization of many pancreatic disorders, because the vast majority of pancreatic diseases originate from or are close to PD.<sup>24th</sup>

In addition, in order to establish an early diagnosis, it is necessary to be based on morphological and functional characteristics, since the change in morphology does not necessarily correlate with exocrine dysfunction, explaining the need to evaluate exocrine pancreatic function separately.<sup>24th</sup>

From this point on, it is clear why most articles evaluate pancreatic anatomy and function after s-MRCP examination, since these two alterations are the most prominent in the identification of early chronic pancreatitis.

## 5.7 OTHER METHODS REVIEWED

### 5.7.1 USE, ERCP and CPRM

Diagnosing chronic pancreatitis, especially in the early stages of the disease, can be difficult and frustrating for both doctors and patients. The contemplated studies analyzed a series of tests in relation to the possibility of early diagnosis of chronic pancreatitis. Endoscopic ultrasound, along with endoscopic retrograde cholangiopancreatography and magnetic resonance cholangiopancreatography, were the most frequently cited tests compared to s-MRCP for this purpose.

According to Jens Brøndum Frøkjær, EUS is able to diagnose parenchymal and ductal changes mainly during the early stage of the disease.<sup>41</sup> It also has a higher sensitivity when compared to ERCP in the early identification of the disease.<sup>26</sup> However, the examination is highly dependent on the operator and some studies still consider the examination to be more important in relation to late CP findings.

ERCP allows visualization of the lateral branches of the pancreatic duct, which may be altered in the initial phase of CP-associated inflammation and remains the gold standard for CP staging.<sup>17,18,27</sup> However, it also has several disadvantages: it is an invasive method and presents a substantial risk of complications.<sup>27th</sup>

MRCP allows visualization of the pancreatic and biliary duct systems, enabling the characterization of ductal and pancreatic abnormalities for diagnosis, staging, and evaluation of CP complications.<sup>21, 22</sup> This test is indicated mainly in patients where there are no pathological changes seen on CT.<sup>41</sup> However, some studies suggest that it is less sensitive in detecting subtle



ductal abnormalities and early changes compared to other tests such as ERCP and others, which have diagnostic capacity similar to ERCP.<sup>25, 26</sup>

The studies analyzed are at odds with each other in several aspects in relation to the ideal test for the early detection of CP. Therefore, a more accurate tool to detect pancreatic changes earlier is even more essential for medical practice.

## 5.8 EFFICIENCY OF S-CPRM

Based on this review, secretin-enhanced magnetic resonance cholangiopancreatography is an efficient method for early diagnosis of chronic pancreatitis, a disease that is usually diagnosed late. However, in the current management of chronic pancreatitis, proposed by Frøkjær, Jens Brøndum et al., its application is reserved for cases in which there is still clinical suspicion of chronic pancreatitis even with normal pancreatic images made by computed tomography and conventional magnetic resonance imaging.<sup>41th</sup>

One question that arose in the face of these results was why s-MRCP is not used as a standard, since, in addition to being a minimally invasive method, it would play an important role in this diagnosis. Accessibility to specialized services for performing this test is low around the world<sup>41</sup>, so the number of professionals specialized in its interpretation is also low, and the analysis of the results can hardly be done by generalists.<sup>30</sup> In addition, it is still necessary to develop a staging system based on magnetic resonance imaging findings that combines the alterations found before and after stimulation with intravenous secretin in order to make the diagnosis accurate and qualified.<sup>44th</sup>

## 6 CONCLUSION

In summary, s-MRCP is a minimally invasive test, which allows the analysis of pancreatic structure and function, which can be beneficial for the diagnosis of several diseases, in addition, it presents diagnostic results comparable and even superior to those of other methods, thus becoming an efficient test for the early diagnosis of chronic pancreatitis.

The difficult access to specialized professionals, in addition to the high costs of equipment and secretin, and the lack of a standardized staging system, are challenges for the practical implementation of this test. However, considering that the early diagnosis of chronic pancreatitis can contain the evolution of the disease, the investment in this test is valid and necessary. The development of exocrine and endocrine pancreatic insufficiency generates expenses with hormone replacement and with the treatment of hospitalizations and interventions caused by complications



of chronic pancreatitis. In addition, the availability of MRI machines is widespread, even if they are expensive. Therefore, in the long term, in addition to diagnosing the disease early and, consequently, delaying its negative outcomes, including mortality, performing s-MRCP in the early stages of chronic pancreatitis could reduce the high costs of treating these complications.



## REFERENCES

Leung PS. Physiology of the Pancreas. *Advances in Experimental Medicine and Biology*. 2010;13–27.

Uchôa C, Mescher AL. *Junqueira's Basic Histology*. 2013.

DiGregorio N, Sharma S. Physiology, Secretin [Internet]. PubMed. Treasure Island (FL): StatPearls Publishing; 2020. Disponível em: <https://www.ncbi.nlm.nih.gov/books/NBK537116/>

Beyer G, Habtezion A, Werner J, Lerch MM, Mayerle J. Chronic pancreatitis. *The Lancet* [Internet]. 2020 Aug 1 [cited 2023 Oct 20];396(10249):499–512. Available from: <https://pubmed.ncbi.nlm.nih.gov/32798493/>

Majumder S, Chari ST. Chronic pancreatitis. *The Lancet* [Internet]. 2016 May 1 [cited 2023 Oct 20];387(10031):1957–66. Available from: <https://pubmed.ncbi.nlm.nih.gov/26948434/>

Friedman M. SLEISENGER AND FORDTRAN'S GASTROINTESTINAL AND LIVER DISEASE- 2 VOLUME SET : pathophysiology,... diagnosis, management. S.L.: Elsevier - Health Science; 2020.

Xiao AY, et al. Global incidence and mortality of pancreatic diseases: a systematic review, meta-analysis, and meta-regression of population-based cohort studies. *Lancet Gastroenterol Hepatol*. 2016;1(1):45–55

PETROV, M. S.; YADAV, D. Global epidemiology and holistic prevention of pancreatitis. v. 16, n. 3, p. 175–184, 1 mar. 2019

Machicado JD, Yadav D. Epidemiology of Recurrent Acute and Chronic Pancreatitis: Similarities and Differences. *Digestive Diseases and Sciences* [Internet]. 2017 Mar 9 [cited 2023 Oct 15];62(7):1683–91. Available from: <https://www.ncbi.nlm.nih.gov/pmc/articles/PMC5478431/>

Kichler AJ, Jang S. Chronic Pancreatitis: Epidemiology, Diagnosis, and Management Updates. *Drugs* [Internet]. 2020 Jul 9 [cited 2023 Oct 15];80(12):1155–68. Available from: <https://pubmed.ncbi.nlm.nih.gov/32647920/>

Whitcomb DC. Pancreatitis: TIGAR-O Version 2 Risk/Etiology Checklist With Topic Reviews, Updates, and Use Primers. *Clinical and Translational Gastroenterology*. 2019 Jun;10(6):e00027.

Brock C. Pathophysiology of chronic pancreatitis. *World Journal of Gastroenterology*. 2013;19(42):7231

Singh VK, Yadav D, Garg PK. Diagnosis and Management of Chronic Pancreatitis. *JAMA*. 2019 Dec 24;322(24):2422.

Nista EC, De Lucia SS, Manilla V, Schepis T, Pellegrino A, Ojetti V, et al. Autoimmune Pancreatitis: From Pathogenesis to Treatment. *International Journal of Molecular Sciences*. 2022 Oct 21;23(20):12667.



Kleeff J, Whitcomb DC, Shimosegawa T, Esposito I, Lerch MM, Gress T, et al. Chronic pancreatitis. *Nature Reviews Disease Primers* [Internet]. 2017 Sep 7;3(1). Disponível em: <https://www.nature.com/articles/nrdp201760>

Gardner TB, Adler DG, Forsmark CE, Sauer BG, Taylor JR, Whitcomb DC. ACG Clinical Guideline: Chronic Pancreatitis. *American Journal of Gastroenterology* [Internet]. 2020 Feb 14; Publish Ahead of Print. Disponível em: <https://journals.lww.com/ajg/pages/articleviewer.aspx?year=9000&issue=00000&article=99424&type=Abstract>

Swensson J, Zaheer A, Conwell D, Sandrasegaran K, Manfredi R, Tirkes T. Secretin-Enhanced MRCP: How and Why—*AJR* Expert Panel Narrative Review. *American Journal of Roentgenology* [Internet]. 2021 May;216(5):1139–49. Available from: <https://www.ncbi.nlm.nih.gov/pmc/articles/PMC8068672/>

Manfredi R, Pozzi Mucelli R. Secretin-enhanced MR Imaging of the Pancreas. *Radiology*. 2016 Apr;279(1):29–43.

Chouhan MD, Firmin L, Read S, Amin Z, Taylor SA. Quantitative pancreatic MRI: a pathology-based review. *The British Journal of Radiology* [Internet]. 2019 Jul;92(1099):20180941. Available from: <https://www.ncbi.nlm.nih.gov/pmc/articles/PMC6636277/>

Hellerhoff KJ, Helmberger H, Rösch T, Settles MR, Link TM, Rummeny EJ. Dynamic MR Pancreatography After Secretin Administration: Image Quality and Diagnostic Accuracy. *American Journal of Roentgenology*. 2002 Jul;179(1):121–9.

Hansen TM. Morphological and functional evaluation of chronic pancreatitis with magnetic resonance imaging. *World Journal of Gastroenterology*. 2013;19(42):7241.

Choueiri NE, Balci NC, Alkaade S, Burton FR. Advanced Imaging of Chronic Pancreatitis. *Current Gastroenterology Reports*. 2010 Mar 16;12(2):114–20.

Tirkes T, Dasyam AK, Shah ZK, Fogel EL. Role of standardized reporting and novel imaging markers in chronic pancreatitis. *Current Opinion in Gastroenterology*. 2021 Jun 18;37(5):512–9.

Chamokova B, Bastati N, Poetter-Lang S, Bican Y, Hodge JC, Schindl M, et al. The clinical value of secretin-enhanced MRCP in the functional and morphological assessment of pancreatic diseases. *The British Journal of Radiology*. 2018 Feb 5;20170677.

Czakó L. Diagnosis of early-stage chronic pancreatitis by secretin-enhanced magnetic resonance cholangiopancreatography. *Journal of Gastroenterology* [Internet]. 2007 Jan 1 [cited 2023 Oct 16];42 Suppl 17:113–7. Available from: <https://pubmed.ncbi.nlm.nih.gov/17238039/>

Jayaraj M, Makar R, Ohning G. Evaluation and Management of Suspected Early Chronic Pancreatitis (ECP). *Current Gastroenterology Reports*. 2020 Jun 26;22(8).

Sugiyama M, Hiroki Haradome, Yutaka Atomi. Magnetic resonance imaging for diagnosing chronic pancreatitis. *Journal of Gastroenterology*. 2007 Jan 19;42(S17):108–12.



Griffin N, Charles-Edwards G, Grant LA. Magnetic resonance cholangiopancreatography: the ABC of MRCP. *Insights into Imaging* [Internet]. 2011 Sep 28;3(1):11–21. Available from: <https://www.ncbi.nlm.nih.gov/pmc/articles/PMC3292642/>

Gupta P, Kamat R, Rana S. Imaging in chronic pancreatitis: State of the art review. *Indian Journal of Radiology and Imaging*. 2019;29(2):201.

Zuccaro P, Kathryn Repas TS, Diamond R, Lopez R, Wu B, Conwell DL. Magnetic Resonance Cholangiopancreatography Reports in the Evaluation of Chronic Pancreatitis: A Need for Quality Improvement. *Pancreatology* [Internet]. 2009 Jan 1;9(6):764–9. Available from: <https://www.sciencedirect.com/science/article/abs/pii/S1424390309801142>

Balci NC, Smith A, Momtahn AJ, Alkaade S, Fattahi R, Tariq S, et al. MRI and S-MRCP findings in patients with suspected chronic pancreatitis: Correlation with endoscopic pancreatic function testing (ePFT). *Journal of Magnetic Resonance Imaging*. 2010 Mar;31(3):601–6.

Nichols MT, Russ PD, Chen YK. Pancreatic Imaging. *Pancreas*. 2006 Oct;33(3):211–20.

Sanyal R, Stevens T, Novak E, Veniero JC. Secretin-Enhanced MRCP: Review of Technique and Application With Proposal for Quantification of Exocrine Function. *American Journal of Roentgenology*. 2012 Jan;198(1):124–32.

Kwon CI, Cho JH, Choi SH, Ko KH, Tirkes T, Gromski MA, et al. Recent advances in the diagnosis and management of chronic pancreatitis. *The Korean Journal of Internal Medicine*. 2019 Mar 1;34(2):242–60.

Bian Y. Quantification of pancreatic exocrine function of chronic pancreatitis with secretin-enhanced MRCP. *World Journal of Gastroenterology*. 2013;19(41):7177.

Gillams AR, Lees WR. Quantitative secretin MRCP (MRCPQ): results in 215 patients with known or suspected pancreatic pathology. *European Radiology*. 2007 Jul 10;17(11):2984–90.

Schlaudraff E, Wagner HJ, Klose KJ, Heverhagen JT. Prospective evaluation of the diagnostic accuracy of secretin-enhanced magnetic resonance cholangiopancreatography in suspected chronic pancreatitis. *Magnetic Resonance Imaging*. 2008 Dec;26(10):1367–73.

Balci NC, Alkaade S, Magas L, Momtahn AJ, Burton FR. Suspected chronic pancreatitis with normal MRCP: Findings on MRI in correlation with secretin MRCP. *Journal of Magnetic Resonance Imaging*. 2007;27(1):125–31.

Bali MA, Sztantics A, Metens T, Arvanitakis M, Delhaye M, Devière J, et al. Quantification of pancreatic exocrine function with secretin-enhanced magnetic resonance cholangiopancreatography: normal values and short-term effects of pancreatic duct drainage procedures in chronic pancreatitis. Initial results. *European Radiology* [Internet]. 2005 Oct 1 [cited 2023 Oct 16];15(10):2110–21. Disponível em: <https://pubmed.ncbi.nlm.nih.gov/15991016/>

Souza D, Alessandrino F, Ketwaroo GA, Sawhney M, Morteale KJ. Accuracy of a novel noninvasive secretin-enhanced MRCP severity index scoring system for diagnosis of chronic pancreatitis: correlation with EUS-based Rosemont criteria. *La radiologia medica*. 2020 Apr 7;125(9):816–26.



Frøkjær JB, Akisik F, Farooq A, Akpınar B, Dasyam A, Drewes AM, et al. Guidelines for the Diagnostic Cross Sectional Imaging and Severity Scoring of Chronic Pancreatitis. *Pancreatology*. 2018 Oct;18(7):764–73.

Dasyam AK, Shah ZK, Temel Tirkes, Navya Dasyam, Borhani AA. Cross-sectional imaging-based severity scoring of chronic pancreatitis: why it is necessary and how it can be done. *Abdominal Radiology* [Internet]. 2019 Sep 11 [cited 2023 Oct 16];45(5):1447–57. Disponível em: <https://www.ncbi.nlm.nih.gov/pmc/articles/PMC8001739/>

Temel Tirkes, Fogel EL, Sherman S, Lin C, Swensson J, Fatih Akisik, et al. Detection of exocrine dysfunction by MRI in patients with early chronic pancreatitis. *Abdominal Radiology* [Internet]. 2016 Sep 23 [cited 2023 Oct 16];42(2):544–51. Disponível em: <https://www.ncbi.nlm.nih.gov/pmc/articles/PMC5542580/>

Conwell DL, Lee LS, Yadav D, Longnecker DS, Miller FH, Morteale KJ, et al. American Pancreatic Association Practice Guidelines in Chronic Pancreatitis. *Pancreas*. 2014 Nov;43(8):1143–62.

Boraschi P, Donati F, Cervelli R, Pacciardi F. Secretin-stimulated MR cholangiopancreatography: spectrum of findings in pancreatic diseases. *Insights into Imaging*. 2016 Sep 15;7(6):819–29.

Maciel M, Cabral L, Schindler H, Guilherme F, Abath C, Recife O. Comentários | Comments. *Rev Saúde Pública* [Internet]. 2006;40(3):521–8. Available from: <https://www.scielo.br/j/rsp/a/FDPNXd377mTwFyhm75t75vJ/?format=pdf&lang=pt>

Hochman B, Nahas FX, Oliveira Filho RS de, Ferreira LM. Desenhos de pesquisa. *Acta Cirúrgica Brasileira* [Internet]. 2005;20:2–9. Available from: <https://www.scielo.br/j/acb/a/bHwp75Q7GYmj5CRdqsXtqbj/?lang=pt>