



## Benefits of gastric bypass in the treatment of obesity: An overview

### Benefícios do by-pass gástrico no tratamento da obesidade: Uma *overview*

DOI: 10.56238/isevjhv3n1-035

Receipt of originals: 02/14/2024

Publication acceptance: 03/06/2024

**Hugo Moreschi<sup>1</sup>, Igor Moreschi<sup>2</sup>, Gabriela Ricalde Chioveti<sup>3</sup>, Fernanda Cristine Frigheto<sup>4</sup>,  
Jéssica Mérley Locatelli<sup>5</sup>, Enia Vitória Valentin<sup>6</sup>, Carolina Soletti<sup>7</sup>, Ian Richard Lucena  
Andriolo<sup>8</sup>, Rodrigo Daniel Zanoni<sup>9</sup>, Lohana Vidaurre Salvatierra<sup>10</sup>.**

#### ABSTRACT

**Introduction:** Obesity is a health condition that has become increasingly common worldwide and is associated with several comorbidities. Treatment of obesity may involve lifestyle changes, medication, or bariatric surgery. Gastric bypass is one of the most widely used techniques in the surgical treatment of obesity and has been shown to be effective in terms of weight loss and improvement of comorbidities. **Methodology:** A literature review was conducted in the PubMed database, searching for articles published between 2010 and 2022, using the keywords "gastric bypass", "obesity", "comorbidities" and "effects". **Results and Discussion:** The evaluated studies

---

<sup>1</sup> Author

ORCID:0000-0001-7105-491-X

Medical student at Faculdade Ceres São José do Rio Preto – SP.

E-mail: hugomoreschi10@gmail.com

<sup>2</sup> ORCID: 0000-0002-3096-5749

Medical student at Faculdade Ceres São José do Rio Preto – SP.

E-mail: igormoreschi10@gmail.com

<sup>3</sup> ORCID: 0000-0003-1870-4375

Medical student at the University for the Development of the State of the Pantanal (UNIDERP), Campo Grande - MS

E-mail: gabrielachioveti@gmail.com

<sup>4</sup> ORCID: 0000-0002-3474-3270

Medical student at the University for the Development of the State of the Pantanal (UNIDERP), Campo Grande - MS

E-mail: fernandafriheto@gmail.com

<sup>5</sup> Orcid: 0009-0003-7811-2942

Medical student at Universidade Brasil (UB), Fernandópolis – SP

E-mail: jessicalocatelli@hotmail.com

<sup>6</sup> ORCID: 0009-0006-3587-149X

Medical student at Universidade Brasil (UB), Fernandópolis – SP.

E-mail: epvalentin@gmail.com

<sup>7</sup> ORCID: 0000-0003-0296-608X

Medical student at the University for the Development of the State of the Pantanal (UNIDERP), Campo Grande - MS

E-mail: soletticarolina@gmail.com

<sup>8</sup> ORCID: 0009-0007-8757-8268

Medical student at the University of Vale do Itajaí, Itajaí – SC

E-mail: ianrlucena@hotmail.com

<sup>9</sup> Co-Counsellor

ORCID: 0000-0001-7641-2851

Doctor from the Pontifical Catholic University of Campinas – SP

Master's Degree in Public Health from Faculdade São Leopoldo Mandic Campinas (2018 - 2022)

E-mail: drzanoni@gmail.com

<sup>10</sup> Counselor

ORCID: 0000-0003-3155-2142

General Surgeon at the Hospital do Servidor Público Municipal de São Paulo – SP.

E-mail: loohana36@gmail.com



demonstrated that gastric bypass is an effective technique in the treatment of obesity, with significant weight loss and improvement in comorbidities such as diabetes, hypertension, dyslipidemia and sleep apnea. In addition, gastric bypass has been shown to have beneficial effects on quality of life and mortality reduction. Although gastric bypass is an effective technique, its indication should be carefully evaluated, taking into account the severity of obesity and the presence of comorbidities. It is important that patients are adequately informed about the risks and benefits of the technique, and that they are followed up by a multidisciplinary team after surgery. Conclusion: Gastric bypass is a safe and effective technique in the treatment of obesity, with a positive impact on weight loss, improvement of comorbidities and quality of life of patients. However, it is important that the indication of the technique is judicious and that patients are followed up by a multidisciplinary team after surgery.

**Keywords:** Gastric bypass, Obesity, Comorbidities, Effects.

## INTRODUCTION

Acute mesenteric ischemia consists of a sudden interruption of the blood supply, it is known that this vessel is the main responsible for the irrigation of the small intestine, thus causing a rapidly progressing abdominal emergency. This obstruction to blood flow can trigger complications, such as necrosis or intestinal infarction, in addition to having a high risk of death for the patient. To better understand the pathological mechanisms, a brief review of the anatomical structures that make up the mesenteric circulation is necessary. The main vessels are the Celiac Trunk, the Superior and Inferior Mesenteric Arteries (SMA), in addition to the collateral vessels that originate in this vascular system and ensure adequate perfusion of the entire small intestine. The celiac trunk (CT) plays a fundamental role in the irrigation of the gastrointestinal tract (GIT) including the esophagus and duodenum, while the superior and inferior mesenteric lead to the rest of the distal segments. While drainage occurs through the superior and inferior mesenteric veins, which join the splenic vein to form the portal vein. Occlusion may result from occlusive or non-occlusive means, abruptly interrupting the blood flow of any of these vascular structures. The existing pathophysiological mechanisms are arterial embolism or thrombosis, venous thrombosis and non-occlusive origin (BARROS, 2018); (BALA, 2022).

In general, the most common etiology of this disease is an embolic occlusion of the superior mesenteric (SMA), in these cases, about 1/3 of the patients have an embolic event in their previous history and it can also occur associated with other arterial embolisms, and it is common for the plunger to result from an atherosclerotic disease of the superior arteries, such as the aorta, but it can also have its origin in the dysfunction of other structures, such as the atrium or left ventricle. In general, the preferential site of emboli are the regions of vascular narrowing,



usually located 3-10 cm distal to the origin of the MAS, thus sparing the proximal jejunum and colon. More than 20% of cases are associated with concomitant emboli in other arterial beds, such as the spleen and kidney (BALA, 2022). As for arterial thrombosis, there is usually an association with coronary artery disease, a pathology that affects 20% of the elderly population. The main mechanism of flow obstruction is arterial stenosis, which progressively reduces the arterial lumen, and ischemia is clinically recognized when it affects about 70% of the vessel diameter. In these cases, an acute clinic can be performed if the plaque ruptures abruptly or due to severe dehydration. Venous thrombosis is the least common cause of this pathology, the reduction of irrigation results from the reduction of venous return, there is an edema of the visceral wall, so that the perfusion is compromised and leads to a reduction of flow in multiple segments involved. Thrombotic phenomena result from systemic disorders, such as prothrombotic states, direct injury to the vessel wall, and venous stasis, known as Virchow's Triad. However, up to 49% of cases may have idiopathic etiology. Finally, there are also other causes, such as non-occlusive arterial and venous thrombosis, which results from vasoconstriction of the splanchnic arteries due to stenosis of some adjacent structure. Other common causes are hypovolemia, severe heart failure, sepsis, prolonged use of vasoconstrictors, extensive surgeries, or hypotension generated by prolonged dialysis (BARROS, 2018); (MARTINI, 2022).

Currently, Acute Mesenteric Ischemia has an incidence of 10 per 100 thousand people per year, in addition, it has an exponential increase with aging, a fact that arouses concern, since in the current Brazilian scenario there is an inversion of the age pyramid with growth of the senile population. The main problem is the high mortality resulting from this pathology, which is recorded in about 50% of cases of the disease (ANIKKA, 2022). The main problem is that it is a silent disease, depending on its etiology, so that the clinical manifestation may become evident only in advanced cases and its presentation varies, depending on the cause. In acute mesenteric ischemia (IMA), the symptoms usually appear abruptly and in a phase that requires early surgical intervention for the affected intestinal region, resulting in the high rate of morbidity and mortality. And due to its low prevalence and nonspecific clinical picture, this pathology is difficult to diagnose, which is often late and results in a delay in the implementation of treatment, a fact that leads to an unfavorable prognosis (BARROS, 2018); (BALA, 2022).

Therefore, in order to ensure a better prognosis for the patient, as well as an appropriate approach to his pathological condition, the objective of this study is to review the main clinical



characteristics of IMA, as well as its diagnostic criteria and the recommended intervention to be implemented.

## **METHODOLOGY**

This is a narrative review of the literature, which was done by determining the following descriptors by the MESH (Medical Subject Headings) platform and the following descriptors can be obtained, which were joined by the Boolean operator AND: "Mesenteric Ischemia", "Diagnosis", "Therapeutics", "Surgical Procedures, Operative". The search was carried out on the PUBMED targeting platform, which indexes the MEDLINE database (Online System for Search and Analysis of Medical Literature). First, 196 studies were found and, with the full text available in full, 68 articles were obtained. After this step, the inclusion criterion was added to original articles and within the years 2010 to 2023, with 20 articles being selected.

After applying the filters, the articles went through a selection process carried out independently by two authors, blindly. First, the title and abstract of the articles were analyzed, in this process 5 articles were excluded because they did not meet the main objective of the article. Following this, the 15 selected articles were thoroughly read, and 12 were selected to compose this review.

## **DISCUSSION AND CONCLUSION**

Nowadays, we are experiencing a pandemic of obesity, a disease that brings with it numerous systemic consequences, such as type 2 diabetes mellitus, dyslipidemia, hypertension, hepatic steatosis, cardiovascular diseases, as well as heart attacks, among other conditions, which makes it a worrying public health problem. In this sense, recognizing obesity, understanding its multifactorial causes, and in this aspect, including the diet based on processed and ultra-processed foods, as well as the lack of physical exercise, is essential. However, multifactorial clinical treatment often fails, and surgical treatment is necessary. (MAYORAL et al., 2020)

Bariatric surgery is divided into restrictive, disabsorptive and mixed, and is most often performed by two techniques. The first, sleeve gastrectomy, is a restrictive technique, known as sleeve, and the second, gastric bypass, is a mixed technique, which in addition to promoting restriction, also promotes disabsorption. Among the bypass approaches, the most commonly performed is gastroplasty with a Roux-en-Y bowel diversion. The sleeve technique accelerates gastric emptying and intestinal transit and also increases bile acid secretion. Gastric bypass, on



the other hand, accelerates gastric emptying, decreases gastric acid secretion, and increases serum bile acid levels. (STEENACKERS et al., 2021)

These bariatric surgeries are called metabolic. In the case of bypass, this designation becomes evident because it reorganizes the metabolism between the proximal and distal parts of the intestine, since in contemporary dietary conditions, which are the supply of foods with a high glycemic index, there is disorganization. This reorganization is necessary, because it is known that the proximal part of the intestine is directly linked to gluconeogenesis, which in view of the high glycemic index of current diets, becomes unnecessary, and therefore, the proximal intestine has its function suppressed. This reduced function reflects directly on the distal intestine, which is responsible for physiological hypoglycemia and hypolipidemia, as well as promoting satiety and blockage of gastric emptying. This response given by the distal intestine is the reduction of its function, which consequently generates hyperglycemia, hyperlipidemia, increased hunger and accelerated gastric emptying, favoring and worsening obesity even more. (SANTORO et al., 2020)

In addition, bariatric surgeries also emerge as more efficient therapeutic alternatives to drug treatments and lifestyle habits for Type 2 Diabetes Mellitus, one of the most frequent complications of obesity, so that through surgeries, one can even talk about a cure for DM2. In this aspect, Gastric Bypass stands out, since through this technique, in addition to the already documented increases in GLP-1 levels, as well as insulin, there is an improvement in insulin sensitization, which is not reported in another technique. (GENTILESCHI et al., 2021)

## INDICATIONS

In Brazil, bariatric surgery is performed by the Unified Health System, but must follow the following indications determined by Ordinance No. 492 of August 31, 2007:

- a. Morbidly obese patients with BMI (body mass index) equal to or greater than 40 Kg/m<sup>2</sup>, without comorbidities and who did not respond to conservative treatment (diet, psychotherapy, physical activity, etc.), performed for at least two years and under the direct or indirect guidance of a hospital team accredited/qualified as a High Complexity Care Unit for Patients with Obesity.
- b. Morbidly obese patients with a BMI equal to or greater than 40 Kg/m<sup>2</sup> with life-threatening comorbidities.
- c. Patients with BMI between 35 and 39.9 kg/m<sup>2</sup> with chronic diseases triggered or aggravated by obesity.



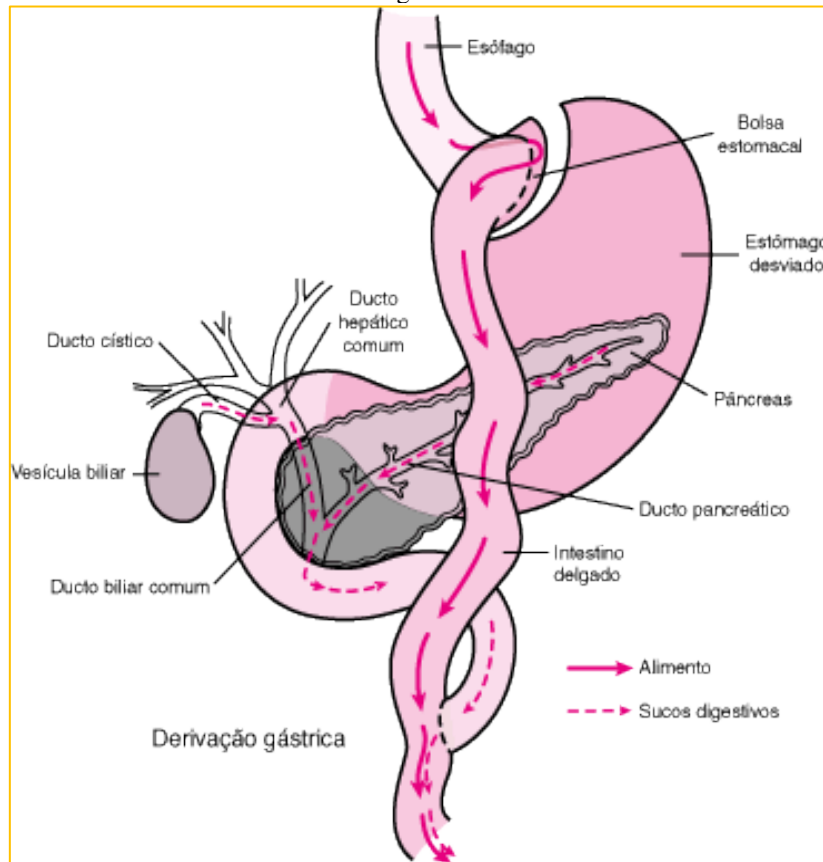
However, the following criteria must be observed:

- a. exclude cases of obesity due to endocrine disease (e.g., Cushing's syndrome due to adrenal hyperplasia);
- b. respect the limits of the age group of 18 to 65 years, and surgical treatment should not be performed before the growth epiphyses are consolidated in the young;
- c. the patient has the intellectual capacity to understand all aspects of the treatment, as well as constant family support;
- d. the patient and the relatives who support him/her to commit to postoperative follow-up, which should be maintained indefinitely;
- e. the patient does not have alcoholism or chemical dependence on other drugs, severe psychotic disorder or recent history of suicide attempt ("ORDINANCE No. 492", [n.d.]

## **BYPASS TECHNIQUES**

In the Roux-en-Y technique, the proximal stomach region is separated from the rest of the organ, followed by the connection of the new stomach pouch with the proximal jejunum. First, there is a horizontal section of the stomach, through staples, so that there is no removal of any organ. This stapling creates a small stomach pouch of less than 30 ml in volume. Subsequently, the Roux-en-Y feeding loop is made, which consists of anastomosis of the gastric pouch with the jejunum, and this is a step of the technique. The other step is the connection of the bypassed stomach to the distal portions of the intestine. The distal portions will receive bile acids and pancreatic juice, which will meet the food coming from the stomach pouch and passing through the jejunum. Thus, the "Roux's Y" technique is considered mixed, as it performs the restriction by creating the stomach pouch and promotes its divorability by reducing the intestinal area with the creation of the Roux loop. (MERCK ONLINE HANDBOOK, 2021; RODRIGUES et al, 2020). Figure 1 schematizes the Roux-en-Y technique.

Figure 1:



Source: MANUAL MERCK ON-LINE, 2021.

## COMPLICATIONS

Like any surgical procedure, Roux-en-Y bypass surgery can also cause complications, either in the short or long term, ranging from hemorrhages to even involving medical malpractice, when the Roux loop is incorrectly constructed and even reaching the formation of a gastrogastric fistula. (ACQUAFRESCA et al., 2015; PALERMO et al., 2015)

### SHORT-TERM COMPLICATIONS

(ACQUAFRESCA et al., 2015)

#### **Anastomotic or stapling line dehiscence**

It consists of the leakage of substances from the gastrointestinal tract, as a result of impaired healing.

#### **Hemorrhagia**

It is the bleeding that occurs at the sites where the staple took place, as well as at the edges of tissue sections.



### **Intestinal obstruction**

When a defect in the abdominal cavity allows the passage of some part of the intestine, the so-called internal hernia is formed, which leads to intestinal obstruction as a complication.

#### **LONG-TERM COMPLICATIONS:**

(PALERMO et al., 2015)

### **Anastomotic stenosis**

A stenosed anastomosis can be caused by anomalous scarring, as well as technical errors that can cause tension disproportions and when there is inaptitude of the surgeon, there can even be errors in the construction of the anastomosis.

### **Marginal ulceration**

Near the anastomosis between the stomach pouch and the jejunum, peptic ulcers may appear and this complication is called marginal ulcer.

### **Gastrogastric fistula**

This complication consists of the access between the stomach pouch and the stomach that has been excluded and is caused by ruptures in the staple lines and even improper technique when constructing the stomach pouch.

### **FINAL THOUGHTS**

In conclusion, gastric bypass is a surgical technique that has been shown to be an effective and safe option in the treatment of obesity. In addition to significant weight loss, the surgery also promotes improvement in several comorbidities associated with obesity, such as diabetes, hypertension and dyslipidemia. Other benefits include improved quality of life and reduced mortality. However, the indication of the technique should be carefully evaluated and monitored by a multidisciplinary team, as the surgery involves risks and may present complications. It is important that patients are adequately informed about the risks and benefits of the technique and that they follow medical advice after surgery to ensure the success of treatment.



## REFERENCES

- MAYORAL et al. Obesity subtypes, related biomarkers & heterogeneity. *Indian Journal of Medical Research*, v. 151, n. 1, p. 11, 2020.
- STEENACKERS et al. Adaptations in gastrointestinal physiology after sleeve gastrectomy and Roux-en-Y gastric bypass. *The Lancet Gastroenterology & Hepatology*, v. 6, n. 3, p. 225–237, mar. 2021.
- SANTORO, S. et al. DOES EVOLUTIONARY BIOLOGY HELP THE UNDERSTANDING OF METABOLIC SURGERY? A FOCUSED REVIEW. *ABCD. Arquivos Brasileiros de Cirurgia Digestiva (São Paulo)*, v. 33, n. 1, 2020.
- GENTILESCHI, P. ; BIANCIARDI, E. ; BENA VOLI, D.; CAMPANELLI, M. Metabolic surgery for type II diabetes: an update. *Acta Diabetologica*, v. 58, n. 9, p. 1153–1159, 18 maio 2021.
- PORTARIA Nº 492. Disponível em: <<http://www1.saude.rs.gov.br/dados/1190226903775PT-492.html>>.
- MANUAL MERCK ON-LINE. Disponível em: <<https://www.msdmanuals.com/pt-br/profissional/dist%C3%BArbios-nutricionais/obesidade-e-s%C3%ADndrome-metab%C3%B3lica/cirurgia-bari%C3%A1trica>>
- RODRIGUES et al. Cirurgia bariátrica por bypass gástrico em Y de Roux: abordagem da técnica e de possíveis complicações tardias no pós-operatório. *Revista Eletrônica Acervo Científico*, v. 16, p. e 4979, 26 dez. 2020.
- ACQUAFRESCA, P. et al. Early surgical complications after gastric by-pass: a literature review. *ABCD. Arquivos Brasileiros de Cirurgia Digestiva (São Paulo)*, v. 28, n. 1, p. 74–80, 2015.
- PALERMO, M. et al. Late surgical complications after gastric by-pass: a literature review. *Arquivos Brasileiros de Cirurgia Digestiva: ABCD = Brazilian Archives of Digestive Surgery*, v. 28, n. 2, p. 139–143, 2015.
- BUCHWALD H, Avidor Y, Braunwald E, et al. Bariatric surgery: a systematic review and meta-analysis. *JAMA*. 2004;292(14):1724-1737.
- SJÖSTRÖM L, Narbro K, Sjöström CD, et al. Effects of bariatric surgery on mortality in Swedish obese subjects. *N Engl J Med*. 2007;357(8):741-752.
- COLQUITT JL, Pickett K, Loveman E, Frampton GK. Surgery for weight loss in adults. *Cochrane Database Syst Rev*. 2014;(8):CD003641.