



Abdominal wall necrosis after incisional hernia repair in an obese diabetic patient

Necrose de parede abdominal pós correção de hérnias incisionais em paciente obesa e diabética

DOI: 10.56238/isevjhv3n2-005

Receipt of originals: 02/24/2024

Publication Acceptance: 03/14/2024

Helen Brambila Jorge Pareja¹, Eduardo Alves Canedo², Elisangela Maria Nicolete Rampazzio³, José Francisco Galindo Medina Filho⁴, Larissa Shepherds⁵, Dayane Valentim Borges⁶, Armando Carromeu Dias Pioch⁷, Victor Hugo Maioli⁸.

ABSTRACT

Tissue repair is a complex and multifactorial organic process, intrinsically related to the health condition of individuals. Systemic pathologies such as hypothyroidism, Diabetes Mellitus (DM) and advanced age have a direct and indirect impact on the chain of physiological processes that make up tissue proliferation and healing. In patients with these comorbidities, especially when associated, the tissue healing mechanism may be compromised and delay postoperative recovery. The objective of this article is to report a clinical case of an elderly patient affected by the comorbidities, who underwent surgery for numerous abdominal hernias and evolved unfavorably in the postoperative period, with extensive necrosis of the abdominal wall.

Keywords: Hernia, Hypothyroidism, Necrosis, Diabetes mellitus.

INTRODUCTION

Diabetes Mellitus (DM) is a disease characterized by a disorder in the metabolism of proteins, carbohydrates and fats, caused by the impaired synthesis or secretion of insulin by the beta cells of the pancreas and/or the inability of the tissues to use it. It is closely related to metabolic syndrome: increased waist circumference has been shown to be an important causal

¹ Physician, Digestive Surgeon

University of Oeste Paulista, Santa Casa de Misericórdia de Presidente Prudente

² Physician, General Surgery Resident

Hospital Regional de Presidente Prudente

³ High school, medical student

University of the West of São Paulo

⁴ High School, Medical Student

University of the West of São Paulo

⁵ High School, Medical Student

University of the West of São Paulo

⁶ High School, Medical Student

University of the West of São Paulo

⁷ High School, Medical Student

University of the West of São Paulo

⁸ High School, Medical Student

University of the West of São Paulo



factor of systemic inflammation, responsible for the insulin resistance usually observed in obese patients. This resistance process occurs due to the high levels of circulating fatty acids that stimulate the phosphorylation of serines in insulin receptor substrates (IRS) in their target tissues (liver and muscle), which decreases intracellular activation in the cascade mediated by the substance itself¹.

Continued high levels of serum glucose increase the activity of DAG and β 2PKC, substances responsible for the contractility of arterial wall smooth muscle and endothelial cell permeability, favoring the deposit of proteins in the basement membrane of capillaries, leading to one of the main complications of DM: diabetic microangiopathy¹⁰. By definition, capillaries are arterioles with a diameter of less than 100 μ m and the endothelial layer is capable of secreting protective substances (such as nitric oxide, prostacyclin, etc.) that are commonly dysregulated in current and long-term DM³. Diabetic microangiopathy, therefore, is the result of numerous factors impaired by hyperglycemia and usually appears after a long period of glycemic uncontrol, with decades of aggression to the microvessels, either due to poor medication adherence by the patient, poor social habits, or due to the severity of the disease itself².

Diabetic microangiopathy is usually observed in target organs of the disease, which includes: retina, renal tubule, Bowman's capsule, peripheral nerves, etc.². The appearance of necrosis of the abdominal wall in a patient with the disease, in the postoperative period of incisional hernia repairs, is a rare case that is rarely seen in the literature. Other causes of surgical wound necrosis include site infections, autoimmune diseases, use of medications, foreign bodies, and increased tissue pressure, among others⁴.

Obesity, commonly known as increased waist circumference, usually associated with the development of type II DM, is also an important risk factor for the appearance of incisional hernias. Incisional hernias refer to protrusions of abdominal contents that occur due to weakness of the wall after trauma or abdominal surgery, and can be called ventral hernias, occurring due to failure in the closure of the aponeurosis (layer of connective tissue that connects the muscles to each other)^{5,6}. 15% of these occur in the mid-abdominal line and the treatment includes an open or laparoscopic approach^{2,5,6}. Other risk factors for its occurrence include: smoking, DM, perioperative and postoperative infections, and inadequate surgical closure⁵.

This report showed that the complications of *Diabetes mellitus* can be more complex and go beyond what science expects and intends to elucidate the facts, aiming to help future professionals. These, in turn, should have full knowledge of their patients and their comorbidities so that they know the ideal management, even if they are unaware or rare about the situation



presented. This article aims to report the case of an obese patient with *diabetes mellitus* who presented necrosis of the abdominal wall after undergoing a surgical procedure to repair an incisional hernia, aiming to elucidate a rare complication and to help other health professionals who may have their patients submitted to the same pathology.

METHODOLOGY

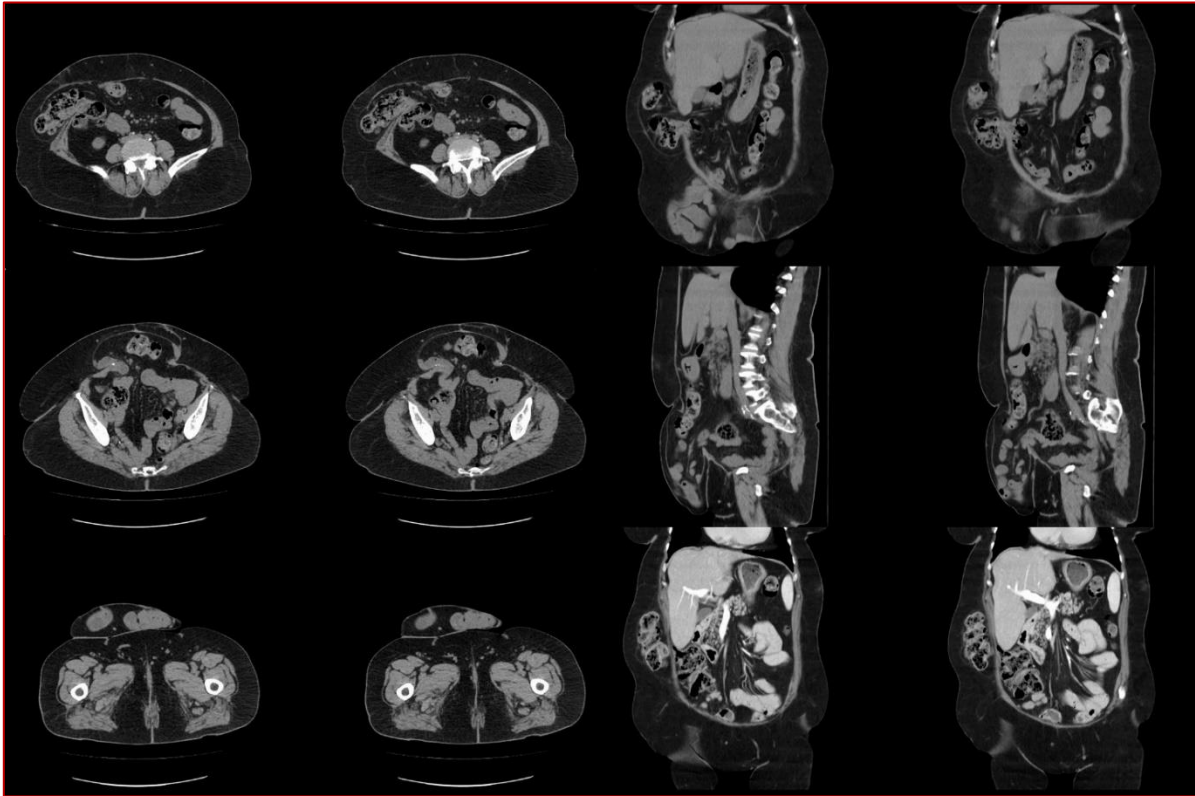
This is a case report type, in which information was collected through a review of medical records. At the same time, to support the ideas discussed in this article, a literature review was carried out in scientific databases such as PubMed and Scielo. The production of this scientific article followed the regulations proposed by the National Research Council (CONEP).

CASE REPORT

A 67-year-old female patient, white, married, with no schooling, Catholic, sought medical attention with a complaint of bulging and pain in the abdominal region due to a previous surgical scar since 2015, but in recent months she has presented significant worsening of pain, especially on exertion, which limits it during daily activities. The patient is obese, with an apron abdomen, and has a history of type II diabetes on Metformin and Glycazide, hypertension on losartan potassium, dyslipidemia on simvastatin and hypothyroidism on levothyroxine sodium.

She has undergone 3 previous surgeries (two surgeries for metachronous treatment due to colorectal cancer, in 2011 and 2013, and one intestinal transit reconstruction). Abdominal physical examination revealed the presence of bulging in a laparotomy surgical scar in the midline region, bulging in the right hypochondrium and left flank over the scar of the colostomy surgical incision, all with prominence in the valsalva maneuver, but hypogastro without manual reduction. A CT scan of the total abdomen was requested for surgical programming (Figure 1).

Figure 1 – CT scan sections of the abdomen

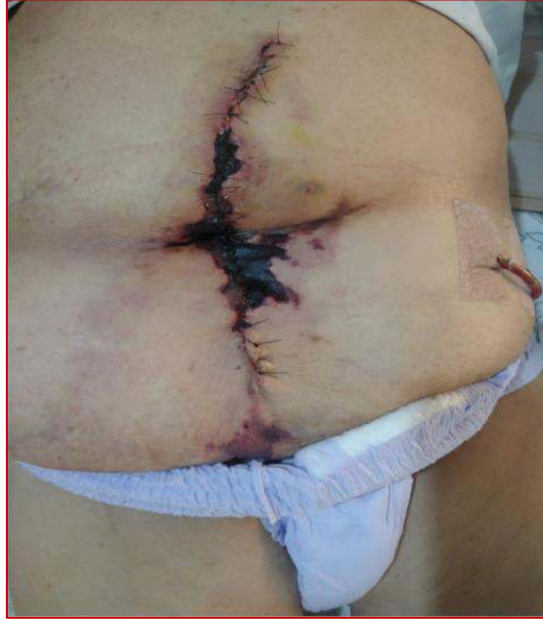

Source: the authors.

After a detailed study of the disease with complementary exams, the presence of 7 ventral hernias was found (see figure 1) and it was decided to use a double-sided mesh in the lower portion, where the axis was not able to be approached, and in the other primary approaches with the use of a mesh to avoid recurrence. The patient underwent a mixed surgical procedure of herniorrhaphy and hernioplasty to close the injured aponeuroses, reconstructing the abdominal wall.

For the herniorrhaphy procedure, a 30x30 centimeter (cm) polypropylene mesh was used, using the primary closure of the technique, with the criterion of choice for hernias of smaller diameter in a total of 6 hernia rings; Hernioplasty was chosen at the discretion of the larger hernias and, for this, a 15x20 cm oval PCDG1 double-sided mesh was used. The mixed technique was necessary due to the number of lesions presented by the patient's abdominal wall and its fragility. There were no complications during surgery. The patient is fed the same day and discharged from the hospital the next day.

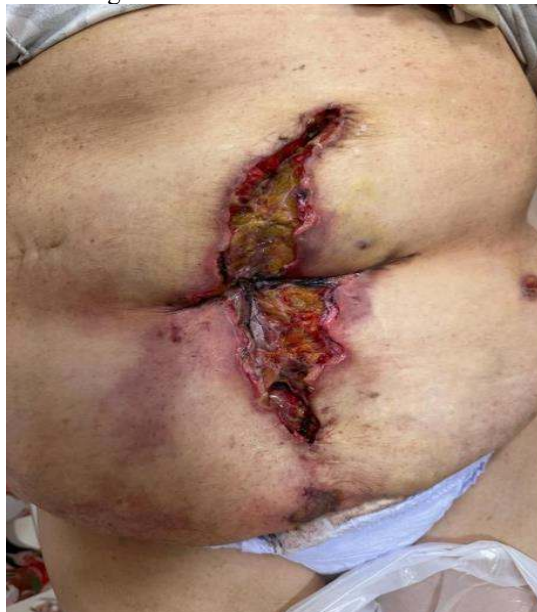Figure 2 – Signs of necrosis in an abdominal surgical wound



Source: the authors

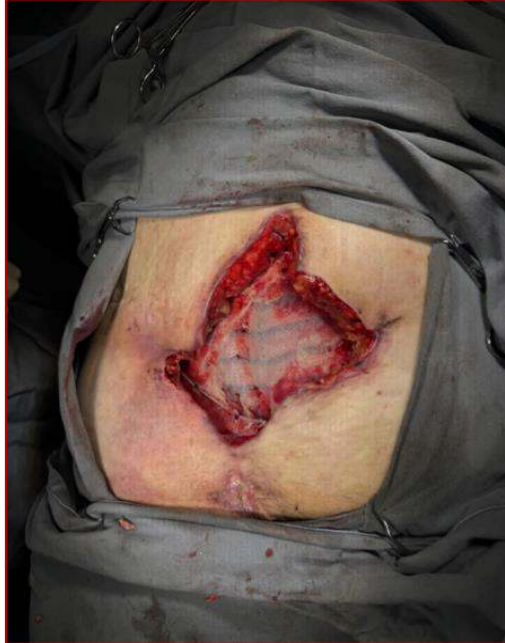After 20 days of surgery, the patient developed signs of necrosis of the surgical wound in the central median region, which remained dry with phlogistic signs and no exit of purulent secretion (*Figure 3*). The patient reported that he had no systemic symptoms, such as fever, nausea or vomiting, as well as no pain. Tissue ischemia was then confirmed, and he was referred to a plastic surgeon for evaluation, followed by debridement of the dead tissue. After 7 days, the patient presented a new necrosis with a foul odor, but without systemic signs, and she was hospitalized and underwent extensive debridement in the operating room (*Figures 3 and 4*).

Figure 3 – Post-debridement wound



Source: the authors.

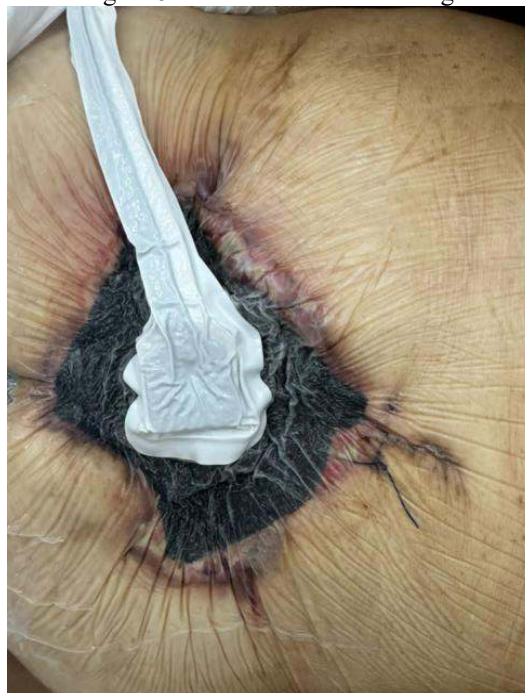Figure 4 – post-debridement surgical wound



Source: the authors.

After 2 days of the second surgery, the patient developed a new necrosis of the wall at the edge of the wound, and a new debridement was performed. The established hypothesis is that wall necrosis evolves after tissue ischemia resulting from significant oxidative stress aggravated by the patient's comorbidities. With tissue debridement, the final approach was to opt for closure by second intention, using a vacuum dressing to assist in the process (Figure 5).

Figure 5 – Use of vacuum dressing.



Source: the authors.



DISCUSSION

Incisional hernias refer to a group of acquired ventral hernias that correspond to defects in the adequate closure of the abdominal wall, more specifically the aponeurosis, with occasional protrusions of abdominal contents or with all the hernia components of the defect, sac and contents, and may affect regions of surgical wound, as in the case reported, or that have undergone mechanical trauma^{5, 6}.

When they require surgical correction, incisional hernias can benefit from two techniques: open correction or laparoscopic correction. Van Den Dop's study states that both techniques have advantages and disadvantages, but laparoscopic correction benefits from shorter hospital stays, less pain, and fewer postoperative complications^{6,7}.

In the case of this patient, the abnormal number of ventral hernias made it impossible to perform laparoscopic correction, taking advantage of the open technique, whose advantage allows the placement of meshes that help increase the resistance of the abdominal wall and complete resection of the hernia sacs, reducing the chances of recurrence, but making the postoperative period more complex in view of the fact that the surgical wounds are larger than in the laparoscopic approach and require more extensive tissue repair.

Tissue repair is a complex process intrinsically related to the baseline health status of patients, while healthy and young organisms tend to have better results in this delicate arrangement, while comorbid and older patients have a slow tissue repair process and, in some scenarios, ineffective⁴.

In the reported case, it is evident that the patient in question had long-standing comorbidities, among which there are those that can, directly or indirectly, interfere with the efficacy and speed of tissue repair; One of these pathologies is hypothyroidism, characterized, in a simple way, by the slowing of metabolism in general, which slows down the biological processes also responsible for tissue repair or healing⁸.

Neto et al, 2017, in a literature review that associated the presence of hypothyroidism with tissue proliferation alterations in scars, surgical or not, elucidated that, in general, patients with deficiencies in T3, T4, and TSH hormones had systemic alterations that justified the delay in healing and cell repair, which extended the time it takes to close wounds; This literature review also associated this fact with the prolonged state of inflammation in patients with hypothyroidism.

Specifically in relation to muscle cells, the layer linked to the aponeurosis responsible for the occurrence of hernias, one study observed that their regeneration is closely related to



intracellular T39. Thus, the literature concludes that the absence of thyroid hormones is capable of delaying wound repair processes⁸.

Inflammation alone is one of the obstacles to the proper execution of the tissue proliferation process by tissue recovery and wound healing mechanisms. This state of inflammation may be reinforced by other comorbidities, such as metabolic syndrome, a condition also presented by the patient in the reported case. The deposition of fat in the abdominal region, in addition to promoting additional effort in the local muscle layer, generates oxidative stress and alters coagulation factors, promoting a procoagulant state, which can directly affect the tissue repair process¹.

The procoagulant state derived from the metabolic syndrome is due to the increase in fibrinogen and PAI-1, in addition to other coagulation factors, on a smaller scale. Although patients such as the one reported with open wounds may benefit from being less predisposed to bleeding. The state of procoagulation can, in addition to exposing the patient to the risk of thrombotic vascular involvement, delay the blood supply to the region dependent on tissue proliferation, and, consequently, adequate healing¹.

Another factor, and probably the most relevant in this case, is the patient's long-standing Diabetes Mellitus (DM). There is a lot of scientific evidence that supports the fact that diabetic patients have a significant delay in the healing process when compared to healthy patients. The mechanisms by which this occurs are diverse¹⁰.

Or Diabetes mellitus (DM) includes a group of hyperglycemic diseases that are related to disorders of protein and fat metabolism, in addition to glucose. This disease is a global health problem, whose International Diabetes Federation estimates that, if the trend continues, it will affect 628.6 million people in the world. world in 2045².

Although metabolic syndrome may encompass DM as one of its main components, in the reported case this comorbidity is highlighted due to the mechanisms involved in its pathophysiology that directly impact the organic capacity to respond to tissue proliferation stimuli, especially due to the microangiopathic involvement observed³.

DM II commonly affects adult individuals with erroneous lifestyle and eating habits; the increase in abdominal circumference, called apron abdomen (also observed in this patient), linked to visceral adipose tissue proportionally increases the levels of circulating fatty acids, which triggers a systemic inflammatory and prothrombotic state, a fact that brings to light that not only the body fat content is an important risk factor, but also the but rather the place of deposition of the same^{2,3,10}.



The prolonged hyperglycemic state affects the micro and macrovasculature, precipitating the emergence of other pathologies, such as thrombosis and ischemic events. In addition, this systemic vascular involvement has an impact on the healing process of the affected individual's body, since the microcirculation plays a crucial role in conducting nutrients and immunological agents to the most exposed regions¹⁰⁻¹².

Reactive oxygen species (ROS) are cellular components strictly related to the regulation of cell activity, including the endothelial layer. These components are regulated by antioxidants, a process called Oxidation and Reduction Balance (Redox). Redox dysfunction is the causal factor of cellular oxidative stress. Hyperglycemia stimulates cell glycolysis, causing an excessive production of by-products from this degradation, which causes DNA damage and consequent activation of DNA repair enzymes^{13,14}.

Endothelial lesions caused by DM cause a reduction in protective factors that regulate platelet aggregation, muscle tone, fibrinolysis, and activation of leukocytes and inflammatory cytokines. The decrease in these homeostatic components promotes, in general, a picture of procoagulability (reinforced by the other components of the metabolic syndrome, such as abdominal fat deposition, in the case of this patient), inflammatory and pro-constrictor of the blood vessels, especially those of smaller caliber; The sum of these factors becomes an almost insurmountable obstacle to effective cell proliferation and tissue recovery of areas affected by injuries^{3,15}.

Finally, the patient's age and previous surgeries may have been a mandatory factor in the unfavorable outcome of the healing process; Older patients present, physiologically, a metabolic deceleration, which slows down the complex mechanism of tissue repair and proliferation; In addition, tissue resistance decreases to 80% after one surgery and even more after another, i.e., multiple surgical incisions have an additive effect and would increasingly aggravate wall flaccidity^{4,16}.

Finally, it can be concluded that both hypothyroidism, metabolic syndrome, especially DM alone, and the patient's age were predisposing factors for the observed outcome. Evidently, post-procedure healing would have been more successful in the absence of so many associated risk factors; However, in complex cases such as this, where the non-approach may result in worse complications than those presented by the patient, it is up to the attending team to decide on the safest alternative, always counting on the possibility of unfavorable recovery and ineffective healing of the wound left by the surgical procedure.



REFERENCES

- I Diretriz Brasileira de Diagnóstico e Tratamento da Síndrome Metabólica. (2005, abril). Arquivos Brasileiros de Cardiologia, 84, 3–28. Disponível em <https://www.scielo.br/j/abc/a/qWzJH647dkF7H5dML8x8Nym/?lang=pt#>. Acesso em 18 fev. 2024.
- Diretrizes da sociedade brasileira de diabetes. (2019). Sociedade Brasileira de Diabetes. São Paulo. Disponível em <https://www.saude.ba.gov.br/wp-content/uploads/2020/02/Diretrizes-Sociedade-Brasileira-de-Diabetes-2019-2020.pdf>. Acesso em 22 fev. 2024.
- Aguiar, L. G. K. de, et al. (2007, março). A microcirculação no diabetes: implicações nas complicações crônicas e tratamento da doença. Arquivos Brasileiros de Endocrinologia & Metabologia, 51(2), 204–211. Disponível em <https://www.scielo.br/j/abem/a/WCXPmF4BptP7YyVvhHrQJ6j/#>. Acesso em 18 fev. 2024.
- Campos, A. C. L., et al. (2007, janeiro). Cicatrização de feridas. ABCD. Arquivos Brasileiros de Cirurgia Digestiva (São Paulo), 20(1), 51–58. Disponível em <https://www.scielo.br/j/abcd/a/wzTtGHxMQ7qvkBbqDLkTF9P#>. Acesso em 19 fev. 2024.
- Hope, W. W., & Tuma, F. (2023, junho 12). Incisional hernia. StatPearls, StatPearls Publishing. Disponível em <https://www.ncbi.nlm.nih.gov/books/NBK435995/>. Acesso em 18 fev. 2024.
- Van den Dop, L. M., et al. (2021). Hybrid operation technique for incisional hernia repair: a systematic review and meta-analysis of intra- and postoperative complications. Hernia: The Journal of Hernias and Abdominal Wall Surgery, 25(6). Disponível em <https://www.ncbi.nlm.nih.gov/pmc/articles/PMC8613158/>. Acesso em 21 fev. 2024.
- Parker, S. G., et al. (2021). Identifying predictors of ventral hernia recurrence: systematic review and meta-analysis. BJS Open, 5(2). Disponível em <https://www.ncbi.nlm.nih.gov/pmc/articles/PMC8038271/>. Acesso em 24 fev. 2024.
- Medeiros Neto, L. P., Martin, A. A., & Arisawa, E. A. L. (2017). Efeitos do hipotireoidismo sobre a reparação tecidual. Revista Univap, 23(43), 85–101. Disponível em <https://revista.univap.br/index.php/revistaunivap/article/view/1780>. Acesso em 24 fev. 2024.
- Dentice, M., et al. (2010). The FoxO3/type 2 deiodinase pathway is required for normal mouse myogenesis and muscle regeneration. The Journal of Clinical Investigation, 120(11). Disponível em <https://www.ncbi.nlm.nih.gov/pmc/articles/PMC2964991/>. Acesso em 4 fev. 2024.
- Banday, M. Z., et al. (2020). Pathophysiology of diabetes: An overview. Avicenna Journal of Medicine, 10(4), 174-188. Disponível em <https://www.ncbi.nlm.nih.gov/pmc/articles/PMC7791288/>. Acesso em 21 fev. 2024.



Clyne, A. M. (2021). Endothelial response to glucose: dysfunction, metabolism, and transport. *Biochemical Society Transactions*, 49(1). Disponível em <https://www.ncbi.nlm.nih.gov/pmc/articles/PMC7920920/>. Acesso em 20 fev. 2024.

Cole, J. B., & Florez, J. C. (2020). Genetics of diabetes mellitus and diabetes complications. *Nature Reviews Nephrology*, 16(7). Disponível em <https://www.ncbi.nlm.nih.gov/pmc/articles/PMC9639302/>. Acesso em 20 fev. 2024.

Darenskaya, M. A., et al. (2021). Oxidative stress: Pathogenetic role in diabetes mellitus and its complications and therapeutic approaches to correction. *Bulletin of Experimental Biology and Medicine*, 171(2). Disponível em <https://www.ncbi.nlm.nih.gov/pmc/articles/PMC8233182/>. Acesso em 20 fev. 2024.

Deng, L., et al. (2021, fevereiro 4). The role of oxidative stress and antioxidants in diabetic wound healing. *Oxidative Medicine and Cellular Longevity*, 2021, 8852759. Disponível em <https://www.ncbi.nlm.nih.gov/pmc/articles/PMC7884160/>. Acesso em 22 fev. 2024.

Pagan, L. U., et al. (2018). Função endotelial e exercício físico. *Arquivos Brasileiros de Cardiologia*, 111(4), 540-541. Disponível em <https://abccardiol.org/article/funcao-endotelial-e-exercicio-fisico/>. Acesso em 21 fev. 2024.

Smith, J., & Parmely, J. D. (2023, agosto 8). Ventral hernia. StatPearls, StatPearls Publishing. Disponível em <https://www.ncbi.nlm.nih.gov/books/NBK499927/>. Acesso em 22 fev. 2024.