



## DeBakey type 1 acute aortic dissection: Diagnostic and clinical challenges

### Dissecção aórtica aguda tipo 1 de DeBakey: Desafio diagnóstico e clínico

DOI: 10.56238/isevjhv3n2-011

Receipt of originals: 03/19/2024

Publication Acceptance: 04/09/2024

**Carlos Eduardo da Costa Nunes Bosso<sup>1</sup>, Rafaela Keiko Uieda<sup>2</sup>, Matheus de Souza Camargo<sup>3</sup>, Pablo Milhorança Pinheiro<sup>4</sup>, Maíra Milhorança Pinheiro<sup>5</sup>, Maria Clara do Nascimento Perpétuo<sup>6</sup>, Paulo Vitor Ferreira<sup>7</sup>, Armando Carrromeu Dias Pioch<sup>8</sup>, Isabela Piovesana Fardin<sup>9</sup>, Yago Mendonça Gervasoni<sup>10</sup>, Mirella Freire Bassan<sup>11</sup>, Alberto Benedito Sãovesso Froio Lourenço<sup>12</sup>, Guilherme Rodrigues Ragassi<sup>13</sup>.**

#### ABSTRACT

Acute aortic dissection (AAD) is a clinical condition with an obscure prognosis, possibly fatal and complicated diagnosis. Among the diseases that cause chest pain, the diagnosis of AAD is usually one of the least speculated, and imaging tests are often necessary to raise this hypothesis. The present case report aims to describe the clinical condition of admission and the therapeutic approach adopted in a patient who was admitted to the emergency department complaining of severe chest pain, radiating to the mandible. The initial suspicion was AMI, and catheterization was instituted, which did not show any coronary obstruction. A chest X-ray raised suspicion of AAD, which was confirmed with a CT angiogram. Although she received an incorrect diagnosis at first, the patient underwent the procedures correctly and received the appropriate treatment, having survived the acute aortic dissection.

**Keywords:** Aortic dissection, DeBakey, Cardiac surgery.

---

<sup>1</sup> Lattes: 2190592790293176

Cardiologist - Universidade do Oeste Paulista

<sup>2</sup> Lattes: 8711939006693563

Medical Doctor - University of the West of São Paulo

<sup>3</sup> Undergraduate student in medicine at the University of Oeste Paulista

<sup>4</sup> Lattes: 0519049247591691

Undergraduate student in medicine - Universidade do Oeste Paulista

<sup>5</sup> Lattes: 2748498829781236

Undergraduate student in medicine - Universidade do Oeste Paulista

<sup>6</sup> Lattes: 8045728673048875

Undergraduate student in medicine - Universidade do Oeste Paulista

<sup>7</sup> Lattes: 2347161452318654

Undergraduate student in medicine - Universidade do Oeste Paulista

<sup>8</sup> Lattes: 7782298528620114

Undergraduate student in medicine - Universidade do Oeste Paulista

<sup>9</sup> Lattes: 1932739709037204

Undergraduate student in medicine - Universidade do Oeste Paulista

<sup>10</sup> Lattes: 8803044589474130

Undergraduate student in medicine - Universidade do Oeste Paulista

<sup>11</sup> Lattes: 8729909321911405

Undergraduate student in medicine - Universidade do Oeste Paulista

<sup>12</sup> Lattes: 4323386407120968

Undergraduate student in medicine - Universidade do Oeste Paulista

<sup>13</sup> Lattes: 2781308810982380

Undergraduate student in medicine - Universidade do Oeste Paulista



## INTRODUCTION

Acute aortic dissection (AAD) is a clinical condition with an unclear prognosis, possibly fatal evolution and complicated diagnosis that depends on adequate and early management to ensure the patient's survival. Among the diseases that can cause chest pain, the diagnosis of AAD is usually one of the least speculated, and imaging studies are often necessary to raise this hypothesis<sup>1</sup>. Statistics indicate that about 30% of aortic dissection cases receive an incorrect diagnosis before reaching an accurate diagnosis<sup>2</sup>.

The pathophysiology of AAD is not yet fully understood, but theories consist of the loss of the layered structure of a segment of the aorta, generating blood entry through the intimal layer into the media layer – the blood is contained between the media and the intima, without the latter breaking. Blood accumulation in this region can be extensive to the point of creating a false lumen in the artery, and can be identified in imaging studies<sup>2,3</sup>. Another possibility is that there is extravasation of the *vasa vasorum*, which leads to the formation of blood reserves between the aortic layers in a manner similar to the process of influx due to loss of continuity of the intima layer<sup>3</sup>.

Along with penetrating aortic ulcers and intramural hematomas, aortic dissection is part of the group of diseases responsible for acute aortic syndrome<sup>3</sup>. These pathologies, although different, can lead to similar clinical pictures and evolve in parallel in the same individual; All of them represent a high morbidity and mortality factor if not detected and treated early<sup>3,4</sup>.

The most pronounced risk factors for developing AAD are those related to the cardiovascular system or disorders involving collagen production. Systemic arterial hypertension (SAH) is the most prevalent among patients undergoing acute aortic dissection: more than 70% of them had SAH. Blood pressure variations induced by strenuous exercise and the use of vasoactive drugs are also considered in this statistic. Collagen diseases lead to weakening of the arterial layers, which can result in aortic dissection<sup>3</sup>. Previous cardiac surgeries, with endovascular aortic repairs, may also represent a high risk factor for AAD<sup>5</sup>.

The diagnosis is relatively complicated, mainly because of the non-specific clinical picture. The main complaint in the face of AAD is severe chest pain, which can radiate to the back; The presence of this symptom is common in about 90% of patients. Symptoms such as syncope, decreased level of consciousness, and loss of pulses in the lower limbs are representative of more severe conditions, and may indicate cardiac tamponade or decreased cerebral blood perfusion, requiring rapid intervention<sup>1-3</sup>.



In the face of a presentation with poor specific signs and symptoms, the aid of imaging resources is essential to confirm the diagnosis and, sometimes, even to raise this as a diagnostic hypothesis for acute chest pain <sup>2</sup>. To facilitate the diagnosis of suspected AAD, investigating risk factors has been shown to be very useful in clinical practice; patients with Marfan syndrome, for example, have significant collagen disorders, and therefore have a high risk of aortic dissection. Patients with a positive family history, aortic surgery, more localized chest pain, and pulse discrepancy are important indicators of AAD <sup>2,5</sup>.

Although they can guide the diagnostic hypothesis very well, the risk factors do not have high enough accuracy to rule out other pathologies of the cardiovascular system, such as extensive acute myocardial infarction (AMI), for example. Therefore, imaging tests are essential to confirm the diagnosis. Considering the most commonly available resources, chest X-ray may play an important role in the diagnosis, showing mediastinal enlargement. However, its sensitivity is around 80%, and a considerable fraction of patients with AAD will not, in fact, present any mediastinal alteration <sup>1,6</sup>.

Chest CT angiography, which is widely available and has superior sensitivity to chest X-rays, shows the presence of a clear separation between the true lumen – the physiological one – and the false lumen – the one formed by the accumulation of blood between the middle and intima layers of the aorta. This separation is called *a flap*. This examination can also show the severity of aortic involvement and lesions of important branches, and should be chosen to diagnose patients with hemodynamic stability. In urgent cases, the imaging procedure should be performed at the bedside, and transthoracic echocardiography is a good alternative <sup>1,6</sup>.

Regarding laboratory tests, differential diagnoses should be considered, with troponin to rule out or confirm AMI. D-dimer has some relevance for the diagnosis, however, its sensitivity is high for several diseases associated with coagulation, therefore, low values, below 500 ng/mL, generally serve to exclude the diagnosis; High values are not used for <sup>confirmation</sup><sup>1,6</sup>.

The objective of this case report is to describe the clinical condition of admission and the therapeutic approach adopted in a patient who was admitted to the emergency department of the hospital complaining of severe chest pain, radiating to the mandible, which had started with lower intensity 5 days ago. The initial suspicion was AMI, and catheterization was instituted, which did not show any coronary obstruction. The chest X-ray raised suspicion of AAD, which was then confirmed with a CT angiogram. Although she received an incorrect diagnosis at first, given the non-specificity of the symptoms and the severity of the condition if the initial diagnosis



was confirmed, the patient underwent the relevant procedures correctly and received the appropriate treatment, having survived the acute aortic dissection.

## **METHODOLOGY**

This is a case report based on the medical records of a well-documented 58-year-old female patient. The study was approved by the ethics committee of the Presidente Prudente Regional Hospital. This study followed the guidelines of the National Council for Research Ethics (CONEP) during its elaboration. To complement the content, searches were carried out in electronic databases, such as PubMed, Lilacs and Scielo.

## **CASE REPORT**

A 58-year-old female patient, living in a city in the region, was referred via the regulation service, with severe chest pain, radiating to the mandible, associated with nausea. She was eupneic, oriented, and in regular general condition. The patient was hypertensive, measuring 160 x 80 mmHg, tachycardic, and saturated 93% in room air. Pulmonary and cardiac work-ups did not show any noteworthy alterations.

She reported that she sought care in her city of origin after starting with typical chest pain at rest, radiating to the jaw and sweating five days before admission to the emergency room of this service. At the time, she was medicated with painkillers and released. On the following day, the patient sought care again, and then an electrocardiogram (ECG) was performed, which showed symmetrical T-wave inversion, indicating ischemia in the inferior and anterolateral walls. She received care and was inserted into the regulation system, and was then transferred to this referral hospital for catheterization.

After admission to this service, and based on the care initiated at the emergency care unit in the patient's city, the patient was taken for catheterization at the hospital's hemodynamics service. The examination did not show any obstruction, which clearly indicated that it was not an AMI. Imaging tests were requested for further investigation.

Chest X-ray showed widening of the mediastinum; A computed tomography angiography of the aortic artery was requested, which revealed a mural hematoma that extended from the ascending aorta to the descending portion, demonstrating DeBakey grade 1 dissection. In addition, an abdominal aortic aneurysm was detected, extending to the infrarenal segment, without mural thrombi. The patient was admitted to the coronary care unit (CCU), hypertensive and using nitroglycerin (Tridil®) 5 ml/h, conscious, oriented, eupneic on room air, reporting



chest pain at the slightest exertion. ASA, clopidogrel and Clexane were discontinued and hydration for renal protection was initiated.

Preoperative and routine examinations were performed, which did not show any electrolyte or infectious alteration or the presence of anemia that would prevent the performance of a surgical procedure. Although the patient required surgical correction, the case was kept under conservative treatment, because at the time there was a platelet deficit in the hospital's blood bank, and the patient was hemodynamically stable, which allowed the adoption of this approach.

The patient remained under strict blood pressure control in the two days prior to her surgery, and there were no complications during this period. On the third day of hospitalization, the platelet stock had been replenished and surgery could take place normally.

The surgical procedure was performed in the morning. The surgical team described the condition as extensive, being a thoracoabdominal aneurysm with retrograde enlargement to the ascending aorta, with a significant intramural hematoma in this portion. An aortic root reconstruction was performed, and a Dacron 26 prosthesis was used. The abdominal aortic aneurysm was not addressed at the time. The surgery went well, without interurrences, and after the procedure the patient was taken to the intensive care unit.

The patient progressed well in the postoperative period, being extubated on the same day and maintained only with a 2.5 L/min O mask. There was no chest tube output during this period. Postoperative antibiotic prophylaxis was initiated. On the third postoperative day, the use of beta-blockers was resumed; Blood pressure and heart rate were off-target, slightly increased, with 145x54 mmHg and 96 bpm, respectively.

The evaluation of the vascular surgery team determined that the abdominal aneurysm in the infrarenal portion of the patient could receive outpatient follow-up and elective surgical scheduling.

On the fourth postoperative day, the patient was discharged from the intensive care unit and referred to the cardiology ward. During the entire period after the surgical procedure, there were no complications, respiratory and urinary symptoms, or events that would justify more time under intensive care.

Still on the fourth day, the patient presented an isolated episode of fever; Antibiotic therapy was maintained, and the patient remained under observation by the cardiology team. There were no new febrile episodes and no new complaints referring to urinary or respiratory



infection. There was a slight neutrophilic leukocytosis in the leukogram on the eighth postoperative day, but it resolved between the eleventh and twelfth days of hospitalization.

Antibiotic therapy was completed one day after the normalization of the leukogram, and the patient was discharged 16 days after being admitted to the hospital's emergency room. Currently, she is under outpatient follow-up with cardiology and vascular surgery, to evaluate the evolution of the aortic root reconstruction procedure and also to follow up the elective surgical procedure to repair abdominal aortic aneurysm, respectively.

## RESULTS

After catheterization, it was determined that the patient did not have any coronary obstruction that would justify her chest pain, and therefore, other causes should be investigated. The team immediately opted for the aid of imaging tests, and the chest X-ray immediately revealed an enlargement of the diaphragm, compatible with aortic dissection.

To confirm the diagnosis, a CT angiography was performed, which revealed a type 1 DeBakey dissection, which was surgically approached and resolved after aortic root reconstruction. The patient progressed well, thanks to the quick action of the team that treated her, and fully recovered from the event. Currently, she continues to be monitored on an outpatient basis by cardiology and vascular surgery teams and has controlled blood pressure and no other symptoms related to the initial condition.

## DISCUSSION

Annually, the incidence of acute aortic dissection is around 3.5/100,000 inhabitants. Men over the age of 60 are the majority among the new cases<sup>1</sup>. Although it may be a low incidence when compared to other diseases of the cardiovascular system, such as acute myocardial infarction, for example, which has a mortality rate of about 183.3/100,000 inhabitants in Brazil, cases of AAD cannot be treated with indifference, given their complexity and high risk of mortality<sup>7</sup>.

Regarding the complexity of the diagnosis, the lack of specific signs and symptoms of AAD often dispels clinical reasoning from this diagnostic hypothesis immediately. A French study indicates that about 30% of patients admitted with symptoms compatible with AAD receive an incorrect diagnosis first. This data shows the difficulty of establishing the correct relationship between symptoms and cause in cases of aortic dissection, not due to the lack of



experience of the medical team, but due to the need to act quickly in the face of differential diagnoses that are confused with AAD <sup>2</sup>.

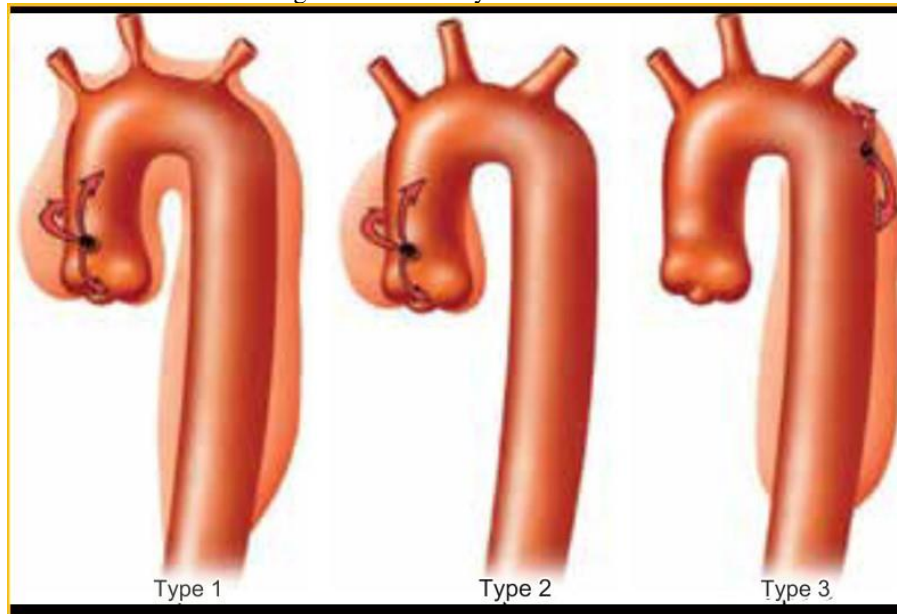
In the reported case, the patient received initial care in her city of origin and, guided by the clinical presentation and the suggestive ECG, the physicians believed it to be an AMI, establishing contact with the regulation center for urgent transfer of the patient. After admission to the hospital, the patient was treated for AMI and catheterization was performed. It was only when it was found that there was no coronary obstruction that it was determined that the origin of the chest pain was due to another cause.

The sequential approach followed a rational sequence, since the patient, although still with chest pain at that time, but to a lesser extent thanks to the measurement, presented hemodynamic stability, which allowed the performance of more sensitive and specific exams; radiography was essential to bring up the suspicion of AAD. Mediastinal dilatation is present in about 80% of patients with aortic dissection, and although it is not enough to confirm the diagnosis, it was decisive for the follow-up of the investigation <sup>1</sup>.

Computed tomography angiography, the test of choice for patients with hemodynamic stability, determined the presence of dissection and intramural hematoma, in addition to the infrarenal abdominal aneurysm in the patient's aorta. The specificity and sensitivity of this test are superior to radiography, which allows the diagnosis to be made based on the findings, especially the *Flap*, which shows true and false light caused by intramural hematoma <sup>1,6</sup>.

Regarding the classification of the dissection frame, there are currently two very common anatomical classifications: the Stanford classification and the DeBakey classification (used by the team that treated the patient at the hospital). In the latter, there are 3 possible denominations, namely: type 1 when the delamination affects from the ascending aorta to the aortic arch, type 2 when the delamination is restricted to the ascending aorta, and type 3 when it affects only the descending aorta.

Figure 1 – DeBakey's classification



Source: adapted from Dinato et al, 2018.

The patient in this case had a type 1 DeBakey dissection, in addition to a thoracoabdominal aneurysm that extended to the descending portion of the aorta, where there was a large intramural hematoma. From the classification shown in Figure 1, this is the most extensive involvement, equivalent to Stanford's type A, potentially fatal if not diagnosed and managed correctly early <sup>8</sup>.

Regarding the types of complications, we can separate them into 2 types: hemorrhagic syndromes, usually associated with complete or partial kneecap of the aorta, usually after hypertensive peaks, and malperfusion syndromes, associated with impairment or occlusion of the true lumen of the aorta by the intramural hematoma, causing a reduction in the flow of the branches that originate from the aorta and irrigate viscera, kidneys and lower limbs <sup>2</sup>.

The literature points to several risk factors that are attributed to a higher risk of developing AAD, such as hypertension, aortic valve defects, collagen disorders, dyslipidemia, and age <sup>1,2</sup>. A risk factor that is still not well understood is endovascular repair of the thoracic aorta; The association between repair and development has been shown to have a low incidence, but a high degree of lethality, and further studies are needed to evaluate the aspects related to the increase in morbidity and mortality after the intervention <sup>5</sup>.

Finally, it was possible to conclude that, although there was a misdiagnosis by the team that performed the first consultation, one should take into account the scarcity of resources at the site, which justified the transfer of the patient, and also the non-specificity of an acute aortic dissection. Even with the setbacks in the care, it was possible to conduct the case satisfactorily



and avoid a worsening of the condition. The patient fully recovered and was discharged 18 days after admission.

It is necessary to be attentive to nonspecific signs and symptoms, allowing differential diagnoses not to be far from clinical practice, without differences in incidence and prevalence being taken into account; It is completely acceptable that a complaint of chest pain that radiates to the jaw is confused and treated at first as an AMI, but once this hypothesis is discarded, it is essential to keep in mind the less frequent diagnoses that can be made, and the way to confirm them and act as soon as possible. AAD is a serious clinical condition that, although infrequent, represents a high risk of mortality, and therefore, it is necessary to understand its mechanisms and how to act in the face of such a high risk of life for the patient.



## REFERENCES

- Dinato, F. J., Dias, R. R., & Hajjar, L. A. (2018). Dissecção da aorta: manejo clínico e cirúrgico. *\*Rev Soc Cardiol Estado de São Paulo\**, 28.
- Tchana-Sato, V., Sakalihasan, N., & Defraigne, J. O. (2018). La dissection aortique. *\*Rev Med Liege\**, 73.
- Ferrera, C., Vilacosta, I., Cabeza, B., Cobiella, J., Martínez, I., & Sanz, M. S. P., et al. (2020). Diagnosing Aortic Intramural Hematoma: Current Perspectives. *\*Vascular Health and Risk Management\**, 16.
- Li, G., Xu, X., Li, J., & Xiong, S. (2021). Thoracic Endovascular Aortic Repair for Retrograde Type A Aortic Intramural Hematoma. *\*Frontiers in Cardiovascular Medicine\**, 8.
- Chen, Y., Zhang, S., Liu, L., Lu, O., Zhang, T., Jing, Z., et al. (2017). Retrograde Type A Aortic Dissection After Thoracic Endovascular Aortic Repair: A Systematic Review and Meta-Analysis. *\*J Am Heart Assoc\**, 6.
- Gupta, A. K., & Senaratne, J. M. (2021). Type A aortic intramural hematoma. *\*BMJ Case Rep\**, 14.
- Santos, J., Meira, K. C., Camacho, A. R., Salvador, P. T. C. O., Guimarães, R. M., Pierin, A. M. G., et al. (2018). Mortalidade por infarto agudo do miocárdio no Brasil e suas regiões geográficas: análise do efeito idade-período-coorte. *\*Ciênc Saúde Colet\**, 23.
- Kanda, T., Tawahara, K., Nakamura, N., Tokonami, Y., Aoshima, H., Matsukura, G., et al. (2021). Difficulty Diagnosing Retrograde Type A Aortic Dissection with Intramural Hematoma and Risk of Re-dissection and Rupture: A Report of Two Cases. *\*Intern Med\**, 60.