



Large adenomatoid odontogenic tumor: Case report

Tumor odontogênico adenomatóide de grande extensão: Relato de caso

DOI: 10.56238/isevjhv3n2-012

Receipt of originals: 29/03/2024

Publication acceptance: 04/19/2024

Tagna de Oliveira Brandão¹, Bruna Borges Nery², Dara Vitória Pereira Lopes Silva³, Davi Matos de Ferreira⁴, Carolina Rosa Barros Oliveira⁵, Lorrان de Andrade Pereira⁶, Juliana Maria Araújo Silva⁷, Edval Reginaldo Tenório Júnior⁸.

ABSTRACT

Adenomatoid odontogenic tumor (OAT) is a benign, uncommon neoplasm of odontogenic epithelial origin, believed to originate from the remains of the dental lamina or enamel organ, representing 2-7% of all odontogenic tumors. Clinically, they are slow-growing, asymptomatic, and rarely exceed 3.0 cm in diameter. AOT has three distinct clinicopathologic variants without any relevant clinical and radiographic differences between them: intraosseous follicular (associated with tooth impaction, generally making up 70% of cases); intraosseous follicular extra-follicular (present between erupted teeth, accounting for 25% of cases); and peripheral (extraosseous, 5% of cases). The objective of this study is to report a case of a large and aggressive adenomatoid odontogenic tumor. A 13-year-old male patient was presenting with a 1-month increase in the volume of the right maxilla. On physical examination, an increase in volume was observed in the middle third of the right face, causing facial asymmetry, and on intraoral examination, a bulging was observed in the bottom of the maxillary vestibule on the right with a firm consistency, mucous membranes with a normal appearance, absence of dental unit 13, stable dental occlusion, good mouth opening, and unsatisfactory oral hygiene. Imaging (CT scan) revealed a hypodense image in the right maxilla, osteolytic, well-circumscribed, with a radiopaque halo, causing expansion of bone corticals without their rupture, associated with an

¹ ORCID: 0000-0002-8276-3145

Resident in the Oral and Maxillofacial Surgery and Traumatology Service, OSID/UFBA/HGE, Salvador, Bahia, Brazil

² ORCID: 0000-0001-8211-0550

Intern at the Oral and Maxillofacial Surgery and Traumatology Service of OSID/UFBA/HGE, Salvador, Bahia, Brazil

³ ORCID: 0000-0001-8660-833X

Intern at the Oral and Maxillofacial Surgery and Traumatology Service of OSID/UFBA/HGE, Salvador, Bahia, Brazil

⁴ ORCID: 0000-0002-0791-7706

Intern at the Oral and Maxillofacial Surgery and Traumatology Service of OSID/UFBA/HGE, Salvador, Bahia, Brazil

⁵ ORCID: 0000-0002-4993-1135

Resident in the Oral and Maxillofacial Surgery and Traumatology Service, OSID/UFBA/HGE, Salvador, Bahia, Brazil

⁶ ORCID: 0000-0002-1389-5662

Oral and Maxillofacial Surgeon at the Oral and Maxillofacial Surgery and Traumatology Service of OSID/UFBA/HGE, Salvador, Bahia, Brazil

⁷ ORCID: 0000-0002-3053-4690

Oral and Maxillofacial Surgeon at the Oral and Maxillofacial Surgery and Traumatology Service of OSID/UFBA/HGE, Salvador, Bahia, Brazil

⁸ ORCID: 0000-0001-9604-9850

Preceptor of the Oral and Maxillofacial Surgery and Traumatology Service of OSID/UFBA, Salvador, Bahia, Brazil



included and impacted dental unit 13. Enucleation and complete curettage of the lesion and extraction of the associated unit 13 were performed, and a lesion presenting a fibrous capsule was observed during the operation. The patient is being monitored by the team, with no signs of recurrence so far. Thus, there is a rapid and aggressive evolution, being noticeable and clinically confused with the behavior of an amelolastoma, however the histopathological diagnosis of AOT was confirmed, in addition the lesion responded well to the conservative surgical technique through enucleation and curettage, presenting an excellent result.

Keywords: Oral surgery, Maxillary neoplasms, Oral pathology.

INTRODUCTION

Adenomatoid odontogenic tumor (OOT) is an uncommon benign neoplasm of odontogenic epithelial origin, believed to originate from the remains of the dental lamina or enamel organ, representing 2-7% of all odontogenic tumors^{1,2}.

It usually affects young patients, with a predilection for females, occurring mainly during the second or third decade of life, and two-thirds of all cases are diagnosed when the patient is between 10 and 19 years old. The anterior region of the maxilla and the mandible are the most common sites to occur, and it is found twice as often in the maxilla (65%) as in the mandible^{1,2,3}.

Clinically, they are slow-growing, asymptomatic, and rarely exceed 3.0 cm in their largest diameter, although they can reach up to 7 cm^{3,4}. In general, the increase in volume is perceived as one of the first symptoms, and it can cause expansion of bone corticals in addition to causing displacement of dental units. Root resorption, cortical destruction, and soft tissue infiltration are uncommon characteristics².

AOT has three distinct clinical-pathological variants without any relevant clinical and radiographic differences: intraosseous follicular (associated with tooth impaction, usually comprising 70% of cases); intraosseous extrafollicular (present between erupted teeth, representing 25% of cases); and peripheral (extraosseous, 5% of cases)^{5,6}.

Radiographically, in about 75% of cases, the tumor appears as a well-defined, unilocular radiolucent that surrounds the crown of an unerupted tooth, most often a canine. They may show some degree of calcification within them, the nature of which varies from nonspecific globules to cementum. These tumors are supported by a thick, fibrous capsule of active tissue that makes separation of the lesion from the tooth and surrounding bone easily. Therefore, they can be confused with an apical cyst, dentigerous cyst, calcifying odontogenic cyst, odontogenic keratocyst, and also ameloblastoma^{1,3}.

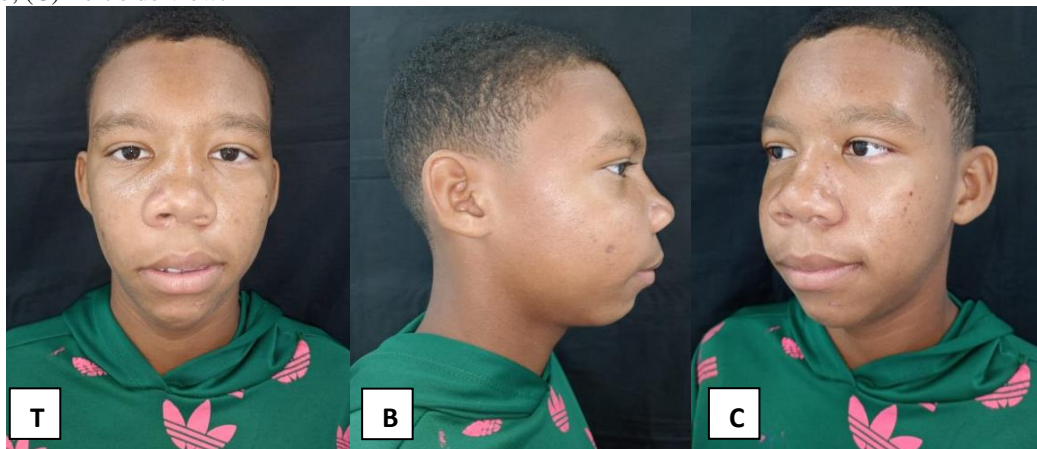
Recurrence has been described, but it is extremely rare, making extensive and aggressive surgical approaches unnecessary. The surgical management of this lesion would be to be enucleation along with the impacted tooth associated because of its capsule; It is easily enucleated from bone^{1,7}.

The objective of this study is to report a case of a large, aggressive adenomatoid odontogenic tumor in a young male patient.

CLINICAL CASE

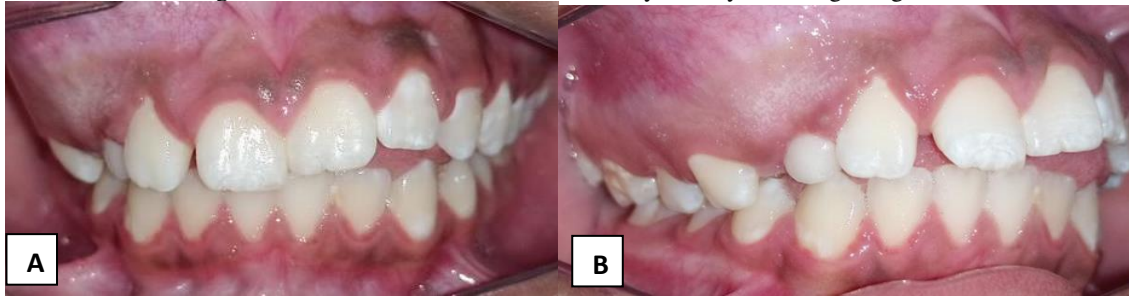A 13-year-old male patient, melanoderma, attended the oral and maxillofacial surgery and traumatology outpatient clinic of the Professor Edgar Santos University Hospital, located in Salvador-BA. The patient was presenting with an increase in volume in the right maxilla with an evolution of 01 month, with pain on palpation, On physical examination, an increase in volume was observed in the middle third of the right face, causing facial asymmetry (Figure 1).

Figure 1. (A) Preoperative frontal view after physical examination; (B) Lateral view on the right showing an increase in volume; (C) Left side view.



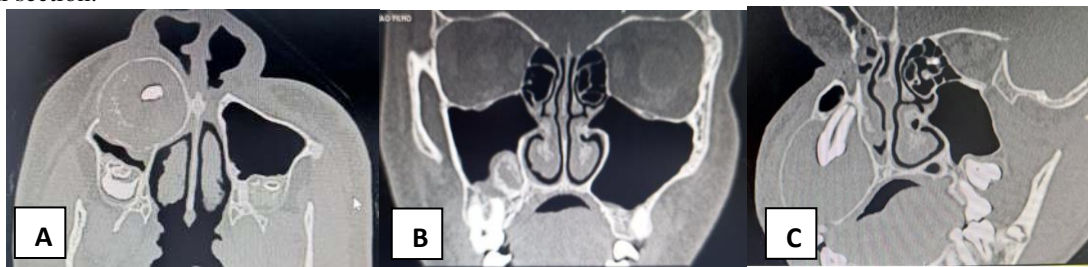Intraoral examination revealed a bulging at the bottom of the right maxillary vestibule with a firm consistency, normal mucous membranes, absence of dental unit 13, stable dental occlusion, good mouth opening, and unsatisfactory oral hygiene (Figure 2).

Figure 2. Intraoral examination showed asymmetry in the right region.



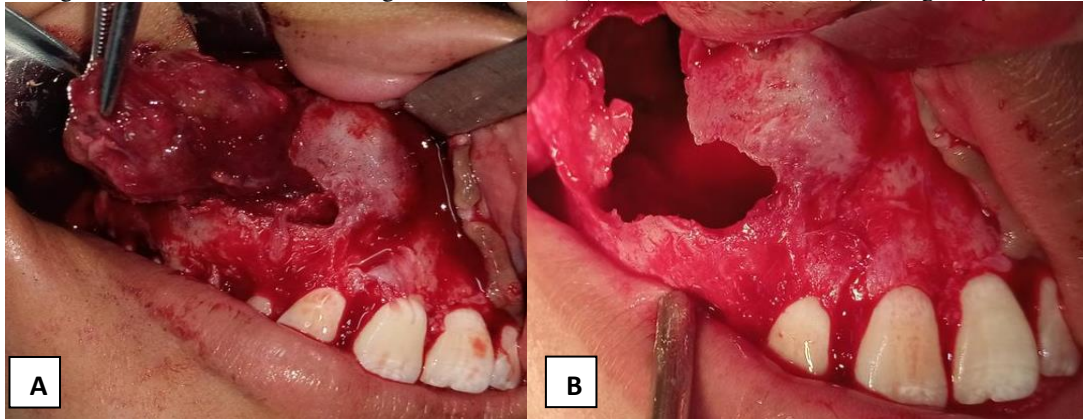
On imaging (computed tomography of the face), I notice a hypodense image in the right maxilla region, osteolytic, well circumscribed, with a radiopaque halo, causing expansion of bone corticals without their rupture, associated with the dental unit 13 included and impacted, so that the initial suspicion was ameloblastoma (Figure 3).

Figure 3. Facial tomography showed the hypodense region with cortical expansion in the right maxilla, circumscribed, with a radiopaque halo, associated with the dental unit 13. (A) Axial cutting; (B) coronal section; (C) Sagittal section.



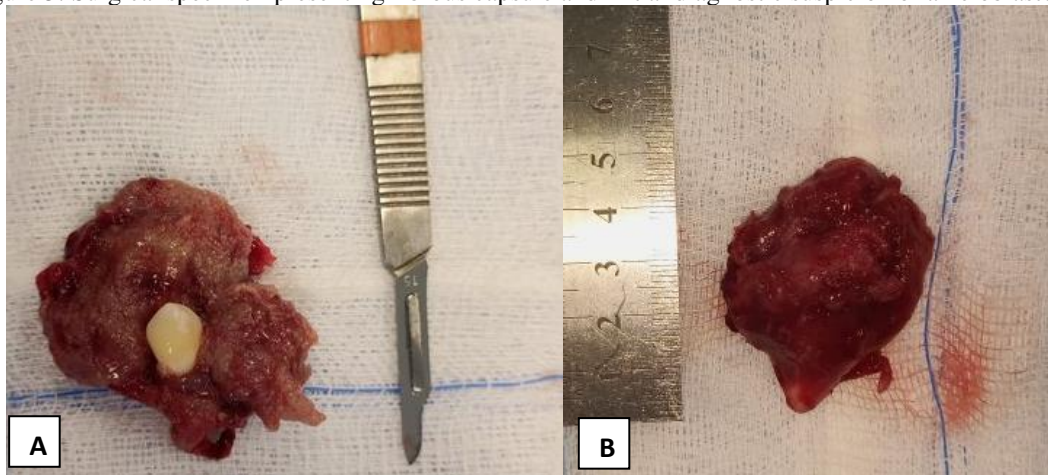
For the surgical approach, access was performed in the right maxillary vestibule fundus, mucoperiosteal detachment, due to the expansion of the lesion the bone was fragile and thin, therefore, it was not necessary to use rotating instruments for osteotomy. In the transoperative period, the lesion presented a fibrous capsule with a good cleavage point, and the lesion was enucleated and curettaged, as well as extraction of the dental unit 13 included and impacted, associated with the lesion (Figure 4)

Figure 4. Nucleation and curettage of the lesion. (A) removal of the lesion; (B) Surgical pocket.



The surgical specimen was packed in 10% formaldehyde and sent for anatomopathological evaluation, whose final diagnosis was adenomatoid odontogenic tumor.

Figure 5. Surgical specimen presenting fibrous capsule and initial diagnostic suspicion of ameloblastoma.



The patient is being monitored by the oral and maxillofacial surgery and traumatology team, with no signs of recurrence so far and with the following clinical aspect.

Figure 6. Extraoral images of the patient on the 27th postoperative day. (A) front view; (B) left side; (C) Right side.

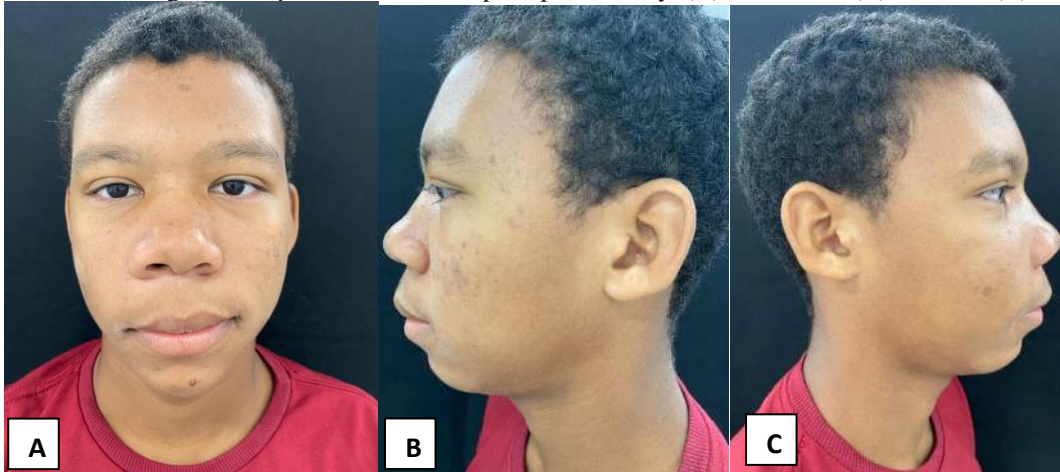
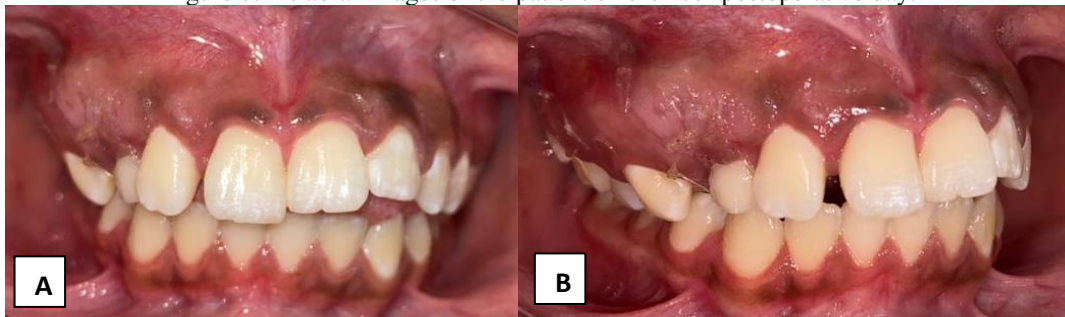


Figure 7. Intraoral images of the patient on the 27th postoperative day.



DISCUSSION

OAT is a benign odontogenic lesion that has been considered non-invasive, but aggressive, slow-growing and progressive, so this nature can cause patients to tolerate swelling for years until it produces an obvious deformity^{8,9,10}. It often causes expansion of the surrounding cortical bones and displacement of adjacent teeth¹⁰. It is generally considered an uncommon tumor, but it is responsible for approximately 3% to 7% of odontogenic tumors and is considered the fourth most frequent among them^{7,8}.

Studies have observed its prevalence in women in a ratio of 2:1 in relation to men, and it is diagnosed more frequently in the second decade of life, which makes the present study atypical, as it affects a 13-year-old male individual. In addition, it predominantly affects the anterior region of the maxilla, being 2.6 times more affected than the mandible ^{4,8,11}.

It is well established that AOT has three clinical variants that were originally described by the research group of Philipsen et al. in two publications (1991)¹² and (1992)¹³. These variants are as follows: Central (or intraosseous) variants: (1) The follicular (or pericoronal) type in which TOA is associated with the crown of an unerupted tooth; (2) The extrafollicular (or extracoronal) type in which the OAT has no association with the crown of an unerupted tooth



and (3) the peripheral (or gingival) variant (TOAP). The case presented here is traditionally classified as FOLICULAR central type AOD.

In this sense, the follicular variant has accounted for 71% of AOD lesions, so that the literature reports that canines are involved in 59% of these cases, especially the upper ones^{8,11}. In the reported case, the lesion was associated with dental unit 13, which was displaced close to the orbital floor region.

Conventional radiographs, such as panoramic radiography and periapical radiographs, are often used as a first step in the diagnosis of AOD, since it is usually discovered through routine radiographic examinations⁸. However, conventional radiographs do not provide sufficient details about the exact extent of the lesion and its relationship with neighboring structures, and computed tomography should be used¹⁵. tag.

The differential diagnosis of OAT is challenging due to its clinical and radiographic similarity to other odontogenic lesions, such as dentigerous cyst, keratocyst, calcifying odontogenic tumor, and ameloblastoma. The main differential diagnosis is dentigerous cyst and ameloblastoma, since they correspond to the most common odontogenic cyst and odontogenic tumor¹⁵. According to Câmara et al. (2016)¹⁶, 77% of AOT cases are initially diagnosed as dentigerous cysts, and what will differentiate OAT from other odontogenic lesions is that in AOT there are foci of radiopacity within it. The reported case presented a rapid and aggressive evolution, which was noticeable and clinically confused with the behavior of an amelolastoma. However, in the histopathological examination it was possible to observe the presence of duct-like structures, foci of calcification, and areas of cells with clear and standard cytoplasm, with the histopathological diagnosis of TOA.

As for treatment, surgical enucleation and curettage of the lesion is the main treatment of choice, since the tumor is encapsulated, which allows complete removal¹⁷. Phillipsen et al. (2007)¹⁵ conducted a retrospective collaborative study that included a comprehensive analysis of the clinical and epidemiological profile of AOT. The results of this study reinforce the efficacy of surgical removal as the main treatment for AOD. Studies suggest the use of decompression devices in some cases, such as in cases of atrophic mandible, to reduce the injury and subsequent enucleation, in order to avoid unwanted fractures¹⁸. In the present case, the lesion responded well to surgical therapy through enucleation and curettage, with no signs of recurrence to date and with an excellent prognosis.



CONCLUSION

Adenomatoid odontogenic tumor is a benign neoplasm with distinctive clinical, radiographic, and histological features. Therefore, it is worth emphasizing the importance of the correct diagnosis, involving a combination of clinical evaluation, imaging tests, and histopathological analysis, as in the case in question. The surgical approach is the main pillar and, although the recurrence rate is low after complete removal of the lesion, regular follow-up is essential.



REFERENCE

- Al-Shimari, F., Chandra, S., & Oda, D. (2017). Adenomatoid odontogenic tumor: Case series of 14 with wide range of clinical presentation. **J Clin Exp Dent**, 9(11), e1315–e1321.
- Nel, C., Uys, A., Robinson, L., & van Heerden, W. F. P. (2021). Multiple adenomatoid odontogenic tumours associated with eight impacted teeth. **Oral Radiol**, 37(2), 321–327. Disponível em: <https://doi.org/10.1007/s11282-020-00471-w>
- Karam Genno, N., Aoun, N., & El Toum, S. (2017). Adenomatoid odontogenic tumor associated with an impacted maxillary lateral incisor: A case report with five-year follow-up. **Case Rep Dent**, 2017.
- Okura, S., Igarashi, C., Wakae-Morita, S., Eda, T., Ito, H., Nakashima, K., et al. (2021). Differential diagnosis between calcifying odontogenic cyst and adenomatoid odontogenic tumor by computed tomography images. **Oral Radiol**. Disponível em: <https://doi.org/10.1007/s11282-021-00531-9>
- Sadasivan, A., Ramesh, R., & Kurien, N. M. (2020). Peripheral adenomatoid odontogenic tumor — A rare cause of gingival enlargement: A case report with CBCT findings. **Clin Cosmet Investig Dent**, 12, 297–304.
- La Monaca, G., Pranno, N., di Gioia, C. R. T., Pompa, G., Vozza, I., & Cristalli, M. P. (2019). Surgical management of extrafollicular variant of adenomatoid odontogenic tumor in the maxillary posterior region. **Case Rep Dent**, 2019(2017), 1–7.
- Thakur, A., Tupkari, J. V., Joy, T., & Hanchate, A. V. (2016). Adenomatoid odontogenic tumor: What is the true nature? **Med Hypotheses**, 97(October), 90–93. Disponível em: <http://dx.doi.org/10.1016/j.mehy.2016.10.024>
- Siriwardena, B. S. M. S., Udagama, M. N. G. P., Tennakoon, T. M. P. B., Athukorala, D. A. A. D. W., Jayasooriya, P. R., & Tilakaratne, W. M. (2020). Clinical and demographic characteristics of adenomatoid odontogenic tumors: Analysis of 116 new cases from a single center. **Braz J Otorhinolaryngol**. Disponível em: <https://doi.org/10.1016/j.bjorl.2020.06.004>
- Jayasooriya, P. R., Rambukewella, I. K., Tilakaratne, W. M., Nihal Mendis, B. R. R., & Lombardi, T. (2020). Clinico-pathological presentations of cystic and classic adenomatoid odontogenic tumors. **Diagnostics**, 10(1), 1–13.
- Prakasam, M., Tiwari, S., Satpathy, M., & Banda, V. R. (2013). Adenomatoid odontogenic tumour. **BMJ Case Rep**, 1–4.
- Philipsen, H. P., Khongkhunthiang, P., & Reichart, P. A. (2016). The adenomatoid odontogenic tumour: An update of selected issues. **J Oral Pathol Med**, 45(6), 394–398.
- Philipsen, H. P., Reichart, P. A., Zhang, K. H., Nikai, H., & Yu, Q. X. (1991). Adenomatoid odontogenic tumor: Biologic profile based on 499 cases. **J Oral Pathol Med**, 20(4), 149–158.



- Philipsen, H. P., Samman, N., Ormiston, I. W., Wu, P. C., & Reichart, P. A. (1992). Variants of the adenomatoid odontogenic tumor with a note on tumor origin. **J Oral Pathol Med**, 21(8), 348–352.
- Ide, F., Mishima, K., Saito, I., & Kusama, K. (2009). Diagnostically challenging epithelial odontogenic tumors: A selective review of 7 jawbone lesions. **Head Neck Pathol**, 3(1), 18–26.
- Philipsen, H. P., Reichart, P. A., Siar, C. H., Ng, K. H., Lau, S. H., Zhang, X., et al. (2007). An updated clinical and epidemiological profile of the adenomatoid odontogenic tumour: A collaborative retrospective study. **J Oral Pathol Med**, 36(7), 383–393.
- Câmara, P. R., Dutra, S. N., Carmo, A. B., Júnior, A. T., & Azevedo, R. S. (2016). Tumor odontogênico adenomatóide: Relato de um caso clínico destacando os seus principais diagnósticos diferenciais. **Rev. Bras. Odontol.**, 73(4).
- Katiyar, A., Gupta, S., Gupta, K., & Pandey, M. (2019). Trauma to Tumor: A Hunt of Adenomatoid Odontogenic Tumor – A Rare Case Report. **Int J Clin Pediatr Dent**, 14(4), 366–369.
- Figueiredo, N. F. D., Pinto, L. G., Silva, M. S., Neto, J. M. B., Costa, D. F. N., & Inaoka, S. D. (2021). Tumor odontogênico adenomatóide em região posterior de mandíbula: Relato de caso adenomatoid odontogenic tumor in the posterior region of the mandible: Case report. **Rev Fac Odontol Univ Fed Bahia**, 51(1), 58–65.