



Surgical correction of 7 abdominal wall hernias using a hybrid technique

Correção cirúrgica de 7 hérnias de parede abdominal por técnica híbrida

DOI: 10.56238/isevjhv3n2-017

Receipt of originals: 03/18/2024

Publication acceptance: 08/04/2024

Helen Brambila Jorge Pareja¹, Eduardo Alves Canedo², Elisangela Maria Nicolete Rampazzio³, Armando Carromeu Dias Pioch⁴, Luiza Queiroz Pettinate⁵, Gabriel Trevisan Del Hoyo⁶, Brenda Vieira Azambuja Carneiro⁷, Caroline da Silva Barreto Santos⁸.

ABSTRACT

Incisional hernias are defects of the abdominal wall under previous scarring. They are an important epidemiological factor, since they are responsible for 11% of laparotomy surgeries performed by surgeons. They have local and systemic symptoms, including pain, fullness, bulging and edema, and can even complicate ischemia and tissue necrosis. Comorbidities are important aggravating factors and the surgical techniques used for correction, including laparotomy and laparoscopy, should be resolute to avoid complications, including recurrences. The technique of herniorrhaphy and hernioplasty are constantly described in the literature, but the use of mixed technique is something little seen that challenges the knowledge of the medical team and addresses the professional's discernment to encompass both previous knowledge and the patient's social and comorbid profile.

Keywords: Hernia, Correction, Hernioplasty, Herniorrhaphy.

INTRODUCTION

Ventral hernias are defined by non-inguinal and non-hiatal defects in the abdominal wall, and can be divided into acquired or congenital, the former being more prevalent¹. Incisional hernias refer to a group of acquired ventral hernias that correspond to defects in the proper closure of the abdominal wall, more specifically the aponeurosis, with occasional protrusions of

¹ Physician, Digestive Surgeon

University of Oeste Paulista, Santa Casa de Misericórdia de Presidente Prudente

² Physician, General Surgery Resident

Hospital Regional de Presidente Prudente

³ High school, medical student

University of the West of São Paulo

⁴ High School, Medical Student

University of the West of São Paulo

⁵ High school, medical student

University of the West of São Paulo

⁶ High School, Medical Student

University of the West of São Paulo

⁷ High school, medical student

University of the West of São Paulo

⁸ High school, medical student

University of the West of São Paulo



abdominal contents or with all the hernia components of the defect, sac and contents. Incisional hernia can occur either in places that have suffered some type of trauma or in surgical incisions^{1,2,3}.

The pathophysiology of hernia formation is not very well understood. Intimate fascial healing is essential to avoid wall closure defects, but several factors can contribute to prevent this from occurring, including technical factors related to sutures², and hernia recurrence is closely related to the efficacy of surgical repair⁴. The gaps in the surgical incision separated by the edges, later filled by scar tissue, when it occurs in the presence of factors that can lead to tissue healing errors, predisposes to the appearance of incisional hernias². Such risk factors include: systemic diseases (diabetes mellitus, hypothyroidism, neoplasms, etc.), habits and addictions (alcoholism, smoking, drug addiction), factors related to surgical technique, advanced age, etc.^{2,3}.

The anterior abdominal wall is composed of several layers, including skin, peritoneum, fat, fascia, and muscle, having the order variable according to the site, and repetitive stress due to increased intra-abdominal pressure can lead to multiple microscopic tissue ruptures, in addition to factors that hinder healing can contribute to the fragility of the wall, such as oxidative stress from pre-existing comorbidities and from the surgery itself. In addition to these risk factors, tissue resistance decreases to 80% after one surgery and even more after another, i.e., multiple surgical incisions have an additive effect and would increasingly aggravate wall flaccidity¹.

The symptoms of hernia include: pain, edema, fullness at the site of occurrence that may change with the Valsava maneuver and, when enclosed, may attribute tissue ischemia¹. When they require surgical correction, incisional hernias can benefit from two techniques: open correction or laparoscopic correction. Studies have shown that both techniques have advantages and disadvantages, but laparoscopic correction benefits from shorter hospital stays, less pain, and fewer postoperative complications. The open technique, on the other hand, allows the advantage of placing meshes that help increase the resistance of the abdominal wall and complete resection of the hernia sac, reducing the chances of recurrence. Intestinal injury is one of the main intraoperative complications and, when it occurs, absorbable mesh can be a good solution after entrotorrhaphy, given the fact that the placement of non-absorbable meshes in contaminated fields can aggravate the infection³.

Several different types of meshes are available, ranging from synthetic or biological, permanent or absorbable origin². The study by Parker, S. G. 2021⁴ found that the use of meshes in hernia repair surgeries did not show differences between the groups of synthetic and



biological origin regarding the recurrence outcome, but reaffirmed that recurrence is the most common complication of hernia repairs. In addition, such infections follow the podium of complications soon after recurrence. It is noteworthy that mesh placement is contraindicated in the presence of infections at the surgical site for the treatment of hernias.

In general, the defect in the fascia should be closed when it is less than 10 centimeters, and when it is upper with meshes. The component separation technique can be used when the approximation of the edges is not plausible to be performed².

METHODOLOGY

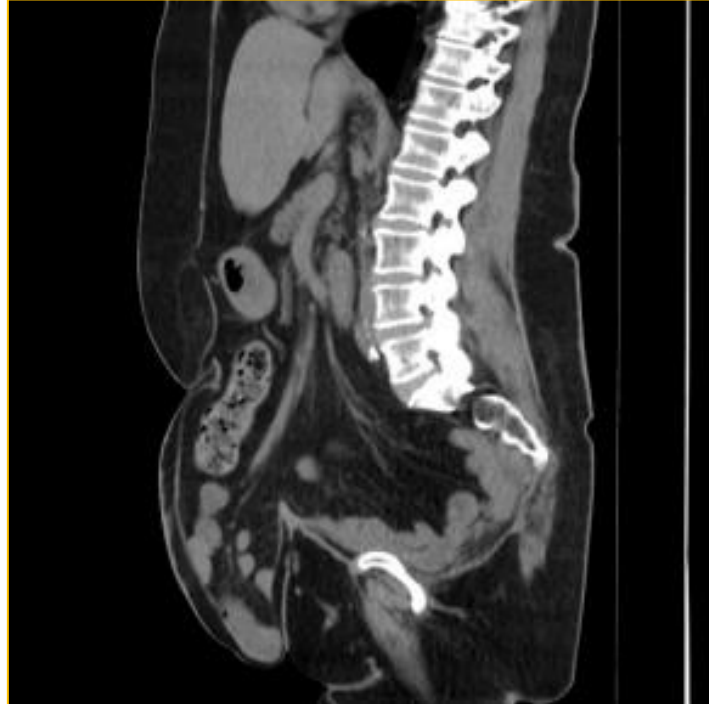This is a case report type, in which information was collected through a review of medical records. At the same time, to support the ideas discussed in this article, a literature review was carried out in scientific databases such as PubMed and Scielo. The production of this scientific article followed the regulations proposed by the National Research Council (CONEP).

CASE REPORT

A 67-year-old female patient, white, married, with no schooling, Catholic, sought medical attention with a complaint of bulging and pain in the abdominal region due to a previous surgical scar since 2015, but in recent months she has presented significant worsening of pain, especially on exertion, which limits it during daily activities. The patient is obese, with an apron abdomen, and has a history of type II diabetes on Metformin and Glycazide, hypertension on losartan potassium, dyslipidemia on simvastatin and hypothyroidism on levothyroxine sodium.

She has undergone 3 previous surgeries (two surgeries for metachronic treatment due to colorectal cancer, in 2011 and 2013, and one intestinal transit reconstruction). Abdominal physical examination revealed the presence of bulging in the laparotomy surgical scar in the midline region, bulging in the right hypochondrium and left flank over the scar of the colostomy surgical incision, all with prominence to the Valsalva maneuver, but hypogastro without manual reduction. A CT scan of the total abdomen was requested for surgical programming (Figure 1).

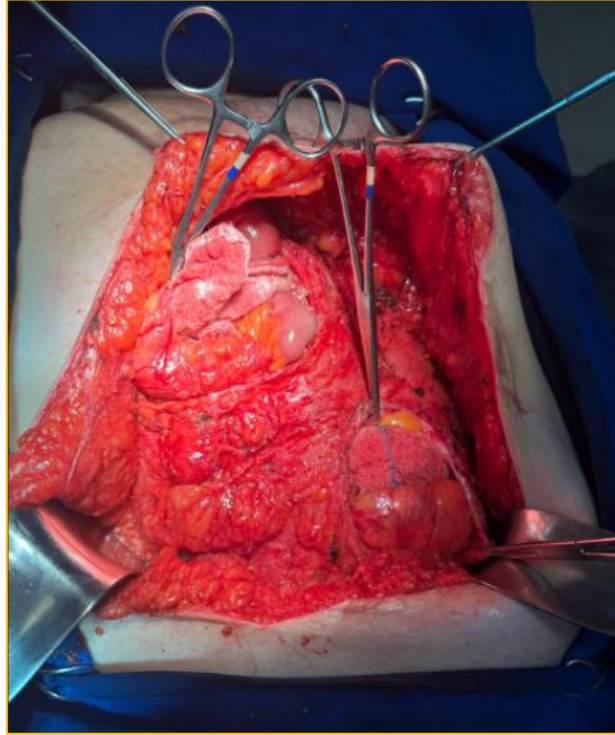
Figure 1 – CT scan sections of the abdomen



Source: the authors.

After a detailed study of the disease with complementary exams, the presence of 7 ventral hernias was found (see figure 1) and it was decided to use a double-sided mesh in the lower portion, where the axis was not able to be approached, and in the other primary approaches with the use of a mesh to avoid recurrence. The patient underwent a mixed surgical procedure of herniorrhaphy and hernioplasty to close the injured aponeuroses, reconstructing the abdominal wall.

Figure 2 – Open correction technique

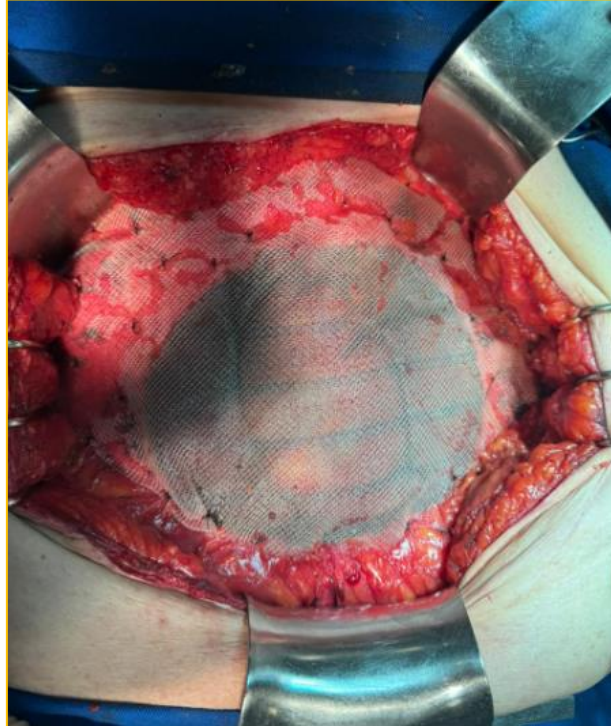


Source: The Authors

For the herniorrhaphy procedure, a 30x30 centimeter (cm) polypropylene mesh was used, using the primary closure of the technique, with the criterion of choice for hernias of smaller diameter, in a total of 6 hernia rings, which allowed the approximation of the edge of the aponeuroses, located in the epigastrium;

Hernioplasty was chosen at the discretion of larger hernias located in the hypogastrium, which did not allow the approximation of the aponeurotic borders, at the risk of compartment syndrome, and for this purpose, a 15x20 cm oval PCDG1 double-sided mesh was used in direct contact with the intestinal loops.

Figure 3 – Use of meshes for hernia repair.



Source: the authors

The mixed technique was necessary due to the number of lesions presented by the patient's abdominal wall and its fragility. There were no complications during surgery. The patient is fed the same day and discharged from the hospital the next day.

DISCUSSION

The patient in the reported case has at least two risk factors for the occurrence of herniations through the abdominal wall, in addition, the history of previous surgeries increased the chances of incisional hernias, since multiple surgical incisions have an additive effect of sagging in the abdominal wall, increasing the chances of incidence as the surgical frequency increases^{1,6}.

Laparoscopic correction with the use of meshes provides better results than the open technique⁸, however, for this patient, the presence of numerous hernias made it impossible to use a single surgical technique or laparoscopic technique in order to avoid new recurrences. Therefore, the formulation of a mixed technique of herniorrhaphy and hernioplasty in open correction was chosen.

Incisional hernias are an economic problem in Brazil, accounting for 1% of sick leaves, and many risk factors have been identified, such as obesity, diabetes mellitus, smoking, COPD, etc.⁵. According to the Brazilian Society of Hernia and Abdominal Wall (SBH), DataSUS



reported that 404 thousand hernia repair procedures were performed in Brazil between 2020 and 2022, representing the most frequent surgery performed by surgeons⁸.

Although the patient was relatively old and had important comorbidities that made the surgical procedure considerably more complex, the impact on her quality of life justified an intervention to try to mitigate the problems caused by the unfolding of the hernias. According to the SBH, the surgical treatment of hernias, whether of any origin, should occur when symptoms appear, disrupting the quality of life of patients or posing imminent health risks⁸.

The Technique *Sublay* In the case of this patient, hernioplasty was chosen for those hernias with larger diameters, without the possibility of primary approximation of the fascia. PCDG1 double-sided meshes were placed in direct contact with the intestine. Although this specific technique has a higher record of seroma formation, there is evidence that the chances of recurrence are lower⁹.

The tendency of abdominal wall hernias is for their diameter to increase according to the traction of the abdominal muscles¹⁰, thus, herniorrhaphy, chosen for primary closure, would not be a viable option in this obese patient with an apron abdomen for large diameter hernias, due to the high percentage of risk of recurrence.

For smaller hernias, the technique used was herniorrhaphy with placement of simple polypropylene meshes. This material presents evidence of better outcomes and lower risks of dehiscence; Although it is possible to approach this type of hernia with simple sutures between the aponeuroses, evidence indicates that hernia recurrence is lower in those procedures where mesh was used⁸.

Although the use of meshes is not exempt from the risk of complications inherent to the insertion of these artificial components in the human body, the risks of techniques that do not make use of these artifacts (such as adhesions or compartment syndrome, due to the reduction of abdominal volumetric capacity after hernia spinning) far outweighed the benefits. The intraperitoneal use of prostheses is indicated in large hernias that do not allow approximation of the edges, frequent recurrences with associated intra-abdominal lesions, obese patients, and when laparoscopic access is contraindicated¹¹. The patient in the reported case presented all the criteria for its use.

Abdominal hernia correction should allow the viscera that make up the protruding sacs to be reintroduced and the wall reconstructed. The purpose of this procedure is to avoid restricting the volume of the abdominal cavity and the increase in internal pressure, so as not to complicate compartment syndrome¹¹. When evaluating the patient in the preoperative period, the medical



team observed that the large number of hernia rings over the incision and the variation in diameter between them would not allow the reconstruction of the abdominal wall in order to avoid compartment syndrome. This fact includes an important justification for the use of screens. Aponeurotic sutures would reduce the abdominal area and, consequently, increase the pressure of the cavity. The use of double-sided meshes and polypropylene was the resolute resource for this issue, as they increase the contact surface of the abdominal wall and the intracavitary space.

Regarding the types of screens themselves, the risk of adhesion was mitigated by the composition of each one. The formation of adhesions is part of the natural healing process, but they are self-limiting, until the fibrinolytic system absorbs them. This process is delayed in the presence of infections, inflammations and ischemia¹⁰. To prevent this from occurring pathologically, the double-sided mesh was used in direct contact with the viscera of the patient in this report. This mesh has both faces of different compositions: one in contact with the musculature, capable of maintaining tensile strength, avoiding recurrences; another in contact with the intestine, avoiding adhesions. Thus, this mesh was chosen in hernias with larger diameters that had intestinal protrusions involved.

As for simple polypropylene mesh, the study by Ultrabo, Cal et. Al., 2021¹² states that the difference in size between the pores influences the formation of fibroids, with those with smaller diameters (1mm) being the most responsible for these complications related to healing. For the patient in this case, this mesh was used in hernias of smaller diameter, associated with herniorrhaphy, since this same study states that the risk of dehiscence is lower with its use.

The scarcity in the literature on the mixed technique of herniorrhaphy and hernioplasty did not allow us to predict relevant prognostic data for the case that has not yet presented a complete outcome, but it allows, based on other data, to rationalize that hybridizing both procedures with the use of meshes was the best choice for this patient. Advanced age was a significant factor for the team's therapy, since quality of life is a target of any and all medical procedures, being characterized as an indispensable component for the reestablishment of health. Therefore, it is concluded that evidence-based medical judgment and available resources led to the best treatment available to the patient, and so far there have been no complications related to the surgical technique itself.

Conflicts of interest

The authors affirm that there is no potential conflict of interest that could compromise the impartiality of the information presented in this scientific article.



REFERENCES

- Smith, J., & Parmely, J. D. (2023, August 8). Ventral hernia. *StatPearls*. StatPearls Publishing. Disponível em: <https://www.ncbi.nlm.nih.gov/books/NBK499927/>. Acesso em: 22 fev. 2024.
- Hope, W. W., & Tuma, F. (2023, June 12). Incisional hernia. *StatPearls*. StatPearls Publishing. Disponível em: <https://www.ncbi.nlm.nih.gov/books/NBK435995/>. Acesso em: 18 fev. 2024.
- Van den Dop, L. M., et al. (2021). Hybrid operation technique for incisional hernia repair: a systematic review and meta-analysis of intra- and postoperative complications. *Hernia: The Journal of Hernias and Abdominal Wall Surgery*, 25(6). Disponível em: <https://www.ncbi.nlm.nih.gov/pmc/articles/PMC8613158/>. Acesso em: 21 fev. 2024.
- Parker, S. G., et al. (2021). Identifying predictors of ventral hernia recurrence: systematic review and meta-analysis. *BJS Open*, 5(2). Disponível em: <https://www.ncbi.nlm.nih.gov/pmc/articles/PMC8038271/>. Acesso em: 24 fev. 2024.
- Martins, E. F., Dal Vesco Neto, M., Martins, P. K., Difante, L. D. S., Silva, L. L. de M., Bosi, H. R., et al. (2022). Onlay versus sublay techniques for incisional hernia repair: 30-day postoperative outcomes. *ABCD, Arquivos Brasileiros de Cirurgia Digestiva*, 35, e1692. <https://doi.org/10.1590/0102-672020220002e1692>. Acesso em: 11 mar. 2024.
- Campos, A. C. L., et al. (2007). Cicatrização de feridas. *ABCD, Arquivos Brasileiros de Cirurgia Digestiva (São Paulo)*, 20(1), 51–58. Disponível em: <https://www.scielo.br/j/abcd/a/wzTtGHxMQ7qvkBbqDLkTF9P#>. Acesso em: 19 fev. 2024.
- Harries, R. L., et al. (2017). Hughes Abdominal Repair Trial (HART)-abdominal wall closure techniques to reduce the incidence of incisional hernias: feasibility trial for a multicentre, pragmatic, randomised controlled trial. *BMJ Open*, 7(12), e017235. <https://doi.org/10.1136/bmjopen-2017-017235>
- Sociedade Brasileira de Hérnia e Parede Abdominal (SBH). (2009). Hérnia da parede abdominal. Curitiba: SBH. Disponível em: <https://sbhernia.org.br/hernia/#definicao>. Acesso em: 13 mar. 2024.
- Nguyen, M. T., et al. (2014). Comparison of outcomes of synthetic mesh vs suture repair of elective primary ventral herniorrhaphy: a systematic review and meta-analysis. *JAMA Surgery*, 149(5), 415-421. <https://doi.org/10.1001/jamasurg.2013.5014>
- Araújo, U. R. M. e F. de, Czezko, N. G., Deallarmi, A., Hemoviski, F. E., & Araújo, H. V. C. P. (2010). Escolha do material da tela para disposição intra-peritoneal na correção cirúrgica de defeitos herniários da parede abdominal. *ABCD, Arquivos Brasileiros de Cirurgia Digestiva*, 23(2), 118–121. <https://doi.org/10.1590/S0102-67202010000200012>
- Speranzini, M. B., & Deutsch, C. R. (2010). Grandes hérnias incisionais. *ABCD, Arquivos Brasileiros de Cirurgia Digestiva*, 23(4), 280–286. <https://doi.org/10.1590/S0102-67202010000400015>
- Utrabo, C. A. L., Czezko, N. G., Busato, C. R., Montemór-Netto, M. R., Lipinski, L., & Malafaia, O. (2021). Between Prolene®, Ultrapro® and Bard Soft® meshes which presents the best performance in the repair of the abdominal wall? *ABCD, Arquivos Brasileiros de Cirurgia Digestiva*, 34(1), e1577. <https://doi.org/10.1590/0102-672020210001e1577>