



Acute viral bronchiolitis in infants: A narrative literature review

Bronquiolite viral aguda em lactentes: Uma revisão narrativa de literatura

DOI: 10.56238/isevjhv3n2-028

Receipt of originals: 09/04/2024

Publication acceptance: 04/29/2024

Juliana Smidt Costa¹, João de Sousa Pinheiro Barbosa², Victor Fernandes Feitosa Braga³, Ana Flávia Moura Marques⁴, Fernanda Magalhães Zendersky⁵, Beatriz da Costa Luiz Bonelly⁶, Giovanna Abe Rodrigues de Melo⁷, Vitor Henrique Soares Campelo⁸, Isabella of Almeida Cunha⁹.

ABSTRACT

Severe acute bronchiolitis is mostly caused by respiratory syncytial virus (RSV) and is the leading cause of hospitalization in children under one year of age. Despite having low mortality, it has high morbidity, requiring an early diagnosis through a detailed clinical history and physical examination. Thus, a narrative review was carried out consisting of fourteen articles found in the electronic databases PubMed/MEDLINE, SciELO and VHL, aiming to review the most current literature on the subject. Currently, the monoclonal antibody palivizumab is the main agent used in the prevention of bronchiolitis, and is available to patients who are at high risk of developing severe disease. In addition, the Abryso vaccine was recently approved by the National Health Surveillance Agency (Anvisa) and will be applied to pregnant women in the last trimester of pregnancy, aiming to prevent the disease in newborns. Finally, it was found that the adequate management of acute viral bronchiolitis consists of supportive measures, such as hydration, nutritional support, and oxygenation when necessary, while the use of corticosteroids and bronchodilators did not show a reduction in the length of hospital stay and in the natural course of the disease.

Keywords: Bronchiolitis, Treatment, Infant, Bronchodilators.

INTRODUCTION

Bronchiolitis is a common viral disease in children under one year of age that affects the lower airways. It is caused by several viruses such as adenovirus, influenza virus, rhinovirus, human metapneumovirus and *human bocavirus*, but it is the Respiratory Syncytial Virus (RSV) that is responsible for most cases and severe cases. This disease is strongly associated with

¹ E-mail: julismidt@gmail.com

² E-mail: joao.barbosa@ceub.edu.br

³ Email: viictorbraga@sempreceub.com

⁴ E-mail: anaflaviabsb@hotmail.com

⁵ E-mail: nandazendersky@gmail.com

⁶ E-mail: beatrizbonelly@sempreceub.com

⁷ E-mail: giovannameloxi@gmail.com

⁸ E-mail: vitor.henrique@sempreceub.com

⁹ E-mail: bella.cunha@bol.com.br



seasonality, its peak of infections is during the winter, between December and March in the northern hemisphere (Nicolai, 2013).

Although most children have a mild condition, many require hospitalization because they have risk factors for bronchiolitis, such as prematurity, age less than 3 months, low birth weight, maternal smoking, low socioeconomic conditions, immunodeficiency, liver diseases, neuromuscular diseases, inborn errors of metabolism, chromosomal abnormalities, congenital heart diseases, bronchopulmonary dysplasia, and chronic respiratory disease. The immaturity of the immune system of infants is characterized by quantitative and functional deficiencies of the cells when compared to adults. Such deficiency is marked by lower expression of cytokines, T cells, and CD4 and impairment of antigen-presenting cells. This significant immaturity for RSV infection ceases around 2 years of age for children without immunocompromise (Borchers, 2013).

Bronchiolitis is the leading cause of hospitalization in children under one year of age, so it becomes an economic challenge for the country and exhausting for health professionals. Although it is a disease with low mortality, it has a high morbidity, so early diagnosis and good socioeconomic conditions are essential, as these are factors that directly interfere with the prognosis (Øymar, 2014).

The diagnosis is clinical, so an accurate physical examination and a detailed patient history are required. Age, previous hospitalizations, oxygenation, signs of respiratory failure, and auscultation rich in adventitious sounds, crackles, snoring, and wheezing should be observed (Caballero, 2017). The natural course of the disease usually lasts an average of ten days, and the prodrome is characterized by an upper airway infection, such as nasal obstruction, runny nose, and cough that lasts for 3 days. The characteristic signs of the disease are nonspecific, such as wheezing, crackling, respiratory effort, tachypnea, notch retraction, and intercostal retraction (Fretzayas, 2017).

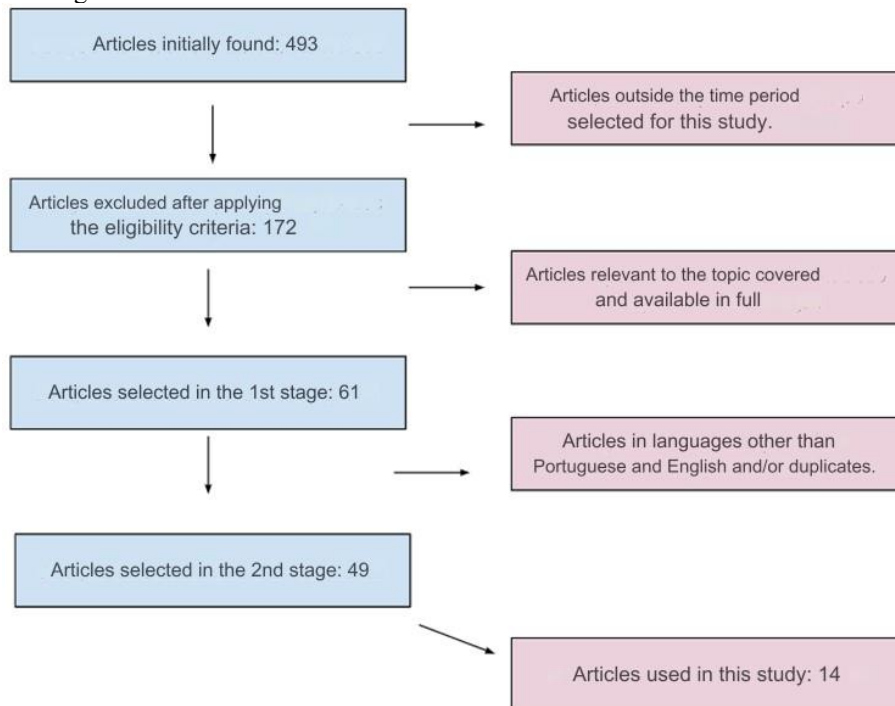
Finally, there is no specific treatment for bronchiolitis, but there are supportive procedures such as superficial nasal hygiene/washing, hydration, nutritional support, and oxygenation, if necessary (Peixoto, 2023). Currently, palivizumab, a monoclonal antibody, is the main prevention measure for bronchiolitis, and is recommended for patients at risk because it reduces severe hospitalizations (Olio, 2019).

Thus, the objective of this study is to review the most current literature on severe acute viral bronchiolitis in childhood, with emphasis on its epidemiology, clinical manifestations, risk factors, prevention, and clinical and hospital management.

METHOD

A narrative literature review was conducted, consisting of articles found in the electronic databases PubMed/MEDLINE, SciELO and VHL. Articles published in Portuguese and English during the period from 2013 to 2024 were selected, using the following Health Sciences Descriptors and Medical Subject Headings (DeCS/MeSH): "Bronchiolitis", "Treatment", "Infant" and "Bronchodilator Agents". The Boolean operator "AND" was used to relate the terms. The inclusion criteria were articles pertinent to the topic addressed and reviews of the literature available in full in the aforementioned databases. The exclusion criteria, in turn, included articles published in periods prior to 2013, in languages other than Portuguese and English, and duplicate articles.

Figure 1. Flowchart for the selection of articles used in this narrative review.



DISCUSSION

EPIDEMIOLOGY

Bronchiolitis is a marked seasonal epidemiological disease, which is directly related to its main etiological agent, respiratory syncytial virus (RSV). Its peaks usually occur during the winter months, although relatively constant infection rates are observed throughout the year. The reasons why RSV epidemics occur throughout the world are not fully scientifically known (Borchers, 2013).



Due to its high incidence among infants and young children, it is one of the main causes of hospitalization and mortality in this pediatric age group (Peixoto, 2023). It is estimated that about 3 million children are hospitalized annually, and in Brazil approximately 10.2% of cases progress to death.

It is believed that by the age of two, approximately all children will have been infected by one of the etiological agents, whether or not they develop the disease. It is known that severe presentations tend to occur between the first three months of life (Pineiro, 2024).

As for hospitalizations, it is difficult to determine infections associated with RSV and other agents, since the tests to establish the viral etiology are not performed in the outpatient and hospital routine, since the result does not affect their management and prognosis (Borchers, 2013).

CLINICAL MANIFESTATIONS

RSV infection usually begins after direct contact with respiratory secretions from infected people or contaminated objects, and after an incubation of 4 to 5 days, it initially generates an upper respiratory tract infection (URI), with classic symptoms of rhinorrhea, fever, and cough (Pimentel, 2017).

RSV has a tropism for the cells of the nasal mucosa, multiplying in the nasopharynx and thus reaching the lower airways. This event is directly linked to pulmonary immaturity and is a disease of vulnerability. This justifies the epidemiology of this disease, which mainly affects children under 2 years of age and the younger they are, the higher the cases of hospitalization (Pineiro, 2024).

The way RSV reaches the lower respiratory tract is not fully understood, but it is believed to be closely related to the aspiration of infected secretions from the initial stage. From that moment on, inflammatory processes are initiated, both by the direct cytopathic effect of the virus on the host cells and by the inflammatory reaction of the cytokines produced by the patient's immune system in order to fight the infection. This inflammatory process culminates in interalveolar lesions, mucosal lesions, submucosal lesions, and adventitia lesions of the lower respiratory epithelium. Added to this, the release of these inflammatory mediators and migration of leukocytes and macrophages also lead to the formation of local edema and debris. (Pineiro, 2024)

Bronchiolitis may present with a variety of symptoms, but the main clinical manifestations are tachypnea, fever, respiratory effort, cough, difficulty feeding/breastfeeding



due to shortness of breath. Apnea is the main symptom in very young and premature children. On physical examination, auscultation with diffuse crackles may be found in the respiratory system, due to the fluid present in the interstitium and the secretion in the alveoli. Wheezing is also observed due to smooth muscle contraction, snoring due to the presence of mucus in the upper airways, hyperinflated chest due to air trapping, intercostal retraction, tympanism to thoracic percussion, tachycardia, and decreased saturation (Peixoto F. G., 2023).

RISK FACTORS

Its severe form usually occurs in infants under six months of age, especially those who are premature or who have congenital comorbidities, such as heart disease and lung diseases, requiring hospitalization in 10 to 15% of cases. The conditions that contribute to this predisposition are associated with the immaturity of the immune system, reduced transfer of maternal antibodies and a smaller airway. In addition, it can also be associated with low energy reserve and early weaning (Pimentel, 2017).

In addition to physiological factors, there is an important weight of factors related to socioeconomic conditions. Individuals from lower social levels have a considerably higher risk of developing severe conditions, such as malnutrition and anemia. Environmental exposure to substances such as smoke, mainly linked to smoking, are also factors to be considered (Peixoto, 2023).

The risk of developing new infections is related to children under 12 months of age who have suffered an RSV infection during the first months of life, and usually occur in the following season (Borchers, 2013).

PREVENTION

The prevention of RSV contagion is a challenge, and one of the main points is the social deprivation of newborns, especially up to 3 months of age and during the seasonality of the virus. It aims to protect against RSV transmission in children who have lower lung maturity.

In addition, there are some monoclonal antibodies that can be used as a prophylactic treatment in patients who are at high risk of developing severe disease. These patients would be the ones who fit some specific risk factors. The main human monoclonal antibody used in the prevention of bronchiolitis is palivizumab, which acts against RSV fusion glycoprotein (F) by inhibiting its replication. (Garegnani L, 2021). Due to its high cost, the use of this drug is indicated as a prophylactic treatment for premature infants under 29 weeks, children who have



chronic heart and lung diseases, who may develop complications or who have immunodeficiency. Prophylactic use of this medication has an impact on decreasing RSV hospitalizations (Sun BW, 2024).

Regarding vaccination, there are already two vaccines licensed by the FDA (U.S. Food and Drug Administration), but there are many side effects and in some trials even the exacerbation of immune responses in the body of these children, such as Th2, not bringing enough advantages. In addition, RSV vaccine development is challenging due to the minimal natural defense response in infected healthy adults (SUN BW, 2024). However, the National Health Surveillance Agency (Anvisa) recently approved the bivalent Abryso vaccine, composed of two antigens of RSV surface protein F. It is an immunizer that will be applied during the last trimesters of pregnancy in order to prevent the disease in newborns (BRASIL. RESOLUTION-RE No. 1,180, of March 27, 2024).

CLINICAL AND HOSPITAL MANAGEMENT

The disease is diagnosed from your clinic, based on the presentation of typical respiratory signs and symptoms. (Borchers, 2013). Current management guidelines do not recommend chest X-rays and blood tests, and should only be performed if they present severe conditions and worsening of the clinical picture. Once the diagnosis is established, attention should be paid to the criteria for hospitalization, which include children under 3 months of age, signs of respiratory distress, respiratory rate greater than 60 per minute, saturation less than 92%, and reduced food intake (Nicolai, 2013).

Regarding its conduct, it should be noted that there is no specific therapy capable of shortening the course of the disease. In view of this, several support measures are recommended as treatment (Peixoto, 2023). The guidelines recommended in the home environment include hand hygiene, avoiding passive smoking, maintaining the child's usual diet, use of antipyretics and guidance on alarm signs. A very important measure to be adopted is nasal lavage of the infant with saline solution, aiming to improve nasal obstruction. Vigorous and deep nasal aspiration is contraindicated, as it worsens local edema and further irritates the air mucous membranes (Pimentel, 2017).

Hospital therapy mainly recommends the maintenance of oxygen saturation, good oral hydration and breastfeeding. Oxygen therapy is indicated for all patients with saturation levels below 92%, and several supplementation devices are available. The use of the high-flow nasal cannula is not yet a general consensus regarding its use, but it is capable of allowing greater



flows of humidified oxygen and providing positive pressure in the airways. Because many have difficulties in feeding due to congestion and respiratory effort, intravenous isotonic fluids or nasogastric tube should be administered (Cabellero, 2017).

There is no consensus regarding pulmonary physiotherapy in demonstrating efficacy in treatment and reduction in the length of hospital stay. Current guidelines do not recommend routine treatment of uncomplicated bronchiolitis and those who do not have comorbidities (Pinheiro, 2024).

There is some agreement among the current Guidelines that the use of corticosteroids for the treatment of the disease, both inhaled and systemic, is not indicated, since they do not have a clinically significant effect on admissions or the duration of hospitalizations (Fernandes, 2013). Although corticosteroid therapy has an anti-inflammatory action, helping to reduce edema in the respiratory mucosa and improve bronchoconstriction, it does not change the course of the disease and there are still studies that show that it is capable of prolonging viremia, and its contraindication is level B of evidence (Dall'olio, 2019).

The use of bronchodilators, such as albuterol and salbutamol, does not improve oxygen saturation and does not reduce hospital stay and disease resolution time (Gadomski, 2014). Although wheezing is present, the cause of bronchospasm is related to the presence of bronchiole debris, and there is no benefit to its use. Nevertheless, patients with a history of familial atopy may respond to bronchodilators when rhinovirus is the etiologic agent. However, when there is no possibility of etiological identification, a bronchodilator test can be performed, and should be maintained if there is an improvement in respiratory rate and pulmonary auscultation, level D of evidence (Dall'olio, 2019).

Nebulization with 3% hypertonic saline, in its first studies, seemed to show promising results in terms of its effectiveness, as it is believed that it is capable of promoting the breakdown of ionic bonds in mucus, making it more fluid and facilitating its removal. However, recent studies have brought disappointing results to its use in treatment, as it does not reduce the length of hospital stay (Barben, 2014). New high-evidence studies need to be carried out to define its role in the correct management of the disease, since its use is still quite controversial in the current literature (Zhang, 2017).



FINAL THOUGHTS

Acute viral bronchiolitis is a disease marked by its seasonality and morbidity related to respiratory syncytial virus. It is responsible for the largest number of hospitalizations of children under one year of age, with an average course of ten days of evolution.

Currently, severe cases are well correlated with predisposing conditions such as prematurity and congenital comorbidities, such as heart disease and lung disease. Thus, the use of the monoclonal antibody palivizumab as prophylaxis in these cases is recommended, given its impact on the reduction of RSV hospitalizations. Another way to prevent severe cases, recently approved by Anvisa, is the application of the Abryso vaccine, which will be applied during the last trimesters of pregnancy.

In addition, for better outcomes, it is known that, in addition to an early diagnosis, it is necessary to pay attention to the hospitalization criteria, which include: infants under 3 months of age, signs of respiratory distress, respiratory rate greater than 60 per minute, saturation less than 92%, and reduced food intake.

Regarding the hospital management of the disease, it is known that support measures are the basis of current treatment, such as oxygen therapy, hydration, and nutritional support. According to the most recent studies, the use of corticosteroids and bronchodilators is not indicated because they do not have an impact on the course of the disease and do not reduce the length of hospital stay. Finally, nebulization with 3% hypertonic saline also had no impact on the length of hospital stay. However, its use is still controversial in the literature, and more studies with high evidence are needed to define its application in the correct management of the disease.



REFERENCES

- BORCHERS, A. T. et al. Respiratory Syncytial Virus—A Comprehensive Review. *Clinical Reviews in Allergy & Immunology*, v. 45, n. 3, p. 331–379, 12 abr. 2013.
- NICOLAI, A. et al. Viral bronchiolitis in children: A common condition with few therapeutic options. *Early Human Development*, v. 89, p. S7–S11, out. 2013.
- FERNANDES, R. M. et al. Glucocorticoids for acute viral bronchiolitis in infants and young children. *Cochrane Database of Systematic Reviews*, 4 jun. 2013.
- ØYMAR, K.; SKJERVEN, H. O.; MIKALSEN, I. B. Acute bronchiolitis in infants, a review. *Scandinavian Journal of Trauma, Resuscitation and Emergency Medicine*, v. 22, n. 1, 3 abr. 2014.
- BARBEN, J.; KUEHNI, C. E. Hypertonic saline for acute viral bronchiolitis: take the evidence with a grain of salt. *The European respiratory journal*, 1 out. 2014.
- GADOMSKI, A. M.; SCRIBANI, M. B. Bronchodilators for bronchiolitis. *Cochrane Database of Systematic Reviews*, 17 jun. 2014.
- CABALLERO, M. T.; POLACK, F. P.; STEIN, R. T. Viral bronchiolitis in young infants: new perspectives for management and treatment. *Jornal de Pediatria*, v. 93, p. 75–83, nov. 2017.
- BRAZIL. *Diário Oficial*. [s.l.] Brazil, 1957.
- FRETZAYAS, A.; MOUSTAKI, M. Etiology and clinical features of viral bronchiolitis in infancy. *World Journal of Pediatrics*, v. 13, n. 4, p. 293–299, 4 maio 2017.
- ZHANG, L. et al. Nebulised Hypertonic Saline Solution for Acute Bronchiolitis in Infants. *Cochrane Database of Systematic Reviews*, n. 12, 21 dez. 2017.
- PIMENTEL, Analíria Moraes et al. Diretrizes Para O Manejo Da Infecção Causada Pelo Vírus Sincicial Respiratório (VSR)-2017. *Sociedade Brasileira de Pediatria*, 2017.
- DALL' OLIO, C.; SANT' ANNA, M.; SANT' ANNA, C. Treatment of acute viral bronchiolitis. *Residência Pediátrica*, v. 11, n. 3, 2021.
- PEIXOTO, Felipe Guedes et al. Bronquiolite viral aguda. *Revista Eletrônica Acervo Médico*, v. 23, n. 11, p. e14836-e14836, 2023
- GAREGNANI, L. et al. Palivizumab for preventing severe respiratory syncytial virus (RSV) infection in children. *Cochrane Database of Systematic Reviews*, v. 2021, n. 11, 16 nov. 2021.
- PINHEIRO, F. E. R. et al. Abordagens clínicas da bronquiolite aguda no âmbito atual pediátrico. *Brazilian Journal of Health Review*, v. 7, n. 1, p. 5837–5860, 16 fev. 2024.