



Retroperitoneal tumor: A case report

DOI: 10.56238/ESVJV3N4-007

Receipt of originals: 06/11/2024

Acceptance for publication: 07/31/2024

**Helen Brambila Jorge Pareja¹, Lara Cristina Silva Inácio², Amanda Aizza Caceres³,
Henrique Zafalon Spinardi⁴, Renata Vaz Voltareli⁵ and Natália Cervantes Uzeloto Guazi⁶**

ABSTRACT

Introduction: Retroperitoneal tumors (RPTs) are extremely rare tumors, predominant in both sexes and can be malignant or benign. Due to the inaccessibility of the region and the asymptomatic or nonspecific picture, most of the time, these tumors reach a substantial size. The most frequent symptoms are abdominal pain, discomfort, or a painless palpable mass in the abdomen. In addition to the patient's clinical history, imaging tests are essential for diagnosis. Complete surgical resection is the only potential curative treatment modality for RPT. **Objective:** To demonstrate the importance of early diagnosis for a better prognosis and treatment of RPTs. **Methods:** From a medical case that occurred at the Santa Casa da Misericórdia de Presidente Prudente, and its medical records, information was collected to carry out this report. **Results:** Benign RPTs are approximately four times less frequent than malignant ones, which makes the patient's case even more atypical. For accurate evaluation, high-quality cross-sectional images play a key role. In the case reported here, the patient had a lesion that was difficult to access, and CT-guided biopsy was prevented, for this reason, the surgical choice was made. **Conclusion:** The success of the prognosis of RPTs is influenced by multiple factors. The grade of the tumor is of paramount importance, in addition to its intrinsic biology, along with the extent of the surgical resection performed, playing crucial roles in determining prognosis and life expectancy. Therefore, detailed imaging tests and specific laboratory tests, when possible, are crucial.

¹ Master of Science in Health Sciences
University of Western São Paulo
LATTLES: 8792800011270177
E-mail: brambila_hj@hotmail.com

² Graduated in Medicine
Cesumar University
LATTES: 1863344866214507
E-mail: laraa.inacio@hotmail.com

³ Medical Graduate
University of Western São Paulo
LATTES: 8379777228587608
Email: amandacaceres882@gmail.com

⁴ Graduating from Medicine
University of Western São Paulo
LATTES: 0974349029688681
E-mail: henriquezspinardi@hotmail.com

⁵ Medical Graduate
University of Western São Paulo
LATTES: 3432751045764001
E-mail: renatavaz16@gmail.com

⁶ Medical Graduate
University of Western São Paulo
LATTLES: 2386739547111351
E-mail: nataliaguazi2000@gmail.com



Keywords: Retroperitoneal tumor, Diagnosis, Retroperitoneal sarcoma.

INTRODUCTION

Retroperitoneal tumors (RPTs) are extremely rare tumors, located in the retroperitoneum, bounded anteriorly by the posterior parietal peritoneum and posteriorly by the transverse fascia. They can be benign or malignant. Malignant cancers resulting from epithelial tissues are classified as cancers, while those resulting from non-epithelial tissues are sarcomas, which are more prevalent. (CHOI and RO, 2020) Soft tissue sarcomas account for 1-2% of all solid malignant tumors, with 10% of them occurring in the peritoneum, conferring a condition of notorious rarity. The most common are liposarcoma (specifically well-differentiated and undifferentiated subtypes) and leiomyosarcoma. (CHOI and RO, 2020) (SANTOS et al. 2005) (METTLIN, 1982)

The incidence of RPTs is approximately 0.3-0.4 cases per 100,000 population in the United States. This figure, although modest, does not underestimate the clinical relevance of these neoplasms, whose diagnosis and treatment often challenge the expertise of modern anatomists and pathologists. In the Brazilian context, specific data on the incidence of retroperitoneal tumors are scarce, reflecting, in part, underreporting and the lack of systematic records. (METTLIN et al, 1982) Although devoid of marked sex preference, retroperitoneal tumors manifest predominantly in adults, with an age group commonly situated between the fourth and seventh decade of life, possibly reflecting an accumulation of environmental and genetic factors over time. This age distribution suggests a complex interaction between the aging process and the biological events underlying the genesis of these neoplasms. (METTLIN et al, 1982)

The retroperitoneum is an anatomical area prone to the appearance of tumors due to its diverse tissue composition. (MOORE and DALEY, 2014) Although the etiology of RPTs is still unknown, genetic factors, environmental factors, irradiation, viral infections, and immunodeficiency may be associated with their development. (CHOI and RO, 2020) From a pathological point of view, the neoplastic cell undergoes changes in its regulatory mechanisms of multiplication and metabolism, acquires growth autonomy, and becomes independent of physiological stimuli. Therefore, cellular activities are called constructive, as they manifest continuously and without regulation. (SANTOS et al. 2007)

Develop originally from soft tissues, including fats, muscles, nerves, lymph nodes, and blood or lymphatic vessels. They can involve retroperitoneal organs, such as kidneys, adrenal glands, pancreas, and intrapelvic organs (bladder, uterus, ovaries, prostate, etc.). Invasive RPTs

may also involve large structures of the retroperitoneal lumen, such as the abdominal aorta, inferior vena cava, and ureters. (CHOI and RO, 2020)

Due to the inaccessibility of the region and the asymptomatic or nonspecific picture, most of the time, these tumors reach a substantial size. Therefore, they are usually large in presentation. (STRAUSS et al. 2011) Almost 50% are larger than 20 cm at the time of diagnosis. Symptoms secondary to retroperitoneal lesions appear late in the course of the disease and are associated with organ displacement and obstructive phenomena. (CHOI and RO, 2020) The most frequent symptoms are abdominal pain, discomfort, or a painless palpable mass in the abdomen. Moderate fever and mild leukocytosis may occur due to central necrosis of large tumors. (SANTOS et al. 2007) The diagnosis of retroperitoneal tumors is complicated by other tumor species, morphological overlap between these various tumor types, and the increasing use of minimally invasive biopsy techniques with very limited tissue. (CHOI and RO, 2020)

In addition to the patient's clinical history, which can help point out possible differential diagnoses (CHOI and RO, 2020), imaging tests are essential for diagnosis. Retroperitoneal tumors are best evaluated with good-quality cross-sectional imaging, and preoperative core biopsy histology is required when imaging is nondiagnostic. (STRAUSS et al. 2011) The imaging investigation of choice is contrast-enhanced computed tomography (CT) of the chest, abdomen, and pelvis. The size, location, relationship to adjacent organs, and presence or absence of metastases can be determined. (STRAUSS et al. 2011) Magnetic resonance imaging or PET scan can also be used. (SASSA, 2020)

A tumor composed of adipose tissue can be easily distinguished by magnetic resonance imaging or CT, however, well-differentiated liposarcomas are indistinguishable from lipomas and appear as well-defined lesions with a predominance of lipid tissue and minimal soft-tissue attenuation. In this case, needle biopsy is becoming more useful for definitive diagnosis, in addition to helping to perform histological typing and classification. (SASSA, 2020)

CT-guided biopsy techniques allow an accurate and safe diagnosis of a retroperitoneal tumor, although it is considered a risk of tumor spread at the biopsy site. The efficacy of image-guided fine-needle aspiration cytology (FNAC) has also been reported. The overall sensitivity, specificity, and diagnostic accuracy of image-guided FNA were 98.02%, 72.22%, and 94.12%, respectively. Needle biopsy instead of FNAC is recommended in the European Society of Medical Oncology Clinical Practice Guidelines – European Network Reference for Rare Solid Cancer in Adults and the National Comprehensive Cancer Network Clinical Practice Guidelines.

According to the Trans-Atlantic RPS Working Group, FNAC rarely produces diagnostic information, causes delays in treatment, and should be avoided. (SASSA, 2020)

In the determination of the histological type, the accuracy of diagnosis can be improved by using a genomic method that investigates some mutations in individual sarcomas-specific genes, specific miRNA differentiation, and translocation confirmation using fluorescent in situ hybridization, regardless of morphological diagnosis. If needle biopsy can be performed to confirm the grading system, the prognosis of each type of RPS and the cure rate associated with R0/R1 surgical resection can be estimated. Benign RPTs do not need to be treated if definitive tumor histology can be diagnosed preoperatively through needle biopsy and/or imaging. However, those with symptoms, such as pain, and those with a rapid increase in tumor size are indicated for surgical resection to distinguish benign from malignant tumors. (SASSA, 2020)

In retroperitoneal sarcomas (RPSs), tumor status after treatment is described by the residual tumor classification (R). R0 resection indicates a microscopic resection with a negative margin in which no macroscopic or microscopic tumor remains in the primary RPS bed. R1 resection indicates removal of all gross disease, but microscopic margins are positive for RPS. R2 resection indicates gross residual disease with a coarse residual tumor that has not been resected with macroscopic involvement. (SASSA, 2020) Because retroperitoneal sarcomas often involve vital structures, complete surgical resection is often not possible. (CHOI and RO, 2020)

Complete surgical resection is the only potential curative treatment modality for RPS, but local recurrence occurs in a large proportion of patients and accounts for up to 75% of sarcoma-related deaths. Resection of involved adjacent organs is often required and resection rates of adjacent viscera are reported in large ranges of 34% to 93%. (STRAUSS et al. 2011)

The surgical approach involves a low threshold for organ resection to achieve complete elimination of all gross diseases. An en-bloc resection of the sarcoma and contiguous organs that are macroscopically surrounded by or surrounded by the tumor is performed to achieve complete gross clearance. No attempt is made to resect organs that just lie adjacent to the tumor and are not involved. The most common organs that require resection are the colon, kidney, pancreas, and spleen. (STRAUSS et al. 2011) Achieving R0/R1 surgical resection for RPS increases the cure rate and prevents locoregional recurrence. Other factors contribute to the improvement of the prognosis of RPS, such as favorable tumor histology or biology, improvement of multimodal treatment, perioperative management, surgical technique, and patient biology. (SASSA, 2020)

The use of radiation therapy for the treatment of RPS, along with surgical treatment, showed good results in a combined case-control study using data from the National Clinical

Oncology database jointly administered by the American Cancer Society and the American College of Surgeons. However, the specific irradiation method, dose, and interval were absent from the database. Therefore, to verify the efficacy of perioperative radiotherapy, in Europe, a multicenter randomized controlled trial was compared between the group with preoperative radiotherapy followed by surgery and resection alone for primary treatment. However, the study results reported in 2019 did not show the usefulness of preoperative radiation therapy. Other clinical trials with radiotherapy are ongoing. (SASSA, 2020)

Regarding the use of systemic drugs for the treatment of RPSs, doxorubicin has been a key drug in the systematic treatment of RPS for approximately 30 years. Ifosfamide and other drugs have also been used in combination with doxorubicin. The choice of chemotherapy should be used separately to prolong life and shrink the preoperative tumor. Adjuvant post-surgical resection therapy with doxorubicin and ifosfamide was not recommended based on the results of a randomized controlled trial. (EORTC 62931) (SASSA, 2020)

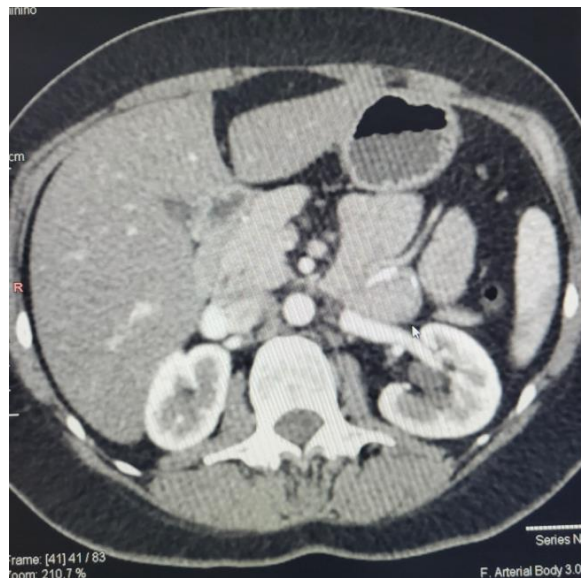
In RPTs, five-year survival for all subtypes is approximately 60%. Factors such as tumor grade, reflecting both aggressive metastatic behavior and increased incidence of local recurrence among high-grade sarcomas, tumor biology, and the extent of resection interfere with survival. Resection is the most important predictor of survival, with incomplete resection conferring a 70% increased risk of death. (FILHO, 2021)

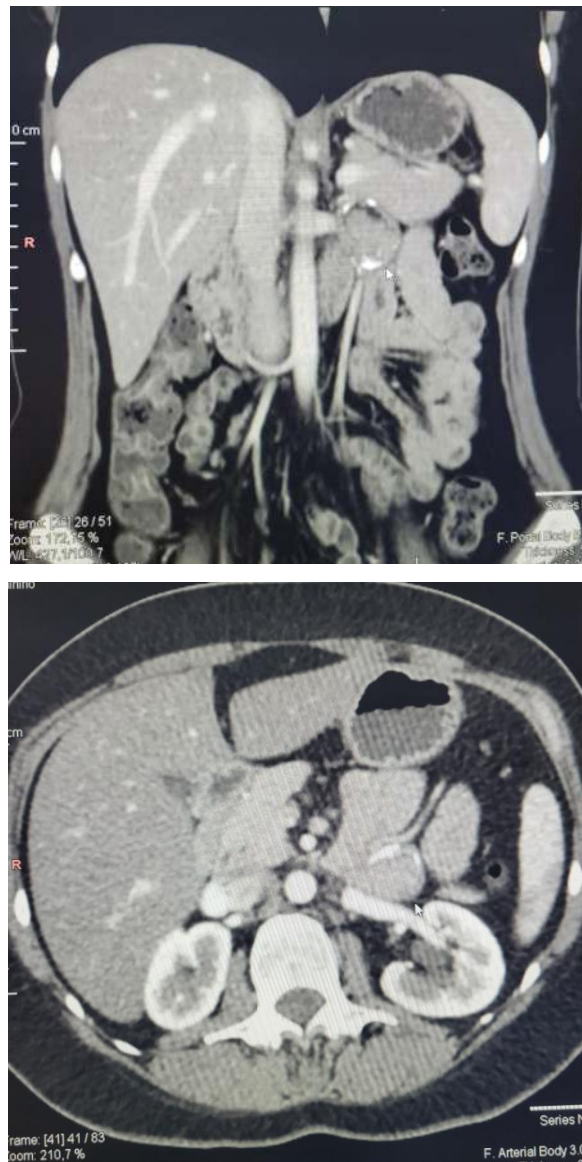
Improved survival and prevention of locoregional recurrence can be accomplished by performing surgery to ensure negative margins with wide, combined resection of some adjacent organs. The high volume of surgeons and specialized centers are associated with better patient outcomes in major oncology surgeries, including hepatobiliary/pancreatic surgery, esophagogastric surgery, and surgical oncology, so cooperation with a trained medical team composed of radiologists, pathologists, and medical oncologists in a centralized center reflects positively on the patient's prognosis. (STRAUSS et al. 2011) (NUSSBAUM et al. 2014)

CASE DESCRIPTION

Patient J.C.F.N.L., female, 40 years old, smoker, without comorbidities, and asymptomatic. He reported that he had a fracture of the coccyx and that, during imaging tests, a lesion/tumor in the retroperitoneum was evidenced, without it being possible to differentiate whether it was cancer or not. She was referred for evaluation by a gastroenterologist. She denied pain, nausea, overnight, and/or malaise. The patient was hospitalized for an elective biopsy guided by computed tomography, but after discussing the case and due to difficult access, it was

not possible to perform it. The patient was electively hospitalized for tumor excision due to suspected lymphoma. The stomach was released, accessing the abdominal retrocavity, without access to the lesion. Mantoux maneuver was attempted, with the release of the left colon with access to the lesion from both planes. In the inventory of the abdominal cavity, there was the presence of a retroperitoneal lesion below the pancreas with anterior border: inferior mesenteric vein, superior mesenteric vein; upper limit: renal vein; and posterior limit: inferior vena cava. Laparotomy was performed with oncological retroperitoneal lymphadenectomy with lymph node dissection and omentectomy for better access to the lesion. The nodule in the retroperitoneum was resected and biopsied, which resulted in a benign non-neoplastic cyst measuring 4.5/3.5/2.5 cm. The procedure was performed without complications. The patient was hemodynamically stable, without VAD, without nausea and vomiting, and with little pain. He was discharged after 4 days of hospitalization.





CASE DISCUSSION

RPTs have no predilection for sex and mainly affect adults, between the fourth and seventh decade of life, an interval that the patient falls into early onset. (METTLIN, 1982) The clinical picture presented by the patient was asymptomatic, which can occur in this type of tumor and contributes to the discovery of the condition late and with a mass that has already evolved very much. However, routine imaging allowed the tumor to be found before it evolved to a substantial size, which occurred in half of the cases. (STRAUSS et al. 2011)

Benign RPTs are approximately four times less frequent than malignant tumors, although they often manifest clinically - which makes the patient's case even more atypical. According to the literature, the highest number of benign RPTs was found in younger patients, as in the case addressed. (SASSA, 2020)

The pathological stage is highly correlated with cancer prognosis, and for an accurate assessment, high-quality cross-sectional imaging plays a key role. When tumor characteristics are not identified by imaging, preoperative histology by core needle biopsy is crucial to establish a definitive diagnosis. (STRAUSS et al. 2011) (NUSSBAUM et al. 2014) (FILHO, 2021) However, in the case reported, the patient had a lesion that was difficult to access, which prevented the performance of a CT-guided biopsy, and, for this reason, the surgical choice was made in this case. (SASSA, 2020) The diagnostic hypothesis was confirmed by IPO excision of a tumor in the retroperitoneum, followed by retroperitoneal lymphadenectomy and omentectomy. With the confirmation of the diagnosis, the medical team can safely proceed to plan an adequate prognosis.

METHODOLOGY

From a medical case that occurred at the Santa Casa da Misericórdia de Presidente Prudente, together with his medical record, information was collected to carry out this case report. In addition, a search for information was carried out in databases.

RESULTS

Benign RPTs are approximately four times less frequent than malignant tumors, which makes the patient's case even more atypical. According to the literature, the highest number of benign RPTs was found in younger patients, as in the case addressed. The pathological stage is highly correlated with cancer prognosis, and for an accurate assessment, high-quality cross-sectional imaging plays a key role. In the case reported here, the patient had a lesion that was difficult to access, which prevented the performance of a CT-guided biopsy, and, for this reason, the surgical choice was made in this case.

CONCLUSION

It is concluded that the success of the prognosis of retroperitoneal tumor is influenced by multiple interrelated factors. The grade of the tumor is of paramount importance as it reflects not only aggressive metastatic behavior but also the higher incidence of local recurrence seen in high-grade sarcomas. In addition, the intrinsic biology of the tumor, together with the extent of the surgical resection performed, plays crucial roles in determining the prognosis and life expectancy of patients. Therefore, detailed imaging and specific laboratory tests are crucial, especially in at-risk populations; and monitoring assistants of a multidisciplinary medical team.



These procedures are critical for initial diagnosis and surgical planning, and accurate implementation of the steps is vital to optimize the chances of recovery.



REFERENCES

1. Choi, J. H., & Ro, J. Y. (2020). Retroperitoneal sarcomas: An update on the diagnostic pathology approach. *Diagnostics, 10*(9), 642.
2. Filho, G. B. (2021). *Bogliolo - Patologia* (10^a ed.). Grupo GEN.
3. Mettlin, C., et al. (1982). Results of the national soft-tissue sarcoma registry. *Journal of Surgical Oncology, 19*(4), 224-227.
4. Moore, K. L., & Daley, A. F. (2014). *Anatomia orientada para a clínica* (7^a ed.). Guanabara Koogan.
5. Nussbaum, D. P., et al. (2014). The effect of neoadjuvant radiation therapy on perioperative outcomes among patients undergoing resection of retroperitoneal sarcomas. *Surgical Oncology, 23*(3), 155-160.
6. Santos, C. E. R., et al. (2005). Estudo da morbimortalidade cirúrgica, da sobrevida e dos fatores prognósticos dos pacientes portadores de sarcomas primários do retroperitônio. *Revista do Colégio Brasileiro de Cirurgiões, 32*(5), 251-255.
7. Santos, C. E. R., et al. (2007). Sarcomas primários do retroperitônio. *Revista Brasileira de Cancerologia, 53*(4), 443-452.
8. Sassa, N. (2020). Retroperitoneal tumors: Review of diagnosis and management. *International Journal of Urology*.
9. Strauss, D. C., Hayes, A. J., & Thomas, J. M. (2011). Retroperitoneal tumors: review of management. *The Annals of The Royal College of Surgeons of England, 93*(4), 275-280.