



Right colectomy for severe and complicated acute appendicitis: A case report

DOI: 10.56238/isevjhv3n4-008

Receipt of originals: 06/11/2024

Acceptance for publication: 07/31/2024

**Helen Brambila Jorge Pareja¹, Eduardo Alves Canedo², Ana Clara Souza Von Ah³,
Guilherme Gomes de Oliveira⁴, Henrico Rodrigues Tavares Godoy⁵, Maria Clara Pereira
Maronesi⁶.**

ABSTRACT

Introduction: Acute appendicitis is an inflammation of the vermiform appendix, a small tubular organ located in the first portion of the large intestine. It can affect people of all ages, but it is most prevalent among young people aged 10 to 20. The diagnosis of acute appendicitis is predominantly clinical. In addition, it is possible to classify appendicitis according to its evolution as complicated or uncomplicated, which allows you to assess the severity of the disease. The standard approach for complicated acute appendicitis is appendectomy. In situations of uncomplicated appendicitis, some studies suggest antibiotic therapy as an alternative to surgical treatment, however, there are controversies in this indication, but it has been gaining strength in the latest guidelines. **Objective:** To demonstrate the importance of the diagnosis of acute appendicitis, as well as its classification, for a better prognosis. **Methods:** From a medical case that occurred at the Santa Casa da Misericórdia de Presidente Prudente, and its medical records, information was collected to carry out this report. **Results:** Appendectomy by videolaparoscopy is associated with a lower rate of mortality, infections, and postoperative complications when compared to open surgery. However, there are cases in which laparotomy is more indicated. It is necessary to evaluate each case individually. **Conclusion:** In most cases, once the patient has clinical findings suggestive of acute appendicitis, he should be referred for immediate appendectomy and should not be submitted to routine imaging tests, thus reducing the time interval between diagnosis and surgical treatment, to avoid greater chances of intraoperative

¹ Master of Science in Health Sciences

University of Western São Paulo

LATTES: 8792800011270177

E-mail: Brambila_hj@hotmail.com

² Graduated in Medicine

Universidad del Pacifico

LATTES: 7988075584280290

E-mail: weacan@gmail.com

³ Medical Graduate

University of Western São Paulo

LATTES: 2765878578490417

E-mail: anavonah@yahoo.com.br

⁴ Graduating from Medicine

University of Western São Paulo

LATTES: 0326267699550789

Email: guilhermegomes8880@gmail.com

⁵ Graduating from Medicine

University of Western São Paulo

LATTES: 1242684848845255

Email: henricog8@hotmail.com

⁶ Medical Graduate

University of Western São Paulo

LATTES: 5734138977436814

Email: mariaclara.maronesi@outlook.com



and postoperative complications.

Keywords: Acute appendicitis, Diagnosis, Treatment, Classification.

INTRODUCTION

Acute appendicitis is an inflammation of the vermiform appendix (formerly called the cecal appendix), a small tubular organ located in the first portion of the large intestine, approximately 2 centimeters below the ileocecal valve, with a length ranging between 2 and 20 centimeters. Generally, the pathology is caused by obstruction of the lumen of the appendix due to hardened stools (fecalites), but it can occur in other ways such as: lymphoid hyperplasia, foreign bodies, intestinal parasites or tumors. The result of luminal obstruction of the appendix leads to luminal hypertension, bacterial proliferation followed by reduced blood flow, ischemia, inflammation, and eventually necrosis and perforation (RODRIGUES et al., 2011) (ALVES et al., 2018) (BENINI et al., 2023).

Acute appendicitis can affect people of all ages, but it is most prevalent among young people aged 10 to 20. Although it is more common in men, women undergo appendectomies twice as often. Statistically, the lifetime risk of developing acute appendicitis is 8.6% for men and 6.9% for women. However, lifetime appendectomy rates are 12% for men and 23% for women. Among patients diagnosed with acute appendicitis, 13% to 20% have appendix perforation. Acute appendicitis is more prevalent in industrialized countries, often associated with low-fiber diets. The incidence of this condition is approximately 48 cases per 10,000 inhabitants per year. In addition, acute appendicitis reaches its highest incidence in the second decade of life, that is, among young people aged 10 to 20 years.

The diagnosis of acute appendicitis is predominantly clinical, and it is essential to carry out an anamnesis and well-done physical examination for an early diagnosis, and thus enable the treatment of the condition. Thus, it is necessary to pay attention to the symptomatology of the disease, being migratory abdominal pain, fever, nausea and/or vomiting. On physical examination, changes such as abdominal distension, palpation mass, and peritonitis may be detected. Some clinical signs are frequently noted in the evaluation of patients with acute appendicitis: Blumberg's sign, Rovsing's sign, Lenander's sign, Aaron's sign, Iliopsoas' sign, Lapinsky's sign, Obturator sign. In addition to the physical examination, anamnesis and imaging exam, there are other ways that help in the diagnosis, such as the scores: AAS (Adult Appendicitis Score), RIPASA, Air and Alvarado. Currently, the score with the highest sensitivity



and specificity is the ASA, which requires laboratory tests such as Leukogram and C-Reactive Protein for scoring. In doubtful cases, it is necessary to use imaging tests such as: Ultrasound (USG), Computed Tomography (CT) and Magnetic Resonance Imaging (MRI) (RODRIGUES et al., 2011) (ALVES et al., 2018) (BENINI et al., 2023).

In addition, it is possible to classify appendicitis according to its evolution as complicated or uncomplicated, which allows the severity and prognosis of the disease to be assessed, and allows the development of therapeutic protocols. Complicated appendicitis often shows signs of necrosis that can later lead to perforation, abscesses, and consequently peritonitis. While the uncomplicated one presents only edema and hyperemia, with no signs of necrosis, mass formation or perforations. It is important to pay attention to differential diagnoses related to acute appendicitis, such as cecal diverticulitis, Meckel's diverticulitis, Crohn's disease, ovarian abscess, pelvic inflammatory disease, among others (BENINI et al., 2023).

The standard approach for complicated acute appendicitis is appendectomy. Appendectomy, surgery to remove the cecal appendix in cases of inflammation or infection, is the most performed emergency surgery in the world. This can be performed conventionally, or laparoscopically, which is less invasive. In situations of uncomplicated appendicitis, those in which there is only hyperemia and edema, or fibrinous exudate, some studies suggest antibiotic therapy as an alternative to surgical treatment, aimed at treating gram-negative and anaerobic bacteria, however, there are controversies in this indication, but it has been gaining strength in the latest guidelines. The American Society of Gastrointestinal and Endoscopic Surgeons determines that the gold standard treatment for acute appendicitis is surgery (COELHO et al., 2010) (MOREIRA et al., 2018).

Possible postoperative complications should be taken into account according to the clinical conditions of each patient and also the possible consequences of non-surgery. Among the surgical complications, the most common of them is wound infection, and its incidence depends on the stage of appendicitis, the age and physiological condition of the patient, and the type of surgery (laparoscopic or open). On the other hand, one of the complications for acute appendicitis that is not diagnosed and treated in a timely manner is the progression to complicated appendicitis (COELHO et al., 2010) (MOREIRA et al., 2018).

In most cases, since the patient has clinical findings suggestive of acute appendicitis and these findings do not require complementary tests, the patient should be referred for immediate appendectomy and should not be submitted to routine imaging tests, such as ultrasounds and computed tomography, since they are time-consuming and expensive, increasing the time

interval between diagnosis and surgical treatment. culminating in higher chances of intraoperative and postoperative complications (COELHO et al., 2010).

CASE DESCRIPTION

Patient L.C.S., male, 19 years old, with severe pain in the abdomen that resembled gas. He sought medical attention to perform a routine ultrasound where he was diagnosed with appendicitis. Soon after, he was referred to a tertiary hospital to be admitted and undergo other imaging tests. Abdominal tomography was performed, where appendicitis was evidenced, with signs of mass effect in the cecum region. A surgical approach was indicated for the patient where the initial objective was to perform a videolaparoscopy. Once the procedure was initiated, and the cavity inventory showed a friable mass that invaded the region of the base of the appendix and cecum with macroscopic characteristics suggestive of a local invasive tumor. Opted for open surgical conversion. Tiflectomy was performed and the surgery was uneventful. The patient was discharged from the hospital on the fourth postoperative day, and continued with a favorable recovery months after the approach. Grade IV appendicitis was confirmed perforated and blocked by anatomopathological examination.

Figure 1: Appendix with increased caliber, presenting thickening and diffuse parietal enhancement, associated with densification of the adjacent adipose planes.

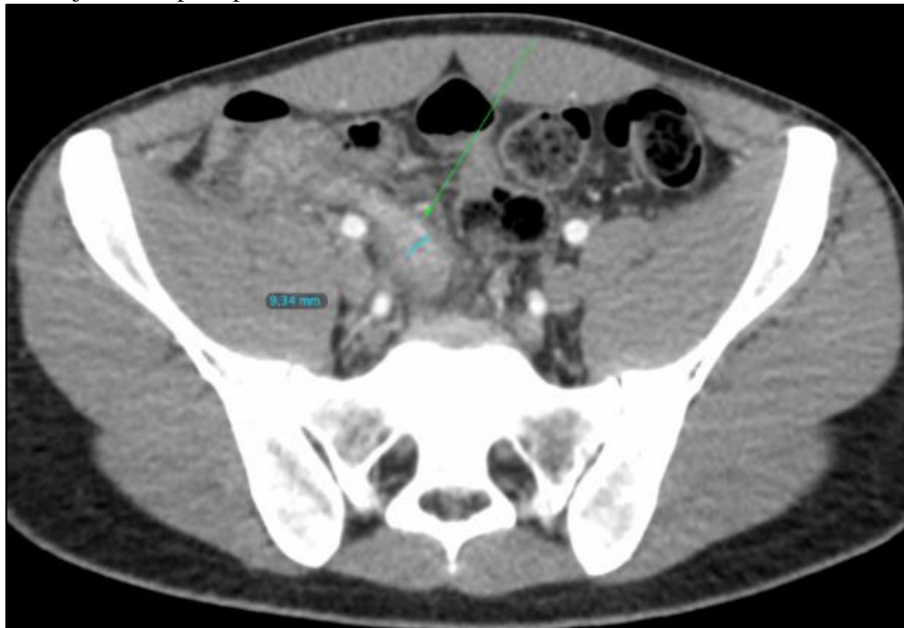


Figure 2: Appendicolith at the tip.

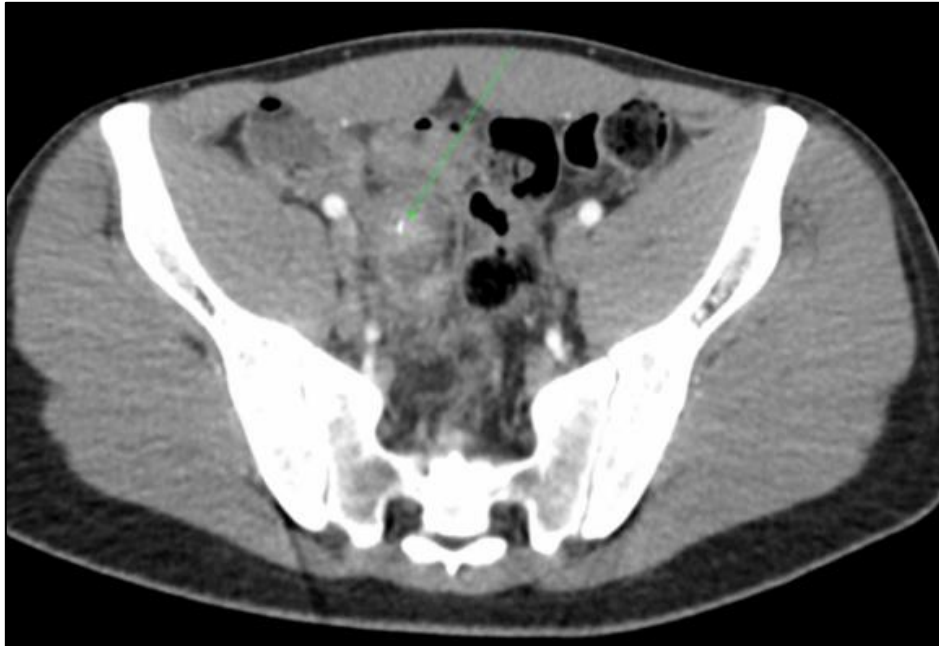
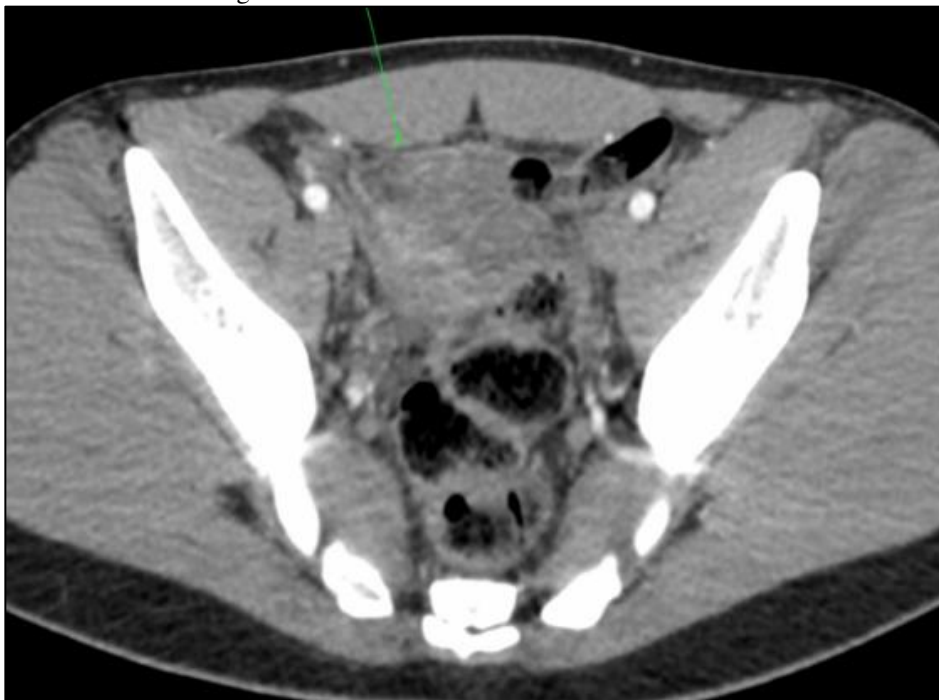
Figure 3: In addition, there is peritoneal thickening (peritonitis), which also speaks in favor of a possible perforation. But it does not have well-defined organized collections for examination.



CASE DISCUSSION

In the face of acute appendicitis, some patients may present atypical and nonspecific characteristics such as indigestion, flatulence, fever, intestinal irregularity (especially diarrhea) and a drop in general condition. Thus, the help of imaging tests is necessary for the definitive diagnosis. Diagnostic imaging methods, such as abdominal USG, CT, or MRI, can be used to confirm the diagnosis, aiding in the analysis of appendix characteristics, such as thickness,



inflammation, presence of characteristic free fluid, wall ischemia, diameter, and appendicular perforation.

USG is usually the first choice for screening patients with acute abdominal pain, as well as the patient in the case, as it is cost-effective and reduces radiation exposure. CT is also frequently used and more specific than USG.

A study conducted in Brazil shows that from the onset of clinical manifestations of acute appendicitis, the time interval until appendectomy is directly associated with the evolution to complicated appendicitis, i.e., the longer the time interval between symptoms and surgical treatment, the chances of complicated appendicitis increase, in addition to other undesired consequences such as postoperative complications and longer hospital stay (COELHO et al., 2010).

Thus, the patient in the case, as soon as the diagnosis was confirmed, was promptly referred for surgery, initially appendectomy by videolaparoscopy, but when a friable mass was detected in the cecal appendix, open surgery was chosen, and tiflectomy (removal of the cecum) was performed. Thus, it is understood that appendectomy is the standard approach for appendicitis, but in situations that do not allow appendectomy such as edema and intense inflammatory process of the base of the appendix and cecum, presence of masses with deformation of anatomical structures, tyflectomy or even right colectomy is necessary.

According to CBC (2016), the evolutionary phases of appendicitis were classified from 0 to IV, with phase 0 corresponding to the normal appendix, I appendix with hyperemia and edema, II appendix with fibrinous exudate, III appendix with necrosis and abscess, and phase IV perforated appendicitis. In this case, the patient already had severe appendicitis, grade IV perforated and blocked.

Data from a study show that the most frequent evolutionary phase among cases of appendicitis is grade II (34.3%); and that of the patients diagnosed in phase IV, the majority were men (65.8%). In the same study, the length of hospital stay was evaluated, which brought as an average length of stay in both men and women, of 7 days, however, in cases of perforated appendicitis, the mean length of stay was 12.4 days. From this, it can be remembered that the length of hospital stay and postoperative complications are directly related. The patient in the case was discharged 4 days after the operation, which can be associated, along with other pre, intra and postoperative care, with his smooth recovery (IAMARINO et al., 2017).

The patient in the case is a young patient, 19 years old, and this already shows a lower risk of postoperative complications, since age is a risk factor from the prognosis of appendicitis



to the postoperative period. One study sought to evaluate the main risk factors for postoperative complications in patients undergoing appendectomy. This included as some predictor factors such as gender, age, type of surgical access performed, type of appendicitis (complicated or uncomplicated), surgical time in minutes, duration of hospital stay in days, and occurrence or absence of postoperative complications (MOREIRA et al., 2018).

Thus, it was found that age over 38.5 years is predictive of postoperative complications, the laparoscopic approach is associated with a lower number of complications, while the conventional (or open) approach is associated with a greater number. As expected, complicated appendicitis increases the risk of postoperative complications, and the surgical time and postoperative hospitalization have a proportional relationship with the degree of complications (MOREIRA et al. 2018).

The age factor is explained by the greater number of comorbidities over 39 years of age compared to a younger individual, in addition to appendicitis manifesting itself atypically in patients in this age group, leading to a later diagnosis that influences the type of appendicitis at the time of surgery and the evolution to complicated appendicitis. Although the laparoscopic route has a recovery with fewer complications, when they occur they tend to be more severe. In addition, in relation to the time of surgery and hospitalization, duration of more than 77 minutes should be considered for prevention and treatment of future complications, as well as paying attention to long hospitalization times, which is associated with the evolutionary phase of appendicitis, which results in more serious complications (MOREIRA et al., 2018).

Delving deeper into the relationship between complications and the phase of appendicitis, another study, which subdivided appendectomized patients into two groups, one with complications and the other without, showed that complications in patients undergoing appendectomy are related to the phase in which the disease is diagnosed and treated. Corroborating these data, almost half of the patients belonging to the group with complications had a perforated appendix (45%), characterizing complicated appendicitis, while in the group without complications, phlegmonous appendicitis predominated (38%), which is uncomplicated (IAMARINO et al., 2017).

Regarding the surgery technique used, at first from the imaging exams, a videolaparoscopy was indicated and initiated, however, when a friable mass was found in the cecal appendix, the technique was quickly changed to an open surgery. Regarding the first choice, it is known that appendectomy by videolaparoscopy is associated with a lower rate of mortality, infections, postoperative complications, and shorter hospital stay, when compared to



the open surgery technique. However, there are cases in which laparotomy (open surgery) is more indicated, with a conversion rate from laparoscopic appendectomy to open appendectomy ranging from 9 to 12%. It is necessary to evaluate the predictors so that there is no loss of time in the operating room in these conversions, as was the case with the patient in question (CHERIF et al., 2023).

A study that evaluated the predictors of conversion from laparoscopic appendectomy to open appendectomy, through computed tomography findings, showed that the presence of significant fat, free fluid or free air, abscess formation, and grade 4 to 5 appendicitis increase the possibility of conversion. In the intraoperative period, in addition to the difficult dissection associated with a severe acute inflammatory process (69.4%), there is also a perforated appendix (36.36%) and a retrocecal appendix (36.36). Other reasons reported were: difficulty in identifying the appendix, uncontrolled bleeding, impossibility of maintaining adequate pneumoperitoneum, and hypotension due to the Trendelenburg position (CHERIF et al., 2023).

METHODOLOGY

From a medical case that occurred at the Santa Casa da Misericórdia de Presidente Prudente, together with his medical record, information was collected to carry out this case report. In addition, a search for information was carried out in databases.

RESULTS

Appendectomy by videolaparoscopy is associated with a lower rate of mortality, infections, and postoperative complications when compared to open surgery. However, there are cases in which laparotomy (open surgery) is more indicated. It is necessary to evaluate each case individually.

CONCLUSION

In most cases, since the patient has clinical findings suggestive of acute appendicitis and these findings do not require complementary tests, the patient should be referred for immediate appendectomy and should not be submitted to routine imaging tests, thus reducing the time interval between diagnosis and surgical treatment, in order to avoid greater chances of intraoperative and postoperative complications.



REFERENCES

- Alves, B. / O. / O.-M. (2018). Apendicite. Biblioteca Virtual em Saúde MS. Retrieved from <https://bvsmms.saude.gov.br/apendicite/>
- Benini, R. L. D. P., et al. (2023). Apendicite aguda complicada e não complicada - Uma revisão abrangente sobre a fisiopatologia, manifestações clínicas, microbiota intestinal e sua relevância, diagnóstico clínico, diagnóstico imagiológico, tratamento, prognóstico e perspectivas futuras. *Brazilian Journal of Health Review*, 6(4), 19233–19250. <https://doi.org/10.34119/bjhrv6n4-084>
- Bom, W. J., et al. (2021). Diagnosis of uncomplicated and complicated appendicitis in adults. *Scandinavian Journal of Surgery*, 110(2), 170-179. <https://doi.org/10.1177/14574969211007822>
- Bramblia, H., et al. (2023). Apendicite aguda complicada tratada com Tiflectomia: Relato de caso. *Brazilian Journal of Development*, 9(4), 12770–12780. <https://doi.org/10.34117/bjdv9n4-067>
- Cherif, M., et al. (2023). Laparoscopic appendectomy: Risk factors for conversion to laparotomy. *ABCD. Arquivos Brasileiros de Cirurgia Digestiva*, 36. <https://doi.org/10.5935/1678-4408.20230013>
- Coelho, U., et al. (2010). Appendectomy: Comparative study between a public and a private hospital. *Revista da Associação Médica Brasileira*, 56(5), 522–527. <https://doi.org/10.1590/S0104-42302010000500012>
- Gomes, C. A., & Nunes, T. A. (2006). Classificação laparoscópica da apendicite aguda: Correlação entre graus da doença e as variáveis perioperatórias. *Revista do Colégio Brasileiro de Cirurgiões*, 33(5), 289–293. <https://doi.org/10.1590/S0100-69912006000500007>
- Gustavo, L., et al. (2023). Apendicite aguda: Aspectos etiopatogênicos, métodos diagnósticos e a apendicectomia videolaparoscópica como manejo. *Brazilian Journal of Development*, 9(3), 9639–9652. <https://doi.org/10.34117/bjdv9n3-072>
- Iamarino, A. P. M., et al. (2017). Risk factors associated with complications of acute appendicitis. *Revista do Colégio Brasileiro de Cirurgiões*, 44(6), 560–566. <https://doi.org/10.1590/0100-69912017006008>
- Monteiro, P. (2017). Perfil clínico-epidemiológico dos pacientes operados de apendicite aguda no Hospital Universitário Cassiano Antonio Moraes de 2009 a 2016. [Monografia, Universidade Federal do Espírito Santo]. Retrieved from <https://repositorio.ufes.br/handle/10/100>
- Moreira, L. F., et al. (2018). Fatores preditores de complicações pós-operatórias em apendicectomias. *Revista do Colégio Brasileiro de Cirurgiões*, 45(5). <https://doi.org/10.1590/0100-69912018005009>



- Moris, D., Paulson, E. K., & Pappas, T. N. (2021). Diagnosis and management of acute appendicitis in adults: A review. *JAMA*, 326(22), 2299–2311. <https://doi.org/10.1001/jama.2021.22235>
- Freitas, E. L. de, & Mizuno, V. I. (2019). Perfil clínico-epidemiológico da apendicite aguda no Brasil: Uma revisão sistemática. [Dissertation, Universidade Federal de Sergipe]. Retrieved from <https://www.ufes.br/repository>
- Nascimento, J. H. F. D., et al. (2021). Comparison of outcomes and cost-effectiveness of laparoscopic and open appendectomies in public health services. *Revista do Colégio Brasileiro de Cirurgiões*, 48. <https://doi.org/10.1590/0100-699120210048>
- Perri, L. M. de M., et al. (2022). Apendicite aguda: Aspectos gerais acerca da abordagem diagnóstica e cirúrgica. *Brazilian Journal of Development*, 8(5), 34245–34256. <https://doi.org/10.34117/bjdv8n5-045>
- Petroianu, A. (2007). Imagem radiográfica de acúmulo fecal no ceco, como sinal diagnóstico de apendicite aguda. *Radiologia Brasileira*, 40(4), 239–240. <https://doi.org/10.1590/S0100-39842007000400009>
- Rodrigues, E., et al. (2011). Artigo de revisão: Apendicite aguda. *Revista Médica de Minas Gerais*, 21(2), 1–113. Retrieved from <https://www.rmmg.org/exportar-pdf/889/v21n2s4a09.pdf>