



Gallbladder empyema with perforation: A case report

DOI: 10.56238/isevjhv3n4-009

Receipt of originals: 06/11/2024

Acceptance for publication: 07/31/2024

**Helen Brambila Jorge Pareja¹, Gersio Cayres Pinheiro Neto², Maria Julia Elias de Freitas³,
Tiago Lyria da Silva Azinato⁴, Manuela Minatti Fernandez da Cruz⁵.**

ABSTRACT

Introduction: Acute cholecystitis (AC) is an inflammation of the gallbladder often caused by obstruction of the cystic duct by gallstones, responsible for 90-95% of cases. Complications include gangrene, gallbladder perforation, and empyema, which occurs in 6.3-26.6% of complicated cases and can progress to sepsis if not treated promptly. Empyema of the gallbladder is more common in men and the elderly, especially with comorbidities. Symptoms include right upper quadrant pain, fever, and nausea. Diagnosis involves ultrasound, computed tomography, and laboratory tests. Immediate treatment with antibiotics and removal or drainage of the gallbladder. Laparoscopic surgery is preferred. **Objective:** To demonstrate the importance of diagnosis and appropriate treatment of empyema **Methods:** From a medical case that occurred at the Santa Casa da Misericórdia de Presidente Prudente, and its medical records, information was collected to carry out this report. **Results:** Gallbladder empyema presents symptoms such as acute pain in the right upper quadrant, fever, nausea, radiation of pain to the back and shoulder, and positive Murphy's sign. With the worsening, high fever, chills and signs of sepsis appear. In the case reported here, the patient was afebrile, making it difficult to diagnose empyema. A laparoscopic cholecystectomy, the standard of care for gallstones, was performed. **Conclusion:** Prompt treatment with parenteral antibiotics and urgent gallbladder removal or drainage is essential to prevent serious complications and death. Laparoscopic cholecystectomy is the standard of care, offering advantages such as reduction and lower medical cost.

Palavras-chave: Gallbladder empyema, Acute cholecystite, Laparoscopic cholecystectomy.

¹ Master of Science in Health Sciences

University of Western São Paulo

ID Lattes: 8792800011270177

E-mail: Brambila_hj@hotmail.com

² Graduated in Medicine

University of Western São Paulo

ID Lattes: 5123791080690605

Email: gersio_cayres@hotmail.com

³ Medical Graduate

University of Western São Paulo

ID Lattes: 4745977853913211

E-mail: majueliasf@gmail.com

⁴ Graduating from Medicine

University of Western São Paulo

ID Lattes: 9868197015991108

Email: tiagolyria23@gmail.com

⁵ Medical Graduate

University of Western São Paulo

ID Lattes: 4973696998271949

Email: minatti.manu@hotmail.com



INTRODUCTION

Acute cholecystitis (AC) is one of the most common surgical entities seen in the emergency department, it is an acute inflammatory disease caused after obstruction of the cystic duct by gallstones (ORTIZ-HERNÁNDEZ et al. 2022), responsible for 90% to 95% of cases of AC (GALLAHER and CHARLES 2022), or lithogenic bile. Complications of AC, such as gangrene, gallbladder perforation, and emphysematous AC, may occur in 7.2–26% of patients with AC (NASSAR et al. 2022); and empyema of the gallbladder that can progress to sepsis if not treated immediately (ELKIBULI et al. 2020), resulting in organ dysfunction and need for organ support, as a possible consequence of severe disease (NASSAR et al. 2022).

Gallbladder empyema accounts for 6.3–26.6% of complicated AC, with a mortality rate of nearly 3%. It is associated with calculus cholecystitis, where there is obstruction of the cystic duct and bile stasis. Stagnant bile in the gallbladder presents with superinfection with microorganisms leading to suppuration in a gallbladder with acute inflammation (KASHYAP et al. 2023). The most frequent etiologic agents are Gram-negative enteropathogens: *Escherichia coli*, *Klebsiella* spp., and *Streptococcus faecalis*. However, other pathogens can affect the gallbladder and cause complications (ORTIZ-HERNÁNDEZ et al. 2022). Gallbladder empyema is a more morbid condition when it occurs in the older age group, and there is a greater preponderance of men who develop this disease. Patients at increased risk of AC, such as those with associated diabetes, immunosuppressive therapy, or hemoglobinopathies, are more likely to develop gallbladder empyema. Mortality is rare, except in patients with advanced age, compromised immunity, or significant comorbidities (KASHYAP et al. 2023) and in cases of progression to septicemia.

The formation of pus follows this infection, firmly filling the lumen of the gallbladder. In a strained and swollen gallbladder, wall necrosis and perforation may occur if drainage or removal of the gallbladder is not performed immediately. Untreated, or late-treated patients may develop generalized sepsis or gallbladder gangrene, resulting in gallbladder perforation. Rarely, a fistula between the gallbladder and other organs may occur as a complication of gallbladder empyema. On anatomopathological examination, the gallbladder wall may be externally covered by a fibrinous exudate, and purulent secretion in the gallbladder lumen. In culture, this pus may not always develop if the patient is on antibiotic therapy. Microscopic examination of the mucosa may reveal ulceration and evidence of inflammation. There may be associated mucosal hemorrhage (KASHYAP et al. 2023).



This pathology usually presents with signs and symptoms (MURTAZA KHOMUSI et al. 2022), such as acute pain in the right upper quadrant, fever and nausea that may be associated with eating (GALLAHER and CHARLES 2022), irradiation of pain to the back and tip of the shoulder (MURTAZA KHOMUSI et al. 2022), positive Murphy's sign; and with the worsening of the disease, high fever, chills and signs of systemic sepsis occur. Often, the patient has an elevated Gamma Glutamyl Transferase count, alkaline phosphatase, and white blood cells, indicating an underlying infectious cause. Liver and kidney function tests, coagulation profile, and complete blood count should also be obtained (KASHYAP et al. 2023).

Right upper quadrant ultrasound has a sensitivity of approximately 81% and a specificity of approximately 83% for acute cholecystitis (GALLAHER and CHARLES 2022), but it is not diagnostic, but may raise the suspicion of empyema when there is a very swollen gallbladder or when there is echogenic content in the gallbladder associated with gallstones. A CT scan may be useful when an ultrasound does not help, as it may reveal an enlarged or distended gallbladder with edematous walls and sometimes pericholecystic collection. When the diagnosis is more difficult, an MRI can help, including in the differential diagnosis of a Mirizzi syndrome or choledocholithiasis. The other relevant investigations are liver enzyme levels and PT (prothrombin time) and aPTT (activated partial thromboplastin time). Radiological findings alone may be insufficient for an accurate diagnosis of gallbladder empyema. A combination of clinical, radiological, and laboratory findings is crucial to arrive at a correct final diagnosis of gallbladder empyema (KASHYAP et al. 2023).

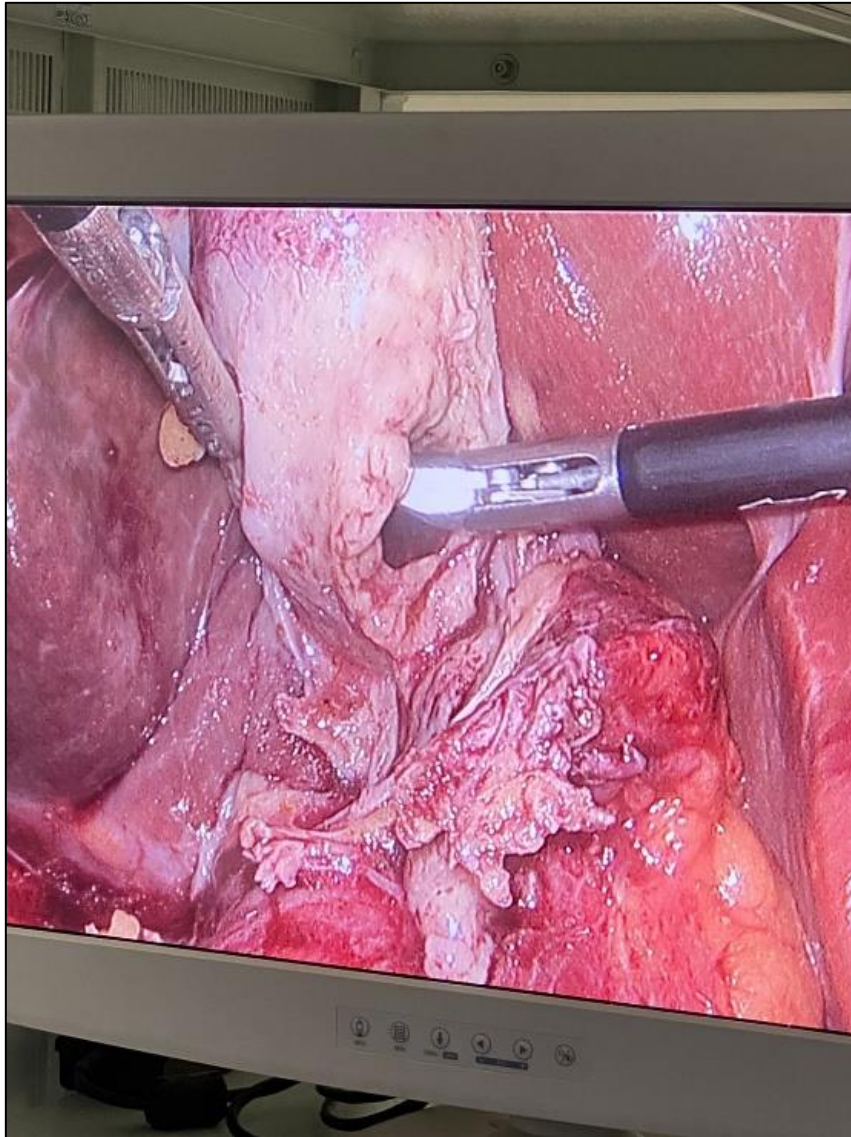
Prompt treatment with parenteral antibiotics, along with urgent removal or drainage of the gallbladder, is essential to prevent serious complications and even death. It is crucial to administer a broad-spectrum antibiotic, ensure hydration, and prepare the patient for surgery as soon as possible. Although the conventional approach is open cholecystectomy, experienced surgeons can perform laparoscopic gallbladder removal. However, it is important for surgeons to be prepared to convert to open surgery if they encounter technical difficulties. Conversion to open surgery is more common in cases of gallbladder empyema due to reduced visibility and increased bleeding due to inflammation. Initial decompression of the distended gallbladder, whether guided by radiology or laparoscopy, facilitates dissection during surgery. The rates of postoperative complications, such as wound infection, bleeding, and bile duct injuries, are higher compared to cases of cholecystitis due to gallstones. In elderly patients or those with severe comorbidities, temporary radiology-guided drainage may be performed prior to surgery. This can

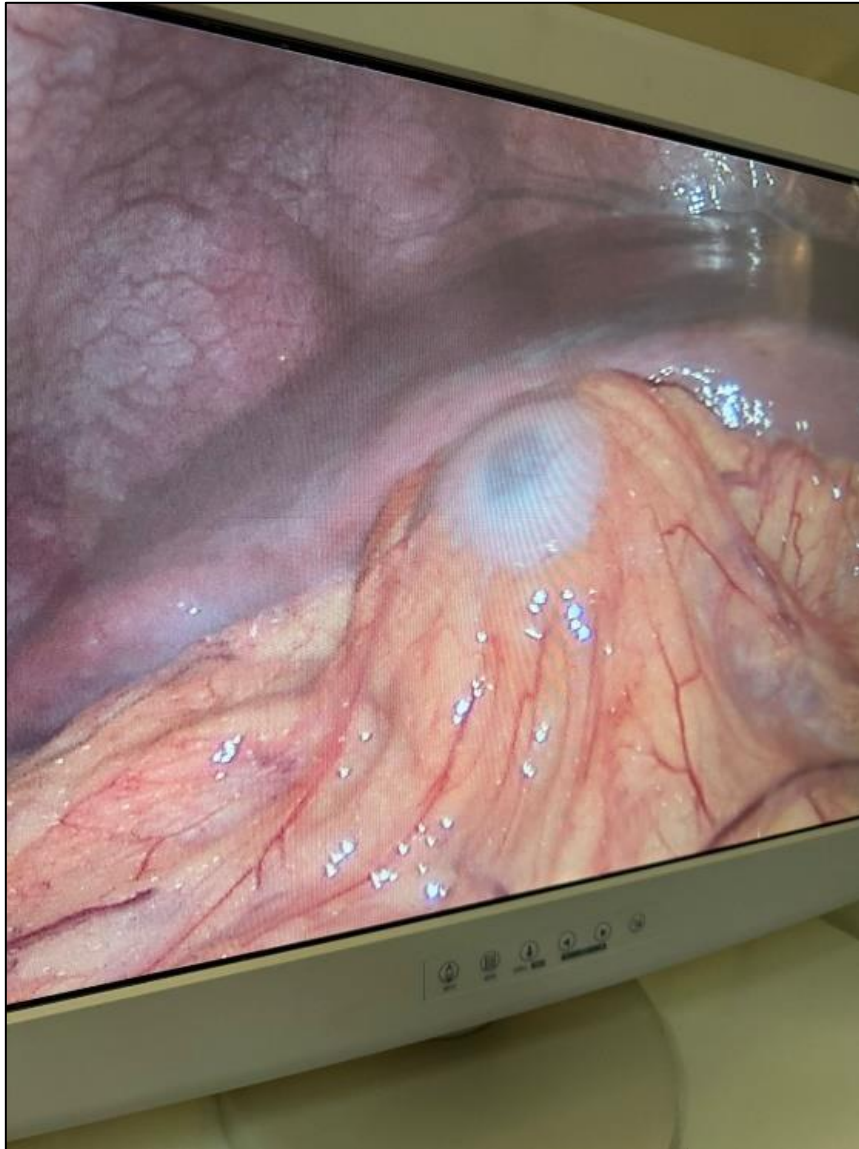


lead to an improvement in the patient's condition, allowing for elective surgery later. Antibiotic therapy is usually maintained until fever subsides (KASHYAP et al. 2023).

CASE DESCRIPTION

Patient M.G.G.T., female, 75 years old, hypertensive. She sought outpatient care due to severe pain in the right hypochondrium that began \pm 5 days ago, which radiated to the back associated with nausea. She reported that the pain began and intensified after the ingestion of fatty foods. He denies fever, vomiting and mitigating factors. He had a previous test diagnosing cholelithiasis. The patient had stable vital signs; He showed no signs of shock and sepsis. Abdominal physical examination showed pain in the right hypochondrium and positive Murphy's sign. Antibiotic therapy was performed on the patient, who underwent surgery on the 10th day, due to her good clinical condition. The surgery performed was an uneventful laparoscopic cholecystectomy. Intraoperatively, a thick vesicle with perforation and pus exit, characterizing a gallbladder empyema, was observed. The patient received a diet on the same day, and was discharged from the hospital the next day to complement clinical treatment with antibiotic therapy at home. The patient had an outpatient return in 15 days and had stable visual signs, with a significant postoperative improvement.





DISCUSSION

Gallbladder empyema is associated with calculus cholecystitis, where there is cystic duct obstruction and bile stasis (KASHYAP et al. 2023). The patient's clinical history showed the presence of cholelithiasis, and her clinical picture was severe pain in the right hypochondrium associated with nausea with onset \pm 5 days, having started and intensified after the ingestion of fatty foods, which can occur in this type of pathology and contributes to the discovery of this condition. However, empyema can progress to sepsis if not treated immediately (ELKBULI et al. 2020).

Gallbladder empyema is a more morbid condition when it occurs in the older age group, and there is a greater preponderance of men who develop this disease. Patients at increased risk of AC, such as those with associated diabetes, immunosuppressive therapy, or



hemoglobinopathies, are more likely to develop gallbladder empyema. Mortality is rare, except in patients with advanced age, compromised immunity or significant comorbidities, in which case the patient had two aggravating factors: advanced age 75 years and being hypertensive.

(KASHYAP et al. 2023)

Prompt treatment with parenteral antibiotics, along with urgent removal or drainage of the gallbladder, is essential to prevent serious complications and even death. It is crucial to administer a broad-spectrum antibiotic, ensure hydration, and prepare the patient for surgery as soon as possible. Although the conventional approach is open cholecystectomy, experienced surgeons can perform laparoscopic gallbladder removal. Antibiotic therapy is usually maintained until fever subsides (KASHYAP et al. 2023). However, in the case reported, the patient was afebrile, which made the primary diagnosis of empyema difficult, for this reason, a laparoscopic cholecystectomy was performed, Laparoscopic cholecystectomy is considered the standard of care for the treatment of gallstones. The success of this technique is due to the demonstrated reduction in postoperative pain and length of hospital stay, rapid recovery, minimal scarring, and overall reduction in medical costs (PATEL et al. 2022). The diagnosis of empyema was confirmed by videolaparoscopy, followed by a cholecystectomy. With this procedure, the patient had her symptoms resolved and was discharged from the hospital 1 day after the surgical procedure.

METHODOLOGY

From a medical case that occurred at the Santa Casa da Misericórdia de Presidente Prudente, together with his medical record, information was collected to carry out this case report. In addition, a search for information was carried out in databases.

RESULTS

Gallbladder empyema accounts for 6.3–26.6% of complicated AC, with a mortality rate of nearly 3%. It is associated with calculus cholecystitis, where there is obstruction of the cystic duct and bile stasis. On anatomopathological examination, the gallbladder wall may be externally covered by a fibrinous exudate, and purulent secretion in the gallbladder lumen. This pathology usually presents with signs and symptoms, such as sharp pain in the right upper quadrant, fever and nausea that may be associated with feeding, radiating pain to the back and tip of the shoulder, positive Murphy's sign; and with the worsening of the disease, high fever, chills and signs of systemic sepsis occur. In the case reported, the patient was afebrile, which made the



primary diagnosis of empyema difficult, for this reason, a laparoscopic cholecystectomy was performed.

CONCLUSION

It is concluded that immediate treatment with parenteral antibiotics, along with urgent removal or drainage of the gallbladder, is essential to avoid serious complications and even death. It is crucial to prepare the patient for surgery as soon as possible, and opt for laparoscopic cholecystectomy considered the standard of care. The success of this technique is due to the demonstrated reduction in postoperative pain and length of hospital stay, rapid recovery, minimal scarring, and overall reduction in medical costs.



REFERENCES

- Elkbuli, A., et al. (2020). Uncommon presentation of severe empyema of the gallbladder: Case report and literature review. *The American Journal of Case Reports*, 21, 1-7. <https://doi.org/10.12659/AJCR.926852>
- Gallagher, J. R., & Charles, A. (2022). Acute cholecystitis: A review. *JAMA: The Journal of the American Medical Association*, 327(10), 965-973. <https://doi.org/10.1001/jama.2022.1306>
- Kashyap, S., Mathew, G., & King, K. C. (2023). Gallbladder empyema. In *StatPearls*. StatPearls Publishing. <https://www.ncbi.nlm.nih.gov/books/NBK565887/>
- Murtaza Khomusi, M., et al. (2022). Prevalence of empyema or mucocele or other histological diagnoses in patients undergoing cholecystectomy with diagnosis of chronic cholecystitis. *Cureus*, 14(7), e27225. <https://doi.org/10.7759/cureus.27225>
- Nassar, A., et al. (2022). Outcome of early cholecystectomy compared to percutaneous drainage of gallbladder and delayed cholecystectomy for patients with acute cholecystitis: Systematic review and meta-analysis. *HPB: The Official Journal of the International Hepato Pancreato Biliary Association*, 24(10), 1622-1633. <https://doi.org/10.1016/j.hpb.2022.05.010>
- Ortiz-Hernández, A., et al. (2022). Acute cholecystitis complicated with gallbladder empyema due to *Mycobacterium tuberculosis* in a patient with diabetes mellitus: A case report. *Therapeutic Advances in Infectious Disease*, 9, 204993612211291. <https://doi.org/10.1177/20499361221129142>
- Patel, N., et al. (2022). Imagem multimodal de complicações de colecistectomia. *Radiographics: A Review Publication of the Radiological Society of North America, Inc*, 42(5), 1303-1319. <https://doi.org/10.1148/rg.2022210095>