



Laparoscopy for IUD removal in the abdominal cavity: A case report

DOI: 10.56238/isevjhv3n4-012

Receipt of originals: 06/11/2024

Acceptance for publication: 07/31/2024

**Helen Brambila Jorge Pareja¹, Michaela Helena Moretto Alves², Isadora Nascimento³,
Julia Abrão Pierin Peres⁴, Maria Luiza Cardoso Silva⁵, Maria Luiza Rigolin Moyses⁶.**

ABSTRACT

Introduction: The intrauterine device (IUD) is the most widely used reversible female contraceptive method in the world today. Among the most common complications include, for example, gynecological infections, uterine bleeding, dyspareunia. A rare and serious complication is IUD migration or uterine perforation. The main risk factors for IUD migration suggested are insertion by an inexperienced operator, extremely ante- or retroverted uteruses, insertion in the immediate postpartum period, or breastfeeding. Regarding treatment, laparoscopy offers a safe and easy surgical procedure to locate and remove the IUD. **Objective:** To demonstrate the importance of follow-up examinations after IUD implantation in order to avoid future complications. **Methods:** From a medical case that occurred at the Santa Casa da Misericórdia de Presidente Prudente, and its medical records, information was collected to carry out this report. **Results:** The IUD is considered a practical, low-cost, and long-acting method of contraception. However, when rare complications occur, the surgical method is the best option for resolution, and videolaparoscopy is used, as reported in the literature. It is important to carry out tests to monitor the patient after IUD implantation, thus avoiding future complications. **Conclusion:** Uterine perforation and IUD migration to another region outside the uterine cavity occur most commonly during device insertion. It would be possible to have a fast and effective treatment, performed through laparoscopy, both in asymptomatic and symptomatic patients, such a method has advantages such as less pain and better recovery time.

¹ Master of Science in Health Sciences
University of Western São Paulo
ID Lattes: 8792800011270177

E-mail: brambila_hj@hotmail.com

² Graduated in Medicine

Aparício Carvalho University Center

ID Lattes: 5279549743262168

E-mail: michaela.helena1@hotmail.com

³ Medical Student

University of Western São Paulo

ID Lattes: 278163493490

E-mail: isanasci785@gmail.com

⁴ Medical Student

University of Western São Paulo

ID Lattes: 7256433254641075

E-mail: juliapierinperes@gmail.com

⁵ Medical Student

University of Western São Paulo

ID Lattes: 2351075881471855

E-mail: malu090802@gmail.com

⁶ Medical Student

University of Western São Paulo

ID Lattes: 7023384452385589

E-mail: maria.luiza.rigolin.moyeses@gmail.com



Keywords: Intrauterine device, Complications, Treatment.

INTRODUCTION

The intrauterine device (IUD) is the most widely used reversible female contraceptive method in the world today, being the second most used way to carry out family planning, after surgical sterilization (PAULO et al. 2019). According to some authors, the intrauterine device (IUD) containing levonorgestrel, known as Mirena, presents better results compared to those containing copper, in terms of lower risk of complications, discontinuation of use, and ineffectiveness. In addition, the use of Mirena significantly reduces endometrial cancer rates, so it is used to prevent endometrial cancer in high-risk patients and is also a therapeutic option when there is an intention to preserve the patient's reproductive potential or in cases of surgical contraindication. The IUD has failure rates of less than 1 per 100 women, and is considered a very effective method for birth control (PAULO et al. 2019). Despite being widely used, the IUD is not without complications. Among the most common complications include gynecological infections, uterine bleeding, dyspareunia, irregular menstrual cycle, and excessive menstruation (MAKARY and RATHORE, 2021). A rare and serious complication of IUD insertion is IUD migration or uterine perforation (PAULO et al. 2019) (MORAES et al. 2015).

Uterine perforation, with the IUD leaving the uterine cavity and migrating to another region, is the most common cause of IUD loss and is associated with high morbidity and mortality (ARAGÃO et al. 2022). Uterine perforation rates are 0.3 to 2.6 per 1000 insertions for intrauterine levonorgestrel delivery systems (LNG-IUS) and 0.3 to 2.2 for copper IUDs (LINHARES et al. 2021). Once in the abdominal cavity, the IUD can compromise several neighboring organs, such as the bladder, small intestine, sigmoid rectum, and vermiform appendix. It has been shown to be rare for the IUD to have left the initial position, traveled through one of the tubes and lodged in a place other than a hollow organ.

This complication is mainly associated with iatrogenic perforation during insertion, uterine abnormalities, and/or normal peristaltic activity of the uterus. Perforations can occur during or after insertions. IUD misplacement usually occurs at the time of insertion and is detected during the first year in 90% of women (ARAGÃO et al. 2022). The main risk factors for IUD migration suggested are insertion by an inexperienced operator, extremely ante- or retroverted uteruses, insertion in the immediate postpartum or breastfeeding, leading to damage to the uterine wall (PAULO et al. 2019) (MAKARY and RATHORE, 2021). Inside the



peritoneal cavity, the IUD can cause fibrosis formation, abdominal pain, infertility, intestinal obstruction, and perforation of neighboring organs.

Regarding the clinical manifestations, the clinical presentation of uterine perforation is quite variable. It can present from the asymptomatic form to abdominal pain, abnormal bleeding, fistula formation, bladder and intestinal perforation (PAULO et al. 2019). Within the peritoneal cavity, the IUD can cause fibrosis formation, abdominal pain, infertility, intestinal obstruction and perforation to neighboring organs, such as the bladder and rectosigmoid (COELHO et al. 2003) (MORAES et al. 2015). The symptomatology will depend only on the place where the IUD was fixed (MORAES et al. 2015). However, there are reported cases in which there were no complications, as the uterine cavity is directly connected to the peritoneal cavity, considering that each fallopian tube approaches the corresponding ovary, allowing the device to be displaced due to this communication.

With regard to diagnosis, if the wires of the device are not visible during the gynecological examination, ultrasound should be attempted to locate the IUD and pelvic x-ray should be used only when the ultrasound does not locate the device (ARAGÃO et al. 2022). Transvaginal ultrasonography (TVUS) has been considered the best method for diagnosing inadequacies in the position of the IUD, and should be indicated as a routine test to prevent failures. However, it has been proposed that anamnesis and clinical examination are appropriate for the evaluation of the position of the IUD, considering aspects such as: change in the uterine bleeding pattern and appearance of pelvic pain with an unusual pattern, regardless of the time of insertion, dispensing with the indication of routine TVUS for this purpose (LINHARES et al. 2021).

Regarding treatment, laparoscopy offers a safe and easy surgical procedure to locate and remove the IUD (MORAES et al. 2015) (ARAGÃO et al. 2022), as it has the advantage of enabling the analysis of the entire pelvic region, excluding possible associated injuries and also correcting probable perforations in adjacent organs (COELHO et al. 2003). The World Health Organization recommends that any IUD dislocated within the abdomen be removed after uterine perforation associated with the IUD, even if some authors disagree with the removal of any dislocated IUD, the high success rate of laparoscopic removal in asymptomatic/symptomatic patients makes this technique the most viable option (ARAGÃO et al. 2022). The patient's recovery is usually excellent and fast, and the procedure can be performed on an outpatient basis with high safety levels. For this reason, in cases of intra-abdominal IUD, laparoscopic removal of the IUD should be the first choice of therapy (MORAES et al. 2015). The patient's



psychological issues should also be considered when choosing this approach, as it is a less invasive procedure.

In addition, laparoscopy has the advantage of allowing adequate evaluation of the entire pelvic region to exclude associated lesions, including the site of uterine perforation (COELHO et al. 2003).

CASE DESCRIPTION

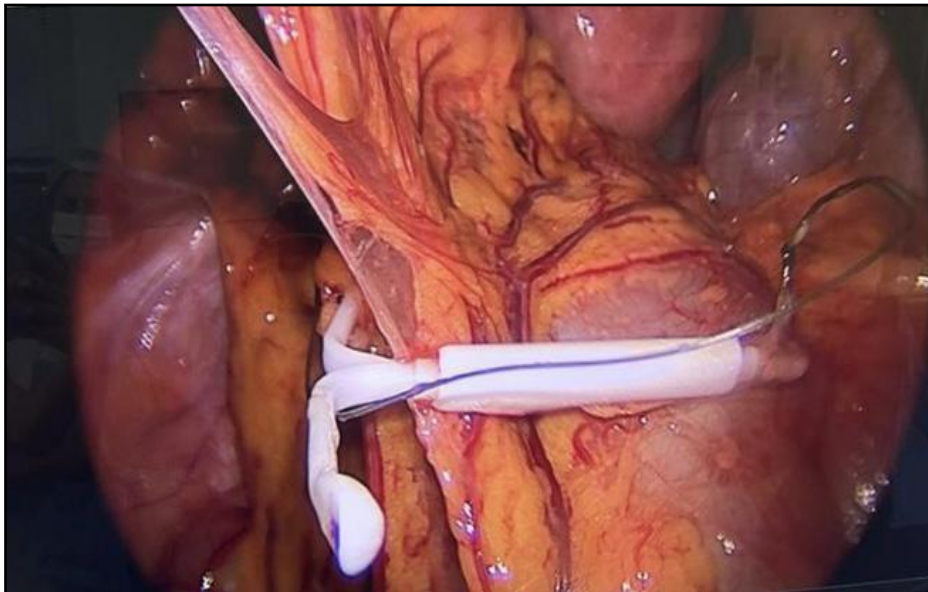
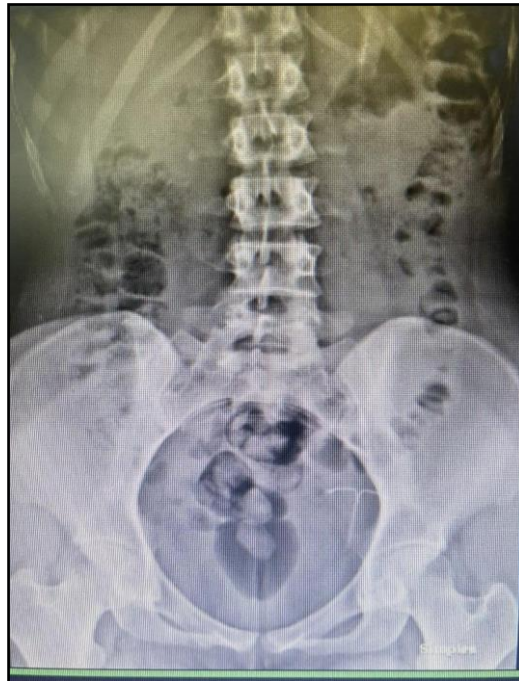A.S.C, female, 28 years old, 65kg, 1.68 m, with no comorbidities or family history of hypertension, diabetes, kidney diseases and uterine abnormality, in addition to having no history of previous surgeries. She underwent videolaparoscopy to remove the Mirena IUD due to its displacement to the extrauterine portion, in the abdominal cavity (anterior uterine wall).

After 3 months of her first delivery (12/20/2021), a cesarean section, the patient opted for the insertion of the Mirena IUD as a contraceptive method. In the postpartum period, she suffered from an infection, in which she had a lot of abdominal pain, fever, accumulation of fluid in the region which suffered an extravasation through the cesarean sections, but after 40 days she had a good recovery, without further complications. Performing, after about 3 months of improvement, the insertion of the device (03/22/2022).

The IUD insertion occurred as expected, being performed under anesthesia, the patient reported not having felt pain during or after the procedure. However, about 2 days after insertion, a routine transvaginal ultrasound was performed to confirm the positioning of the device, in which a displacement of the device outside the uterine cavity was detected, presenting itself in the abdominal cavity. In the endovaginal pelvic ultrasound, it was observed that the patient had a uterus in the midline, with regular contours and homogeneous texture of the myometrium. The endometrium is also regular at 4.4 mm thick. Both ovaries had regular contours and preserved ecotexture. The alteration was detected in the anterior isthmian wall, with an extrauterine portion, compatible with the perforation of the contraceptive device.

Then, the patient was referred for a radiographic study of the simple abdomen, which confirmed the suspicion and allowed the knowledge of the most exact location of the IUD, which was positioned in the region of the left iliac fossa.

Thus, the day after the diagnosis, he removed the device through videolaparoscopy. He reported that he had no pain and had a good recovery.



DISCUSSION

The IUD is considered a practical, low-cost, and long-acting method of contraception. However, it can generate complications for its users, even if rare (PAULO et al. 2019). Among the complications, we have uterine perforation, as presented in the case above. The World Health Organization suggests that any IUD displaced into the abdominal cavity by perforation caused by such a method be removed, due to the high success rate of the surgical procedure, both in symptomatic and asymptomatic patients (MORAES et al. 2015).

Uterine perforation is the most common cause of IUD loss, and can occur both during



insertion and after insertion of the device. Usually this loss occurs at the time of insertion, but a displacement can also occur after the insertion procedure. However, there are rare cases in which it follows adjacent structures in accordance with the local anatomy without causing further damage. Migration is possible due to the anatomy of the fallopian tube that approaches the corresponding ovary, without connecting directly, allowing free access between the uterine and abdominal cavity (LINHARES et al. 2021). In the case of the patient portrayed, we cannot conclude the cause of the IUD exit into the abdominal cavity, but transmigration through the cesarean section surgery scar is a possibility (ARAGÃO et al. 2022).

The case presented also portrays the need to monitor the patient after the implementation of the contraceptive method, through exams such as transvaginal pelvic ultrasound. In the case reported above, uterine perforation was found after this examination, even without complaints from the patient. Thus, allowing an early diagnosis of the complication, as well as its treatment, avoiding future consequences.

On examination, a linear echogenic image was observed on the anterior uterine isthmian wall, with an extrauterine portion, compatible with a displaced contraceptive device, outside the usual topography. Providing the diagnostic impression of perforation of the anterior uterine wall by the contraceptive device.

To confirm the diagnostic impression, a radiographic study of the simple abdomen was performed, in which the intrauterine device was observed in projection of the pelvic cavity, specifically in the left iliac fossa, as observed in the image below.

The method used to remove the IUD from the cavity was videolaparoscopy, which consists of a minimally invasive surgical technique and more indicated with high levels of safety, using a small optical device that is inserted into the patient's abdomen through a small insertion, allowing advantages such as less pain and shorter recovery time (RODRIGUES et al. 2023).

METHODOLOGY

From a medical case that occurred at the Santa Casa da Misericórdia de Presidente Prudente, together with his medical record, information was collected to carry out this case report. In addition, a search for information was carried out in databases.

RESULTS

The IUD is considered a practical, low-cost, and long-acting method of contraception. However, when rare complications occur, such as uterine perforation, the surgical method is the



best option for resolution, and videolaparoscopy is used, as reported in the literature. In addition, it is important to carry out tests to monitor the patient after IUD implantation, such as transvaginal pelvic ultrasound, thus avoiding future complications.

CONCLUSION

It is concluded that uterine perforation and IUD migration to another region outside the uterine cavity, such as the abdominal cavity, occur more commonly during device insertion. Therefore, because it occurs mainly during insertion, performing a gynecological examination to visualize the device's wires or performing a transvaginal ultrasound after insertion, to confirm its location, would be of paramount importance, as they would help in early diagnosis, avoiding further complications of the condition.

In addition, it would be possible to have a quick and effective treatment, performed through laparoscopy, a surgical procedure that remains the best option for IUD removal, both in asymptomatic and symptomatic patients, such a method has advantages such as less pain and better recovery time. In addition, it allows the visualization of the entire pelvic region, allowing the presence of other lesions that may be associated. With it, complications with intrauterine devices are rare, but they can occur as described above, however, their insertion should not be considered against - indication, considering the benefit and safety it provides for the woman's health in the long term.



REFERENCES

- Aragão, D., et al. (2022). Caminhos da clínica diu em cavidade: Abordagem laparoscópica. *Revista Caminhos da Saúde Coletiva pela UERJ*, 18(1). Retrieved from <https://revistas.unifoa.edu.br/caminhos>
- Coelho, J. C. U., Gonçalves, C. G., & Graf, C. M. (2003). Tratamento laparoscópico de periapendicite causada por dispositivo intra-uterino. *Arquivos de Gastroenterologia*, 40(1), 45-46. <https://doi.org/10.1590/S0004-28032003000100009>
- Linhares, J. J., et al. (2021). Apresentação não usual de dois casos de uso de dispositivo intrauterino hormonal - Mirena®. *Medicina (Ribeirão Preto)*, 54(3), 20-22. <https://doi.org/10.11606/issn.2176-7262.v54n3a176062>
- Makary, J., & Rathore, P. (2021). Lost and forgotten: A case of intravesical migration of an intrauterine device. *Urology Case Reports*, 39, 101841. <https://doi.org/10.1016/j.eururo.2021.101841>
- Moraes, P. R., et al. (2015). Tratamento videolaparoscópico para retirada de dispositivo intrauterino em fossa ilíaca direita. *Femina*, 43(1), 59-63. <https://doi.org/10.5935/1679-5509.20150010>
- Paulo, J., et al. (2019). Paciente com perfuração uterina assintomática após inserção de dispositivo intrauterino – Relato de caso e revisão de literatura. *Revista de Medicina e Saúde de Brasília*, 8(1), 67-73. <https://doi.org/10.5935/2237-9622.20190011>
- Rodrigues, A. S., et al. (2023). Avanços na técnica de cirurgia laparoscópica: Uma revisão sistemática das últimas décadas. *Brazilian Journal of Health Review*, 6(3), 13776-13783. <https://doi.org/10.34119/bjhrv6n3-079>