

Phenol peeling. Risks and medical care when performing this aesthetic procedure

DOI: 10.56238/isevjhv3n4-015

Recebimento dos originais: 11/06/2024

Aceitação para publicação: 31/07/2024

Juliana Fontes Beltran Paschoal¹, Leandro Cardozo Batista², Délio Tiago Martins Malaquias³, Rafaela Queiroz Sabbag⁴, Lucas de Souza Vieira⁵, Diógenes Trabuco da Silva Oliveira⁶, Lucimara Pigaiani⁷, Maria Fernanda Hagemann Gomes⁸, Filipe Jabur Lot Garcia⁹, Luiz Rodolfo Thomaz da Silva¹⁰, Aline Cristina Couto da Silva¹¹, Ana Laura Nogueira Ervilha¹², Diego Paulino Mariz¹³, Carla Pupo Concone¹⁴, Ana Carolina Passeli Bergamin¹⁵, Giovana de Souza Campos¹⁶, Thalita Pinheiro Morel Alineri¹⁷, Isadora de Oliveira Soler¹⁸, Hamilton Roberto Moreira de Oliveira Carriço¹⁹, Giovana Casarini Yamashiro²⁰, Amanda Luiza B. Cordeiro²¹, Felipe Santos de Teixeira Martiniano²², Suely Fernandes dos Santos²³, Gabriela Rodrigues da Mota²⁴ and Thiago Augusto Rochetti Bezerra²⁵.

ABSTRACT

Introduction: Phenol chemical peeling is considered a deep peeling that promotes facial rejuvenation, an aggressive method, promoting the exchange of several layers of the epidermis and dermis generating local re-epithelialization, leading to intense cell renewal, which helps in rejuvenation, stimulating its collagen, and consists of accelerating the exfoliation of the skin, through the use of chemical agents (acids), accelerating the speed of cell renewal. **Objectives:** To carry out a literature review on phenol peeling, its risks and medical precautions when performing this aesthetic procedure. **Methods:** The methodology used was a literature review. The research

¹ Medical student. University of Ribeirão Preto. Guarujá, São Paulo, Brazil.

PhD in Biotechnology. University of São Paulo. São Paulo, Brazil.

² Medical student. University of Ribeirão Preto. Guarujá, São Paulo, Brazil.

Master in Health Sciences. Federal University of São Paulo. São Paulo, Brazil

³ Medical student. University of Ribeirão Preto. Guarujá, São Paulo, Brazil.

⁴ Medical student. São Leopoldo Mandic. Campinas, São Paulo, Brazil.

⁵ Medical student. University of Ribeirão Preto. Guarujá, São Paulo, Brazil.

⁶ Medical student. University of Ribeirão Preto. Guarujá, São Paulo, Brazil.

⁷ Medical student. University of Ribeirão Preto. Guarujá, São Paulo, Brazil.

⁸ Medical student. University of Ribeirão Preto. Guarujá, São Paulo, Brazil.

⁹ Medical student. University of Ribeirão Preto. Guarujá, São Paulo, Brazil.

¹⁰ Medical student. University of Ribeirão Preto. Guarujá, São Paulo, Brazil.

¹¹ Medical student. University of Ribeirão Preto. Guarujá, São Paulo, Brazil.

¹² Medical student. University of Ribeirão Preto. Guarujá, São Paulo, Brazil.

¹³ Medical student. University of Ribeirão Preto. Guarujá, São Paulo, Brazil.

¹⁴ Medical student. University of Ribeirão Preto. Guarujá, São Paulo, Brazil.

¹⁵ Medical student. University of Ribeirão Preto. Guarujá, São Paulo, Brazil.

¹⁶ Medical student. University of Ribeirão Preto. Guarujá, São Paulo, Brazil.

¹⁷ Medical student. University of Ribeirão Preto. Guarujá, São Paulo, Brazil.

¹⁸ Medical student. University of Ribeirão Preto. Guarujá, São Paulo, Brazil.

¹⁹ Medical student. University of Southern Santa Catarina. Tubarão, Santa Catarina, Brazil.

²⁰ Medical student. Nove de Julho University. São Bernardo do Campo, São Paulo, Brazil.

²¹ Medical student. Potiguar University. Natal, Rio Grande do Norte, Brazil.

²² Internal Medicine resident at Hospital Beneficência Portuguesa de Santos. Santos, São Paulo, Brazil.

²³ Physiotherapist (UNINOVE). Nove de Julho University. São Paulo, Brazil.

²⁴ Graduated in Medicine. Federal University of the Southern Border. Passo Fundo, Rio Grande do Sul, Brazil.

²⁵ Medical student. University of Ribeirão Preto. Guarujá, São Paulo, Brazil.

PhD in Medical Sciences. Ribeirão Preto Medical School. University of São Paulo. Ribeirão Preto, São Paulo, Brazil.



was carried out by means of an electronic search for scientific articles published on the Scielo (Scientific Electronic Library Online) and Lilacs (Latin American Health Sciences Literature) and Pubmed websites. Discussions: Deep peels are aggressive procedures that act on the reticular dermis and can cause the formation of thick crusts and post-treatment scars. Recovery may require the use of dressings and takes at least 3 months for the redness under the skin to disappear, the final result of the procedure depending on the chemical agent being used. Conclusions: In view of all the advantages presented, it is a procedure that necessarily requires dermatological care and must be carried out carefully, following all the necessary steps correctly in order to avoid possible complications, as phenol is a toxic compound that penetrates the epidermis with high affinity and is absorbed into the bloodstream. Undoubtedly, new studies will bring previously unknown concepts regarding the effects of phenol chemical peeling, allowing for an effective therapeutic approach to reduce the toxic effects of the compound.

Keywords: Phenol chemical peeling, Acial rejuvenation, Exfoliation of the skin.

INTRODUCTION

The skin is made up of two primary layers and a layer of subcutaneous fat, each layer with different characteristics and functions: dermis, epidermis and subcutaneous hypodermis, as well as attached organs such as hair follicles, sweat glands, sebaceous glands and nails (COX, 2021).

Localized damage to the skin and/or underlying soft tissues, usually over a bony prominence or related to the use of a medical device or other artifact. The injury may present as intact skin or as an open ulcer and may be painful. The injury occurs as a result of intense and/or prolonged pressure in combination with shear. Soft tissue tolerance to pressure and shear can also be affected by microclimate, nutrition, perfusion, comorbidities and its condition (LANDAU et al. 2024).

According to Bagatin (2019), as the years go by, the speed of cell renewal in humans slows down, due to changes in the skin as a result of ageing. In this way, aesthetic procedures have been improved in order to meet the needs of the population to achieve longevity.

Cruz et al, (2022), discussed beauty treatments used to camouflage and delay intrinsic or chronological skin ageing. One of these methods is chemical peels, which consist of applying more than one type of formula with chemical agents that clog up the skin's surface, only in the area to be treated, working on deeper layers and promoting cell regeneration.

Facial peeling stimulates the renewal of skin cells through controlled peeling using chemical substances or physical methods such as dermabrasion. The procedure can be used to lighten blemishes and acne scars, as well as treating wrinkles and expression lines (LIEBERMAN, 2020).

According to Costa et al. (2017), the complex interaction between the various cells present in the layers of the skin and the chemical agents used in the formulation of aesthetic techniques contributes to the understanding of possible interactions and toxicities resulting from the use of chemical peels.

This technique consists of applying acids to the skin to remove the damaged layers and promote the growth of a smoother, more elastic, softer and fresher layer through cell renewal. Treatment with chemical peels is quick and brings visible results from the very first session (OLIVEIRA, 2016).

According to Della Rosa (2020), phenol chemical peeling is considered a deep peeling that promotes facial rejuvenation, an aggressive method, promoting the exchange of several layers of the epidermis and dermis generating local re-epithelialization, leading to intense cell renewal, which helps in rejuvenation, stimulating its collagen, and consists of accelerating the exfoliation



of the skin, through the use of chemical agents (acids), accelerating the speed of cell renewal (turn over).

Non-surgical aesthetic procedures are on the rise in Brazil, driven by the presence of health professionals who share surprising results on social media. Among the most powerful and effective options available is phenol peeling, a procedure that has gained attention for its impressive results. However, because it is considered invasive and complex, it poses health risks.

In this context, this study will discuss the levels of toxicity after and during the use of chemical phenol peels in high concentrations, with possible adverse effects due to disturbances to the layers of the skin.

OBJECTIVE

To carry out a literature review on phenol peeling, its risks and medical precautions when performing this aesthetic procedure.

MATERIAL AND METHODS

The methodology used was a literature review. The research was carried out by means of an electronic search for scientific articles published on the Scielo (Scientific Electronic Library Online) and Lilacs (Latin American Health Sciences Literature) and Pubmed websites. The health terminologies consulted in the Health Sciences descriptors (DeCS/BIREME) were used; phenol peeling, its risks and medical care when carrying out this aesthetic procedure.

The inclusion criteria were: original article, published in Portuguese and English, freely accessible, in full, on the subject, in electronic format, totaling 22 articles.

DISCUSSION

According to Schiedler (2024), the skin is made up of two layers: the epidermis and the dermis. These layers contain elastic fibers, nerve endings that provide sensations, immune cells, blood and lymphatic vessels and other attachments that enable the balance between the internal and external environment to be maintained. Over the years, the speed of cell renewal in humans slows down, due to changes in the skin as a result of ageing.

According to Yokomizo (2013), the integument is predominantly considered to be a protective barrier, as it contributes to homeostasis and in this way helps the body to regulate body temperature and enables the perception of pleasant and painful stimuli. In addition, the system has appendages that perform functions responsible for the protective coating and preventing excessive

loss of water to the external environment. This makes it impossible for the internal system to be exposed to possible pathogens present in the ecosystem.

According to Singh et al. (2020), constant peeling and renewal can help remove pathogens present on the surface of the epidermis, as it contains antimicrobial peptides that contribute to bacterial and chemical defense. The Langerhans cells present in the epidermis are responsible for antigen presentation to T lymphocytes, while the Merkel cell contains neurotransmitters that give the skin its mechanical receptor characteristics.

The term peeling comes from the English “to peel”, which means to peel. This procedure consists of using a chemical agent on the skin capable of causing a controlled destruction of the epithelial layer, which consequently generates local re-epithelialization in order to promote intense cell renewal. In this way, the skin is rejuvenated and skin imperfections are eliminated, including pimples, spots, marks, scars and a reduction in pigmentary dyschromia (VASCONCELOS et al. 2013).

Della Rosa (2020) points out that, in general, the chemical molecules that can be used in peeling have the potential to generate a small, controlled inflammatory process, which leads to the denaturation of proteins in the epithelial layer. As a result, the body replenishes new dermal collagen and elastin, restructuring the connective tissue and proliferating new keratinocytes.

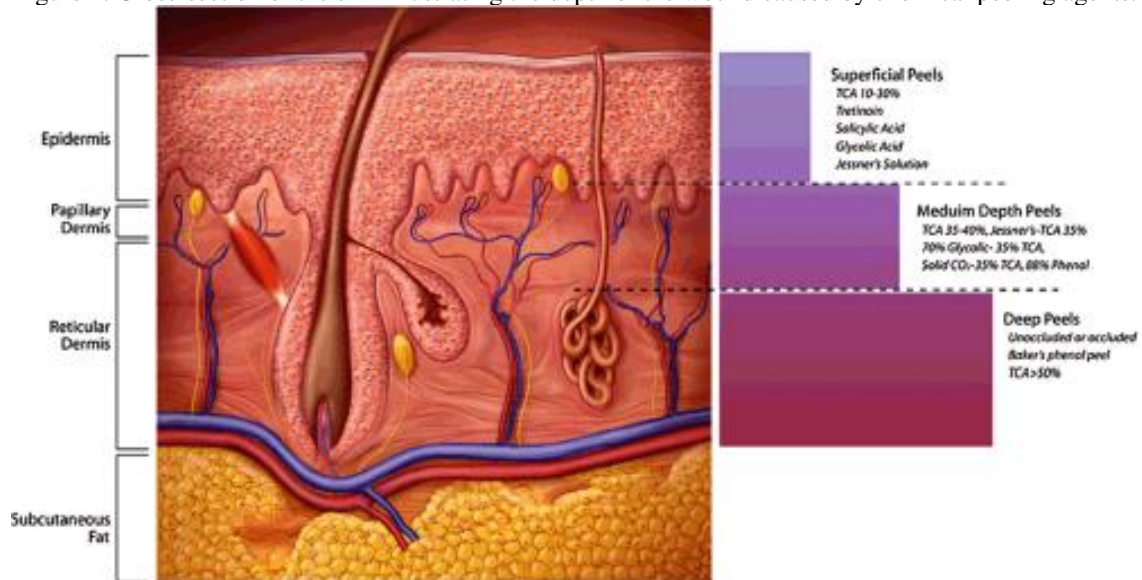
The processes and types of peeling vary according to the depth to which they affect the epithelial tissue: superficial, medium and deep.

Superficial peeling acts on the epidermis down to the papillary dermis. This procedure uses water-soluble acids and chemical components with low toxic potential that can be used more frequently.

Medium peels reach the deep layers of epithelial tissue, namely the papillary and upper reticular dermis. This procedure uses acids that promote intense peeling, which requires strict preparation and 7 to 15 days to return to routine.

According to Goulart (2022), deep peels are aggressive procedures that act on the reticular dermis and can cause the formation of thick crusts and post-treatment scars. Recovery may require the use of dressings and takes at least 3 months for the redness under the skin to disappear, the final result of the procedure depending on the chemical agent being used. The agents used for deep peels are phenol and Baker-Gordon solution. FIGURE 1 shows a cross-section of the skin illustrating the depth of the wound caused by chemical peeling agents.

Figure 1. Cross-section of the skin illustrating the depth of the wound caused by chemical peeling agents.



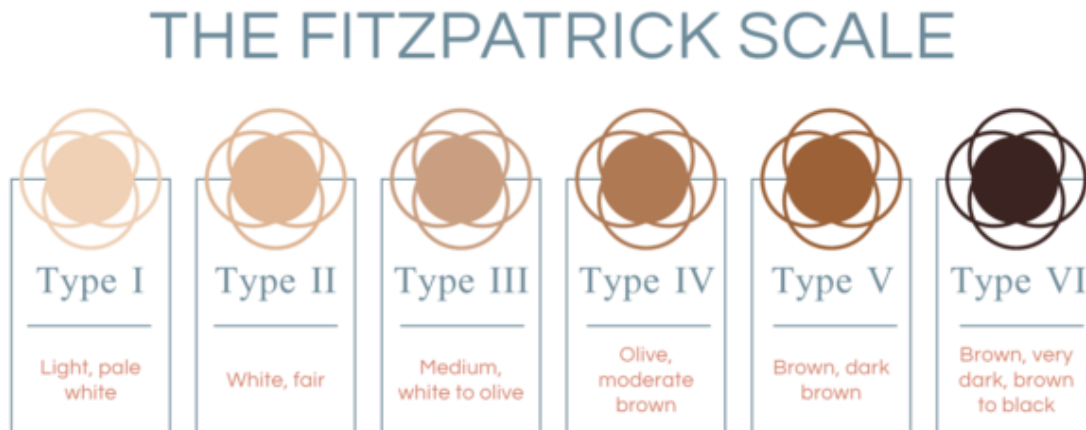Source: plasticsurgerykey.com/superficial-chemical-peels/ (2023).

According to Bagatin (2019), peeling preparation varies depending on the disease being treated. Regimens differ for photodamage, hyperpigmentation (melasma and post-inflammatory hyperpigmentation), acne vulgaris and other conditions. In addition, there are special issues to consider when treating darker ethnic groups. Before the chemical peel, a detailed history and skin examination should be carried out on all patients. Standardized photographs are taken of the areas to be peeled, including frontal and lateral views of the entire face.

For Cox (2021), the use of topical retinoids (tretinoin, tazarotene, retinol formulations) for 2 to 6 weeks before the peel thins the stratum corneum and increases epidermal renewal. These agents also reduce the epidermal melanin content and accelerate epidermal healing. Retinoids also improve the penetration and depth of chemical peels. These agents demonstrate optimal effects in the treatment of photo-damage in Fitzpatrick I to III skin types. They can be used up to 1 or 2 days before the peel. Retinoids can be resumed post-operatively after all evidence of peeling and flaking has disappeared.

The Fitzpatrick skin type system (FIGURE 2) was developed by a Harvard dermatologist in the 1970s. It is used as a measuring tool to determine and classify how different skin types react to ultraviolet (UV) light. The Fitzpatrick system takes into account genetic make-up and reaction to sun exposure (burns and tanning and how they affect the skin).

Figure 2. Fitzpatrick's skin type system.



Source: skinrenewal.co.za/fitzpatrick-skin-type (2024).

Phenol peeling uses in its formulation the technique created by Baker-Gordon (TABLE 1), to minimize adverse effects that can be extremely toxic. This method is indicated for skin whitening and aging due to genetic factors or excessive exposure to the sun (photoaging) (DELLA ROSA, 2020).

In addition, it can be used by patients with excess wrinkles, treatment of intense acne, keratoses, hyperpigmentation and heterogeneous pigmentation (JUSTO et al. 2019).

The Baker-Gordon formulation uses croton oil as a component, which helps the phenol to penetrate the skin more intensely and coagulate the keratin of the epithelial tissue. The properties of the oil mean that the hydroxyls contained in its molecule have a high affinity, making it possible to dissolve it in an alcoholic medium and in the presence of benzenes such as phenol (KADUNC, 2009).

In addition to croton oil, phenol is used as the main component of the formulation, as it has the effect of peeling the skin and consequently the rejuvenation process (KADUNC, 2009).

According to Costa et al. (2017), phenol acts as a keratolytic agent, as it is able to penetrate deeper into the dermis and intensely stimulate the inflammatory process. Thus, the compound induces collagen production and regeneration of epithelial tissue.

Finally, liquid soap is used in the formulation as a vehicle to reduce the fat present on the skin, facilitating the action of phenol. Water is used to help control the concentration of the formula, since the phenol molecule must be diluted correctly for it to work properly (GOULART, 2022).

Table 1. Baker-Gordon formulation

<i>Baker-Gordon's Formula</i>	
<i>Components</i>	<i>% p/p</i>
<i>Phenol at 88%</i>	<i>3</i>
<i>Demineralized water</i>	<i>2</i>
<i>Croton Oil</i>	<i>3</i>
<i>Liquid soap</i>	<i>8</i>

In addition to the concentration used, it is important to consider the pH value of the preparation, which can vary from two to four, and the lower its value (more acidic) the greater the exfoliating action of the peel and its irritating power on the skin (a pH value of 3.5 is ideal for good exfoliation) (TIMONER et al. 2010).

Phenol is used today in the manufacture of dyes, in the preparation of resins, in the production of phenolphthalein, aspirin, picric acid and cresols. Phenol (88% phenol + 12% water) ,3ml / Ordinary/distilled water, 2ml / Soap (liquid hexachlorophene) 0.025%, 8 gts / Croton oil, 3 gts. This formulation produces peeling indicated for the treatment of deep wrinkles and actinic keratoses caused by severe photoaging, in any region of the face (SINGH et al. 2020).

Phenol peeling consists of the controlled application of the substance, which can have different concentrations depending on the degree of intervention, which will cause a burn to the skin. This triggers an inflammatory process that will result in skin peeling. After the procedure, the skin can remain red for up to three months, with a lot of peeling in the first 15 days (CRUZ et al. 2022).

During the procedure, the phenol solution is carefully applied by the dermatologist, and it is important to remember that only these professionals, or plastic surgeons, can apply phenol peeling. The resulting chemical reaction removes the damaged upper layers, stimulating cell regeneration. The effect is like a very intense exfoliation, like a skin change, which, after peeling, brings a smoother, more uniform and youthful layer (DELLA ROSA, 2020; CRUZ et al. 2022; KOHLI et al. 2021).

The treatment is highly effective in smoothing out deep wrinkles, offering a more youthful appearance. Deep exfoliation helps to even out the texture and tone of the skin, giving it a healthier appearance. Dark spots and acne scars are significantly reduced, resulting in clearer, more even skin (CRUZ et al. 2022).

According to Yokomizo (2013), despite the benefits, phenol peeling requires strict care during the recovery period, which can vary from 1 to 3 months. During this period, the skin

becomes red, swollen and extremely sensitive. Sun protection is essential, and it is essential to avoid any exposure to the sun to prevent damage to the newly regenerated skin.

The Brazilian Society of Dermatology (SBD) advises that the procedure should be carried out by qualified dermatologists and in a hospital environment, with cardiac monitoring and anesthesia, due to the risks associated with phenol toxicity (CRUZ et al. 2022).

Despite appearing to be a simple procedure, phenol promotes a series of interactions with the body that require care from its application to the final result, which will occur months later (LANDAU et al. 2024).

According to Goulart (2022), phenol can be nephrotoxic, hepatotoxic and cardiotoxic. This means that the substance can cause damage to the kidneys, liver and heart. Cardiac toxicity occurs due to changes in ion channels, resulting in arrhythmias. In addition, a change in the energy metabolism of heart cells can occur, with a reduction in ATP (adenosine triphosphate), an essential molecule for energy supply. This decreases the ability of the heart cells to contract properly, as well as causing direct damage to them.

The procedure can also cause hypopigmentation, resulting in permanent lightening of the skin, which is why it is not recommended for dark-skinned patients. In rare cases, scarring and serious heart complications can occur due to the absorption of phenol by the body. Therefore, it is essential that this treatment is carried out under the supervision of qualified professionals to minimize these risks (DELLA ROSA, 2020; CRUZ et al. 2022; KOHLI et al. 2021).

According to Bagatin (2019), the hypersensitivity of the skin after the procedure leaves it looking pink for up to six months, and during this period you should avoid the sun as much as possible and use moisturizers. Due to the risks involved, phenol peeling should be performed exclusively by dermatologists or plastic surgeons in controlled environments, so that heartbeats are monitored. It is essential that those interested consult a qualified professional to assess whether the procedure is suitable for their specific needs and skin type.

The legality and safety of the procedure are important factors. Only doctors have the necessary training and license to handle toxic substances like phenol and perform invasive procedures safely (KADUNC, 2009; SCHIEDLER, 2024).

Performing phenol peels outside of a regulated medical environment is illegal and extremely dangerous, according to the standards and guidelines established by the Regional Councils of Medicine and Medical Societies, such as the Brazilian Society of Dermatological Surgery (SBCD) and the Brazilian Society of Dermatology (SBD).

For Della Rosa (2020), in addition to the aesthetic consequences, such as permanent stains and scars that can compromise facial functions, phenol peel can be harmful to the cardiac system, as is being investigated in Henrique's case. The substance is cardiotoxic and can cause arrhythmias and, in severe cases, even cardiac arrest.

Cox (2021) warns that phenol peels are not suitable for everyone. People with heart problems, uncontrolled blood pressure or darker skin (high body type) are at high risk.

Goulart (2022) explains that the technique causes a deep burn to the skin and requires great care. According to experts, phenol peeling is not suitable for all skin types, is recommended for men and women over 60, and should not be carried out by beauticians or dentists.

In Brazil, non-invasive aesthetic treatments grew by 56% between 2020 and 2022, making the country second in the world ranking for this procedure. In 2013, the Medical Act Law was passed, which regulates the practice of medicine in the country, defining which activities are exclusive to doctors and which can be carried out by other health professionals. The law establishes guidelines on what constitutes a medical act, with the aim of guaranteeing the quality of the services provided and patient safety (GOULART, 2022).

Bagatin (2019) mentions that the quest for rejuvenation must always be accompanied by strict safety and professionalism criteria. It is essential that people considering this treatment are aware of the risks and always seek appropriate medical advice.

Before the procedure is carried out, some precautions are necessary, such as: shaving the area where the peeling will be carried out, daily use of facial soaps, moisturizing creams and alcohol-free sunscreen, as well as regular consultations with the dermatologist (CRUZ et al. 2022).

The procedure should mainly be carried out in a hospital environment, or in a clinic that has all the necessary support to ensure patient safety. The patient must have an intravenous drip, as the phenol must be in concentrations permitted in the body (KOHLI et al. 2021).

Therefore, the procedure must have an interval from one area of application to another while the serum is administered, so that the patient can eliminate the concentrations of phenol applied. It is therefore essential to have medical supervision throughout the process, since deep chemical phenol peeling can have adverse effects due to its toxicity (SCHIEDLER, 2024).

According to Yokomizo (2013), carbolic acid or phenol (C₆H₅OH) is an aromatic organic compound derived from coal tar, capable of promoting intense facial rejuvenation when used appropriately. As it is applied topically, it promotes the denaturation and protein coagulation of epidermal keratin, causing a rapid action of intense uniform whitening in the region

Deep chemical phenol peels, when carried out by a skilled professional, show results that are incomparable to other long-term exfoliative procedures. However, the use of phenol in high concentrations can exert direct toxicity on the skin, heart, liver and kidneys (BAGATIN, 2019).

Complications vary according to the type and depth of the procedure, and those that occur in human body systems are listed below (BAGATIN, 2019).

Cox (2021) states that phenol peeling in contact with the skin is capable of causing severe lesions. The classic symptoms presented by the toxicity of the compound are: strong irritation of the mucous membranes, eruptions, as well as the appearance of hypertrophic scars and keloids.

Bacterial infections by *Staphylococcus* sp, *Streptococcus* sp and *Pseudomonas aeruginosa* can occur as a result of the inflammation caused by phenol toxicity. Among the symptoms associated with the proliferation of the microorganism are: discomfort, excessive pain, high fever and others (JUSTO et al. 2019).

In addition, pigmentary changes can manifest after treatment, such as: hypopigmentation or post-inflammatory hyperpigmentation due to phenol toxicity in melanocytes. Both must be monitored and treated so that an irreversible condition does not develop (DELLA ROSA, 2020; JUSTO et al. 2019; KOHLI et al. 2021; PATHAK, 2020).

According to Costa et al. (2017), the absorption of phenol is capable of causing morphological changes in the myocardium, its toxic effect can cause cardiac arrhythmias, atrial and ventricular fibrillation, tachycardia, premature ventricular contractions and electromechanical dissociation.

Singh et al. (2020) point out that medical monitoring is necessary, especially for those with a family history of heart disease. Special care should be taken to avoid possible complications in blood circulation, such as cardiac monitoring, intravenous infusion, as well as spaced applications so that there is no damage to the muscle after long-term treatment.

Deep peeling with high concentrations of phenol is capable of intoxicating the kidneys and liver, due to the high demand for the molecule to be biotransformed and excreted. Approximately 70 to 80% of the amount of phenol absorbed is conjugated by the liver to glucuronic acid and sulphuric acid, after which it is excreted by the kidneys within 15 to 20 minutes of application (LANDAU et al. 2024).

Therefore, since phenol is readily absorbed and widely distributed after dermal exposure, the main sites of metabolism that are constituents of the gastrointestinal tract are impaired due to the toxic levels of the compound. Therefore, phenol is capable of causing nephrotoxicity and



hepatotoxicity, impairing the functionality of these organs (DELLA ROSA, 2020; JUSTO et al. 2019; KOHLI et al. 2021; PATHAK, 2020).

Della Rosa (2020) mentions that for the use of deep phenol peeling, the patient must have clear, thin and dry skin. Compared to women, males have thicker skin, which consequently reduces the action of phenol, resulting in less effective treatment.

As a precaution, patients should be avoided if they have: heart disease, herpes, continuous exposure to UV rays, psychological instability, kidney or liver disease, recent use of isotretinoin and a predisposition to keloids (JUSTO et al., 2008).

The use of peeling is contraindicated in cases of pregnancy, lactation, active herpetic lesions, use of photosensitizing drugs and allergies to the components of the formula (PATHAK, 2020; SCHIEDLER, 2024; VASCONCELOS et al. 2013).

CONCLUSION

In view of the facts mentioned above, phenol chemical peeling is capable of reversing visible eruptions or ruptures due to ageing on human skin.

However, short-term use of the compound in high concentrations can lead to the appearance of pathologies linked to the integument and, consequently, irreversible changes to the surface of the organ after treatment.

In view of all the advantages presented, it is a procedure that necessarily requires dermatological care and must be carried out carefully, following all the necessary steps correctly in order to avoid possible complications, as phenol is a toxic compound that penetrates the epidermis with high affinity and is absorbed into the bloodstream.

Undoubtedly, new studies will bring previously unknown concepts regarding the effects of phenol chemical peeling, allowing for an effective therapeutic approach to reduce the toxic effects of the compound.

REFERENCES

1. Bagatin, E., Hassun, K., & Talarico, S. (2019). Revisão sistemática sobre peelings químicos. *Surgical & Cosmetic Dermatology, 1*(1), 37-46.
2. Costa, I. M. C., et al. (2017). Review in peeling complications. *Journal of Cosmetic Dermatology, 16*(3), 319-326.
3. Cox, S. V., Zachary, C. B., & Cohen, J. L. (2021). Skin preparation for photodynamic therapy, chemexfoliation, and ablative laser resurfacing: A systematic literature review. *Dermatologic Surgery, 47*(7), 938-941.
4. Cruz, L., et al. (2022). Consequências toxicológicas de altas concentrações de fenol no tratamento com peeling químico. *Revista Científica de Estética e Cosmetologia, 2*(1), E0562022-7.
5. Della Rosa, R. C. (2020). Notabilidade dos cuidados do tratamento por peeling. *Scire Salutis, 10*(2).
6. Goulart, B. M., da Silva, T. B. F., & da Silva Braga, J. S. (2022). Intercorrências do Ácido Tricloroacético e Ácido Fenol. *Atas de Ciências da Saúde, 10*(4).
7. Justo, A. S., et al. (2019). Caracterização química do óleo de Croton tiglium (Euphorbiaceae) e avaliação do perfil dermatológico do peeling de fenol com óleo de Croton.
8. Kadunc, B. V., & Vanti, A. A. (2009). Avaliação da toxicidade sistêmica do fenol em peelings faciais. *Surgical & Cosmetic Dermatology, 1*(1), 10-14.
9. Khunger, N., Chanana, C., & Arsiwala, N. (n.d.). Value of chemical peels in aesthetic practice.
10. Kohli, D., et al. (2021). Advances in peeling techniques for fresh produce. *Journal of Food Process Engineering, 44*(10), e13826.
11. Landau, M., et al. (2024). Frontal Fibrosing Alopecia – A new absolute contraindication for deep chemical peels. *Clinics in Dermatology*.
12. Lieberman, D. M., & Roy, S. (2020). Chemical peels. In *Facial Plastic and Reconstructive Surgery: A Comprehensive Study Guide* (pp. 285-297). Cham: Springer International Publishing.
13. Oliveira, T. S. de. (2016). Rejuvenescimento da pele por meio da utilização do laser: uma revisão sistemática da literatura.
14. Pathak, A., Mohan, R., & Rohrich, R. J. (2020). Chemical peels: Role of chemical peels in facial rejuvenation today. *Plastic and Reconstructive Surgery, 145*(1), 58e-66e.
15. Schiedler, V. (2024). Chemical peels for rejuvenating eyelids and face. *International Ophthalmology Clinics, 64*(3), 29-40.



16. Silva, M. V., & de Souza, D. V. (n.d.). A eficácia do peeling de fenol no rejuvenescimento facial The effectiveness of phenol in peeling facial rejuvenation.
17. Singh, B., et al. (2020). Phenolic compounds in potato (*Solanum tuberosum* L.) peel and their health-promoting activities. *International Journal of Food Science & Technology, 55*(6), 2273-2281.
18. Timoner, F. R., et al. (2010). Suporte básico de vida e suporte avançado de vida em cardiologia: Proposta de uma nova estratégia para abordagem e prevenção das intercorrências clínicas em cirurgia dermatológica. *Anais Brasileiros de Dermatologia, 85*, 115-118.
19. Vasconcelos, B. N., et al. (2013). Estudo comparativo de hemifaces entre 2 peelings de fenol (fórmulas de Baker-Gordon e de Hetter), para a correção de ríntides faciais. *Surgical & Cosmetic Dermatology, 5*(1), 40-44.
20. Yokomizo, V. M. F., et al. (2013). Chemical peels: Review and practical applications.