



## Symptomatic Meckel's diverticulum in an adult: A case report

DOI: 10.56238/isevjhv3n4-016

Receipt of originals: 06/11/2024

Acceptance for publication: 07/31/2024

**Tiago Lyria da Silva Azinato<sup>1</sup>, Camilly Emanuelle Colares Barreto<sup>2</sup>, Emanuela Palma de Moraes<sup>3</sup>, Gabriela Zanoni Rigo Villela<sup>4</sup>, Giovanna de Almeida<sup>5</sup>, Mariana Pedroso de Campos<sup>6</sup>, Natalia Cervantes Uzeloto Guazi<sup>7</sup>, Nathalia de Oliveira Hildebrando<sup>8</sup>, Pholliana Silva Lelis<sup>9</sup>.**

### ABSTRACT

Introduction: Meckel's diverticulum (MD) is a true intestinal diverticulum. It originates from failure in the obliteration and absorption of the omphalomesenteric duct during the first trimester of fetal life and affects 2% to 4% of the general population. MD can have its symptomatic or asymptomatic form. The appearance of symptoms suggests complications. The diagnosis depends on the occurrence of complications and is fundamentally based on imaging tests. The definitive treatment of MD is surgical, and the real controversy surrounding MD concerns the option of treating the silent disease with prophylactic resection when discovered during surgery.

---

<sup>1</sup> Graduating from Medicine  
University of Western São Paulo  
LATTES: 9868197015991108  
Email: tiagolyria23@gmail.com

<sup>2</sup> Medical Graduate  
University of Western São Paulo  
LATTES: 2580979553889545  
E-mail: camillyemanuelle2017@hotmail.com

<sup>3</sup> Medical Graduate  
University of Western São Paulo  
LATTES: 8552037083092404  
Email: moraes.palma.emanuela@gmail.com

<sup>4</sup> Medical Graduate  
Anhanguera University UNIDERP  
LATTES: 5551672507100213  
E-mail: gabriela.zrv@gmail.com

<sup>5</sup> Medical Graduate  
University of Western São Paulo  
LATTES: 7343829295017118  
E-mail: giovannaalmeida111@hotmail.com

<sup>6</sup> Medical Graduate  
University of Western São Paulo  
LATTES: 0813107242370116  
E-mail: marianapcampos2002@gmail.com

<sup>7</sup> Medical Graduate  
University of Western São Paulo  
LATTES: 2386739547111351  
E-mail: nataliaguazi2000@gmail.com

<sup>8</sup> Medical Graduate  
University of Western São Paulo  
LATTES: 7425958609544781  
E-mail: nathaliahildebrando123@gmail.com

<sup>9</sup> Medical Graduate  
University of Western São Paulo  
LATTES: 5722160715062325  
E-mail: phollianaalelis@gmail.com



**Objective:** To demonstrate the importance of evaluating Meckel's diverticulum, both symptomatic and asymptomatic, as well as the difficulty of its diagnosis, to make a better choice of treatment. **Methods:** From a medical case that occurred at the Santa Casa da Misericórdia de Presidente Prudente, and its medical records, information was collected to carry out this report. **Results:** MD is rare and usually asymptomatic in adults, where the definitive treatment is surgical, with absolute indication in symptomatic patients. In asymptomatic patients, surgical treatment is controversial considering the potential for complications versus the risk of the surgical procedure. **Conclusion:** MD, when symptomatic, is most often associated with complications. It is essential that each case of Meckel's diverticulum be evaluated individually, considering variables such as gender, age (complications are more frequent in children and young men), anesthetic risk, and diverticulum characteristics for a better prognosis and better choice of treatment.

**Keywords:** Meckel's diverticulum, Treatment, Diagnosis, Complications.

## INTRODUCTION

Meckel's diverticulum (MD) is formed by all layers of the intestinal wall and is a true intestinal diverticulum. It originates from failure in the obliteration and absorption of the omphalomesenteric duct (yolk duct) during the first trimester of fetal life (ARAÚJO et al. 2014).

In the embryo, the omphalomesenteric canal (or yolk duct) communicates between the yolk sac and the lumen of the midgut of the developing fetus. This canal usually obliterates between the 6th and 10th week of gestation and becomes a fibrous band, called the omphalomesenteric ligament, which later usually reabsorbs completely. Meckel's diverticulum corresponds to the defective involution of this primitive yolk loop. It presents as a single, blind recess at the anti-mesenteric border of the ileum, opposite the terminal branches of the superior mesenteric artery, approximately 90 cm from the ileocecal valve (with the distance varying slightly according to the patient's age) (ARAÚJO et al. 2014) (LEQUET et al. 2017).

In approximately 50% of cases, it has ectopic tissues, the most common being those of gastric and pancreatic origin. It generally presents as a short, broad-based diverticulum, with its own blood supply, coming from a terminal branch of the superior mesenteric artery that crosses the ileum to the diverticulum (ARAÚJO et al. 2014). The histology of Meckel's diverticulum is the same as that of the ileum. However, ectopic mucosal tissues can develop within the intestinal layers (most commonly gastric), but also pancreatic, duodenal, colonic, endometrial, Brunner's gland, and even hepato-biliary (LEQUET et al. 2017).

Meckel's diverticulum is an embryonic vestige that affects 2% to 4% of the general population. It is the most common of the gastrointestinal malformations, which together represent around 6% of all known congenital malformations (LORENZONI et al. 2019). It is



twice as common in men as in women and is usually located 60 cm from the ileocecal valve. MD is the most frequent cause of lower gastrointestinal bleeding in children. It seems to have an increased incidence in newborns with other anomalies, such as cleft palate, bicornual uterus, annular pancreas, esophageal atresia and anorectal atresia or malformations of the central nervous and cardiovascular systems (ARAÚJO et al. 2014).

MD can have its symptomatic or asymptomatic form. The appearance of symptoms suggests complications such as digestive bleeding, more common in children; and obstructive, inflammatory, or neoplastic phenomena, more common in adults (ARAÚJO et al. 2014). Many patients with Meckel's diverticulum are asymptomatic. Risk factors for increased risk of developing symptoms include age under 50 years, male gender, diverticulum greater than 2 cm in length, presence of ectopic tissue, wide-based diverticulum, and fibrous bands attached to the diverticulum (AN and ZABBO, 2023).

The most common etiologies of symptomatic Meckel's disease are intestinal obstruction, gastrointestinal (GI) hemorrhage, and inflammation of Meckel's disease with or without perforation. Obstruction refers to cases in which the Meckel is the cause of the intestinal obstruction, for example, by intussusception or invagination of the Meckel into the lumen of the small intestine. Volvulus of the small intestine around the diverticular axis is another possible mechanism. GI hemorrhage refers to painless bleeding from the rectum and is often the result of acid produced from a piece of ectopic gastric mucosa in the Meckel damaging the intestinal lumen, leading to a bleeding ulcer. Inflammation refers to inflammation of Meckel's own or perforation of the diverticular walls resulting in peritonitis (HANSEN and SØREIDE, 2018).

Clinical presentation includes abdominal pain, vomiting, constipation, and bloody stools, as rectal bleeding is typically described as gooseberry or brick-colored jelly. Children usually have stools with the classic color of "gooseberry jelly", while adults usually have melena (ARAÚJO et al. 2014) (AN and ZABBO, 2023). These symptoms and the pathological processes that cause them are not unique to Meckel's disease. For example, an inflamed or perforated Meckel's disease can be mistaken for an inflamed appendix, a much more common condition. Therefore, Meckel's disease represents a diagnostic challenge and is often found incidentally during examination for symptoms, although it is of another cause (HANSEN and SØREIDE, 2018). Clinically, Meckel's diverticulum should be suspected in any child under 2 years of age with painless rectal bleeding. It accounts for approximately 50% of all lower GI bleeding in children under 2 years of age (AN and ZABBO, 2023).



Symptoms stemming from Meckel's diverticula most commonly present in early childhood, with several case series suggesting that most diagnoses occur before the age of 10 years (FUSCO et al. 2022). Most individuals with MD remain asymptomatic for life, and their diagnosis is usually made during laparotomy and laparoscopies indicated for other reasons. The appearance of symptoms suggests complications such as digestive bleeding, more common in children; and obstructive, inflammatory, or neoplastic phenomena, more common in adults (ARAÚJO et al. 2014). The lifetime risk of diverticulum complications including bleeding, obstruction, and diverticulitis are approximately 4% to 6%; 40% of these complications are seen in children under ten years of age (KURU and KISMET, 2018).

The most common complication of Meckel's diverticulum in adults is an intestinal obstruction, while this presentation occurs as the second most common complication in childhood. Intestinal obstruction resulting from Meckel's diverticulum occurs through mechanisms such as: intussusception, volvulus, abdominal wall hernia, Meckel's diverticulitis, among others (KURU and KISMET, 2018). Acute diverticulitis, a sudden inflammation of the diverticulum that must be detected in the differential diagnosis of acute appendicitis, is found in 13-31% of the cases that evolve with complications, with a higher incidence in the fourth and fifth decades of life, and is difficult to diagnose. Complicated MD should be considered when an apparently normal appendix is found in a patient with clinical suspicion of acute appendicitis. MD diverticulitis can be triggered by enterolith, a foreign body or parasite, which causes obstruction of the diverticulum and determines inflammation of the ileal mucosa (ARAÚJO et al. 2014).

In children, bleeding is the most frequent complication (45-50%), followed by obstruction and infection. Episodes of hemorrhage occur especially under two years of age, possibly associated with gastric (60-65%) or pancreatic (5%) heterotopic mucosal ulceration. Gastric acid and pancreatic alkaline secretions would cause ulceration in the adjacent ileal mucosa, which may explain the bleeding episodes (ARAÚJO et al. 2014).

Drilling of MD is extremely rare. Most often, perforation occurs when a dung obstructs the diverticulum, leading to inflammation and necrosis. More rarely, the perforation is due to foreign body perforation. The risk of developing a tumor in MD is higher than in any other part of the small intestine. Carcinoid metaplasia is the most common, accounting for two-thirds of the tumors that develop in MD (LEQUET et al. 2017).



The probability of onset of lifelong complications is assessed at 4%, maximum before the age of two, approximately 1% around the age of 40 and progressively decreasing to almost zero after the age of 70 (LEQUET et al. 2017).

The diagnosis of MD depends on the occurrence of complications and is fundamentally based on imaging tests. The main complementary tests are: abdominal ultrasound, abdominal computed tomography, scintigraphy, and abdominal angiograms, which become relevant in the face of diverticulitis, intestinal invagination/intussusception, obstruction, and digestive bleeding. Scintigraphy is considered the gold standard in MDs with heterotopic gastric mucosa (ARAÚJO et al. 2014).

MD is difficult to diagnose and remains a major challenge in medical practice (ARAÚJO et al. 2014). When inflamed, it can be detected using US, CT or scintigraphy (MIZERKOWSKI et al. 2011). Plain abdominal X-ray is generally nonspecific. Ultrasonography is a good method for diagnosing complications of MD, especially inflammatory processes and intestinal intussusception. Exploratory videolaparoscopy is considered an effective method for inspecting the cavity and has the advantage of simultaneously performing the diagnosis and its correction (ARAÚJO et al. 2014). Computed tomography is usually not useful in the diagnosis, unless there is an associated inflammatory or obstructive process. Most MD diagnoses made by CT are incidental (LORENZONI et al. 2019).

In the case of a digestive hemorrhage, there is an exam that is considered the gold standard to try to understand if the etiological cause of the condition is due to MD. This exam corresponds to a scintigraphy using a radioisotope - technese-99m pertechnetate. This imaging test is based on the assumption that many of the hemorrhagic diverticula contain ectopic gastric mucosa (LORENZONI et al. 2019).

The definitive treatment of MD is surgical. Access can be by laparoscopy or laparotomy, with equally satisfactory results. Simple diverticulectomy can be performed when there is no involvement of adjacent loops, although the preferred surgical technique, especially in cases of bleeding, diverticulitis, and suspected associated neoplasia, is segmental ileal resection with end-to-end anastomosis. The decision regarding the removal of incidentally diagnosed MD is controversial. There are several authors who recommend its resection, alleging that it is impossible to define macroscopically the absence of heterotopic mucosa in the diverticulum or that it will not present some type of complication in the future. Other authors argue that, due to the low probability of MD being symptomatic, approximately 800 diverticulectomies would be necessary to avoid a single complication. When the decision is made for the surgical procedure,



the morbidity and mortality associated with the surgical procedure should be considered (ARAÚJO et al. 2014).

Double-balloon enteroscopy has also been used for endoscopic full-thickness resection of inverted Meckel's diverticulum. Although endoscopic therapeutic procedures have been used recently, the main treatment for Meckel's diverticulum is surgical resection (KURU and KISMET, 2018).

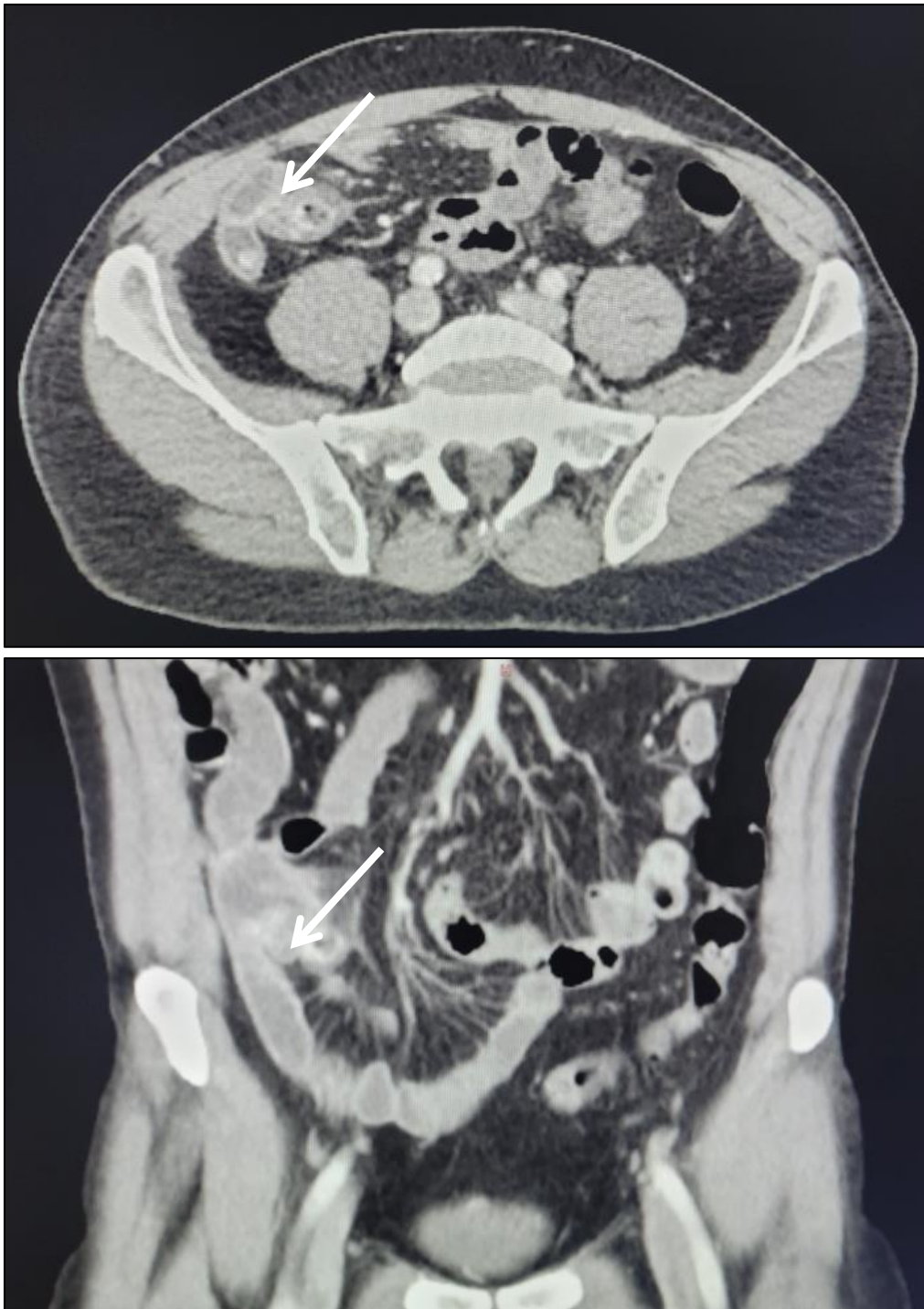
The real controversy surrounding Meckel's disease concerns the option of treating silent Meckel's disease with prophylactic resection when discovered during surgery. Some advise against prophylactic resection, arguing that the morbidity is too high and that the reward is too low (HANSEN and SØREIDE, 2018). There is general agreement that children with MD should undergo prophylactic removal, but the management of fortuitously discovered MD in adults is still debated. The benefit/risk ratio ranges from routine resection protecting the patient from possible late complications to abstention to avoid risks of any immediate or late complications related to surgery.

Therefore, the clinical circumstances of the case, the lifetime disease risk complications, and associated anatomical symptoms should be taken into account when asymptomatic diverticula are found during an abdominal exploration (KURU and KISMET, 2018).

## **CASE DESCRIPTION**

Patient M.F.P., male, 52 years old, with regular treatment for systemic arterial hypertension, using clindamycin and plasil. She sought emergency care on 06/25/2024 complaining of abdominal pain, with migration to the lumbar region and hypogastrium, denying nausea or vomiting, fever and diarrhea, with the initial diagnostic hypothesis of renal colic. Ultrasound of the urinary tract was performed, but without alterations. On the following day, there was worsening of abdominal pain, with subsequent migration to the right iliac fossa and hypogastrium, with peritonitis. On physical examination, the patient presented abdominal pain on palpation and positive abrupt decompression. Chest and abdominal X-rays were performed, in which they returned without alterations. A computed tomography scan of the total abdomen showed an image with an elongated aspect, which communicates with the small intestine on the right, adjacent to the ileum, with peripheral contrast uptake, measuring about 13.5 mm in its largest transverse axis, with densification of the fat around it, which may be related to a Meckel's diverticulum with an inflammatory process. The diverticulum is about 22 mm from the ileocecal valve. After that, an excision was performed by videolaparoscopy, with resection of the

diverticulum at the base with a videolaparoscopic stapler. Meckel's diverticulum was about 5 cm long and had a wide base with phlogistic signs and fibrin about 35 cm from the ileum cecal valve. The patient was discharged the day after surgery, denying pain, nausea, or vomiting, with good dietary acceptance.





## DISCUSSION

Because Meckel's diverticula are usually asymptomatic, particularly in adults, it can be found during a laparotomy performed for another reason (KURU and KISMET, 2018). Most individuals with MD remain asymptomatic for life (LORENZONI et al., 2019). Many surgeons advocate resection of an incidentally found diverticulum because of the potential for life-threatening complications that may occur (KURU and KISMET, 2018).

According to Hansen and Soreide, although symptomatic Meckel can occur at any age, it is most often associated with younger ages. Studies agree that the 3 most common presentations of symptomatic Meckel are caused by obstruction, GI hemorrhage, and inflammation with or without perforation (HANSEN and SOREIDE, 2018). The complication rate of MD is low, 0.03% per year, and the risk of being associated with some complication decreases with age, being insignificant in the elderly (ARAUJO et al., 2014). Therefore, in the case demonstrated, it is seen that this is a rarer report, given that it is a symptomatic elderly patient with the presence of an inflaming diverticulum.

The appearance of symptoms suggests complications. In pre-adolescents and adults, the most common complications are obstructive, inflammatory or neoplastic in nature. Therefore, it should be considered in the differential diagnosis of abdominal diseases, such as acute appendicitis. Meckel's diverticulum is commonly located in the terminal ileum, 40–100 cm from the ileocecal valve and, therefore, should be considered in the differential diagnoses of right iliac fossa conditions, such as appendicitis (LORENZONI et al., 2019). Therefore, based on the abdominal pain migrating to the right iliac fossa in the patient in the case, an ultrasound of the lower abdomen was performed to rule out the hypothesis of appendicitis.

The clinical manifestations are varied and appear during the first decade of life (especially in the first and second years) 50 to 60% of cases and are due to the gastric mucosa of the diverticulum at the level of the ileal junction with the ectopic gastric mucosa, causing bleeding due to ulceration. When the ectopic mucosa is composed of pancreatic tissue, it is associated with intestinal occlusion (LORENZONI et al., 2019).

Three types of operations have been described: segmental resection-anastomosis, wedge resection and tangential stapling. Whenever there is macroscopic involvement of the base of the diverticulum, a T-shaped segmental resection with intracorporeal anastomosis is the only possible solution by laparoscopy. In other cases, diverticular resection with linear stapling or wedge resection seems acceptable, even if there is a small risk of leaving residual heterotopic tissues. In this scenario, the mucosa of the intestinal segments adjacent to diverticulectomy



should be visualized to ensure that all macroscopically visible diseased mucosa has been removed (LEQUET et al., 2017).

Elective surgery is not recommended for cases where the diverticulum is discovered incidentally on radiological imaging. In general, it is not possible to determine the increased risk of complications associated with Meckel's diverticulum detected incidentally by palpation or intraoperative inspection. Therefore, for this reason, the intraoperative approach of asymptomatic patients or accidentally found remains of Meckel's diverticulum is a matter of debate (KURU and KISMET, 2018).

## **METHODOLOGY**

From a medical case that occurred at the Santa Casa da Misericórdia de Presidente Prudente, together with his medical record, information was collected to carry out this case report. In addition, a search for information was carried out in databases.

## **RESULTS**

Although MD represents the most common gastrointestinal congenital malformation, it is nevertheless rare and usually asymptomatic in adults. Ultrasonography and computed tomography are good methods for diagnosing complications of MD, especially inflammatory processes, intestinal intussusception, and corroborate the exclusion of other diseases. Exploratory videolaparoscopy is considered an effective method in the inspection of the cavity and has the advantage of simultaneously performing the diagnosis and its correction, where the definitive treatment is surgical, with absolute indication in symptomatic patients. In asymptomatic patients, surgical treatment is controversial, considering the potential for complications *versus* the risk of the surgical procedure.

## **CONCLUSION**

Meckel's diverticulum can be symptomatic or asymptomatic, since when symptomatic, it is most often associated with complications. It is essential that each case of Meckel's diverticulum be evaluated individually, taking into account variables such as gender, age (complications are more frequent in children and young men), anesthetic risk, and diverticulum characteristics for a better prognosis and better choice of treatment.



## REFERENCES

- AN, J., & ZABBO, C. P. (2023). Meckel diverticulum. In StatPearls. StatPearls Publishing. <https://www.statpearls.com/ArticleLibrary/viewarticle/25989>
- Araújo, L. M., Souza, R. R., & Silva, F. A. (2014). Divertículo de Meckel: Revisão de literatura. *Revista Médica de Minas Gerais*, 24(1), 93-97. <https://doi.org/10.5935/1679-9825.20140015>
- Fusco, J. C., Achey, M. A., & Upperman, J. S. (2022). Meckel's diverticulum: Evaluation and management. *Seminars in Pediatric Surgery*, 31(1), 151142. <https://doi.org/10.1016/j.sempedsurg.2022.151142>
- Hansen, C.-C., & Søreide, K. (2018). Systematic review of epidemiology, presentation, and management of Meckel's diverticulum in the 21st century. *Medicine*, 97(35), e12154. <https://doi.org/10.1097/MD.00000000000012154>
- Kuru, S., & Kismet, K. (2018). Meckel's diverticulum: Clinical features, diagnosis, and management. *Revista Española de Enfermedades Digestivas*, 110, 421-428. <https://doi.org/10.17235/reed.2018.5677/2017>
- Lequet, J., Boudet, M. J., Roustan, J. P., & Scherrer, J. R. (2017). Meckel's diverticulum in the adult. *Journal of Visceral Surgery*, 154(4), 253-259. <https://doi.org/10.1016/j.jviscsurg.2017.06.004>
- Lorenzoni, R., Cardoso, E. L., & Ferreira, T. G. (2019). Meckel diverticulum - A case report. *Residência Pediátrica*, 9(3), 316-318. <https://doi.org/10.5935/1678-4456.20190049>
- Mizerkowski, M. D., Silva, J. C., & Soares, M. L. (2011). Divertículo de Meckel ao Doppler em cores: Relato de dois casos. *Radiologia Brasileira*, 44(4), 268-270. <https://doi.org/10.1590/S0100-39842011000400013>