



Incidental finding of carcinoma in a patient with cholelithiasis and liver cirrhosis: A case report

Achado incidental de carcinoma em paciente com colelitíase e cirrose hepática: Um relato de caso

DOI: 10.56238/isevjhv3n4-018

Receipt of originals: 07/11/2024

Acceptance for publication: 08/01/2024

Helen Brambila Jorge Pareja¹, Eduardo Alves Canedo², Alexandre Henrique Bianchetti Giroto³, Amanda de Menezes Figueiredo⁴, Isadora Nascimento⁵.

ABSTRACT

Introduction: Gallbladder cancer (GC) is considered a malignant neoplasm that affects the bile ducts, being a rare and often lethal condition. This pathology represents a challenge in both diagnosis and treatment, this is due to patients usually being asymptomatic or presenting with nonspecific symptoms. Thus, most cases of GC are incidental findings, without previous diagnosis, in patients undergoing cholecystectomy for cholelithiasis. The definitive treatment considered the gold standard for GC is laparoscopic surgery, with removal of the gallbladder (cholecystectomy). The good results of the procedure are dependent on the neoplasm-free hepatic margin and adequate regional lymphadenectomy. **Objective:** To highlight the importance of adequate treatment for GC, since the improvement of the disease depends on the good results of the procedure. **Methods:** From a medical case that occurred at the Santa Casa da Misericórdia de Presidente Prudente, and its medical records, information was collected to carry out this report. **Results:** GC is considered a malignant neoplasm that represents a challenge in both diagnosis and treatment, as patients are usually asymptomatic or have nonspecific symptoms. The definitive treatment considered the gold standard for GC is laparoscopic surgery, with removal of the gallbladder (cholecystectomy). **Conclusion:** It was evident that it is necessary for a better understanding of the pathology, in addition to studies on the behavior of the GC and its identification in the profile of Brazilian individuals. This type of study would enable prevention, screening, and the adoption of an effective therapeutic indication.

¹ Master of Science in Health Sciences

University of Western São Paulo

ID Lattes: 8792800011270177

Email: brambila_hj@hotmail.com

² Graduated in Medicine

Universidad del Pacifico

ID Lattes: 7988075584280290

E-mail: weacan@gmail.com

³ Graduating from Medicine

University of Western São Paulo

ID Lattes: 7702408288710022

Email: alexandregiroto@hotmail.com

⁴ Medical Graduate

University of Western São Paulo

ID Lattes: 0119048422255155

Email: amanda.mfigueiredo@yahoo.com.br

⁵ Medical Graduate

University of Western São Paulo

ID Lattes: 278163493490

E-mail: isanasci785@gmail.com



Keywords: Gallbladder cancer, Cholecystectomy, Treatment.

INTRODUCTION

Gallbladder cancer (GC) is considered a malignant neoplasm that affects the bile ducts, being a rare and often lethal condition (APODACA-RUEDA et al. 2017). The incidence of this pathology is higher in women, the elderly, Caucasians, and varies considerably according to geographic region, being more prevalent in areas such as Japan, certain regions of India, South America, and Eastern Europe, while it is relatively uncommon in regions of Northern Europe and North America (COIMBRA et al. 2020).

This pathology represents a challenge in both diagnosis and treatment, this is due to patients usually being asymptomatic or presenting with nonspecific symptoms. Among the main symptoms observed, we find abdominal pain located in the upper right quadrant, progressing with acute cholecystitis. In more advanced cases, the patient may present cholangitis, and symptoms such as weight loss, nausea and vomiting, fever, ascites, and a palpable mass in the right upper quadrant are common at this stage. Laboratory tests can show alterations compatible with obstructive jaundice, such as leukocytosis, anemia, and liver function alterations (RODRIGUEZ et al. 2015).

Thus, most cases of GC are incidental findings, without prior diagnosis, in patients undergoing cholecystectomy for cholelithiasis (ARE et al. 2017) (SIEGEL et al. 2019) (NARAYAN et al. 2018). However, the disease progresses quickly and has a high mortality rate. It is estimated that up to 1/3 of patients have metastases at the time of diagnosis and that 85% of patients die within one year of their diagnosis. The poor prognosis of the pathology is mainly due to late diagnosis, which significantly compromises the efficacy of treatment and increases morbidity and mortality (COIMBRA et al. 2020) (ARROYO et al. 2016).

The pathogenesis of GC is not clearly established, but environmental (such as obesity and hyperglycemia) and genetic factors are associated with the occurrence of the pathology. The main risk factor identified is cholelithiasis, which is present in most cases. The risk increases according to the larger size (greater than 3 cm) and longer time of onset of gallstones (ARROYO et al. 2016). Patients with liver cirrhosis are 1.2 to 3 times more likely to have cholelithiasis than the general population and the more severe the existing liver disease (VD level of evidence), cholelithiasis is even more prevalent (ELMAGARMID et al. 2014).

The definitive treatment considered the gold standard for GC is laparoscopic surgery, with removal of the gallbladder (cholecystectomy). Then, all samples collected during surgery



should be sent for histopathological examination, which increases the detection rate of GC (COIMBRA et al. 2020) (HANI OWEIRA et al. 2018).

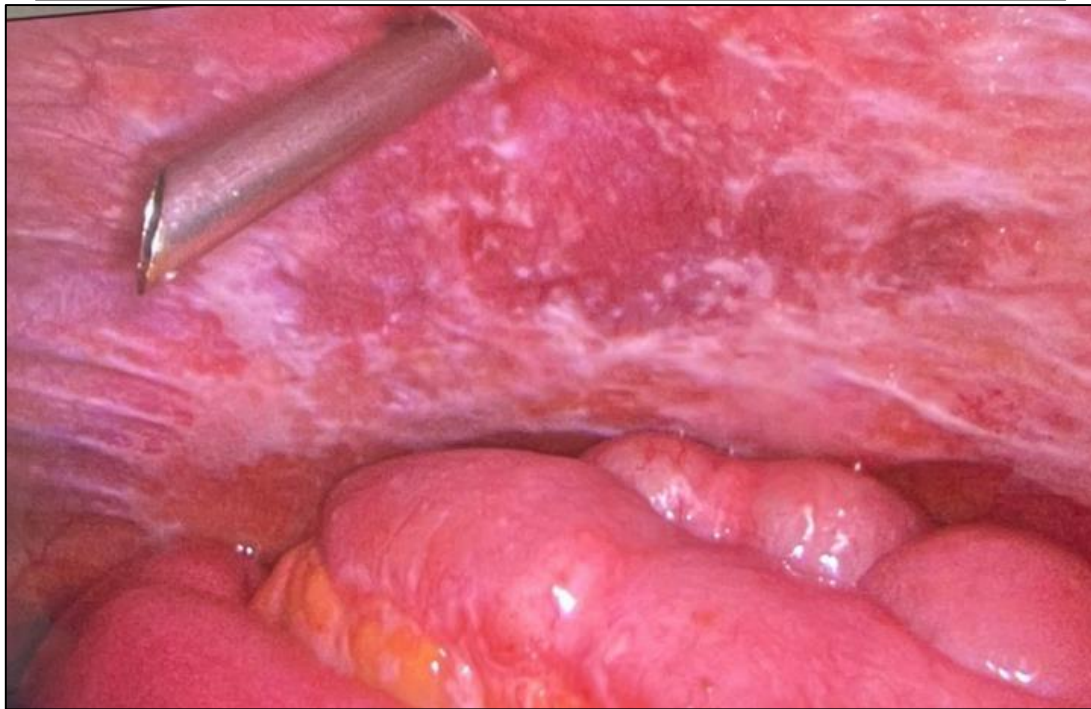
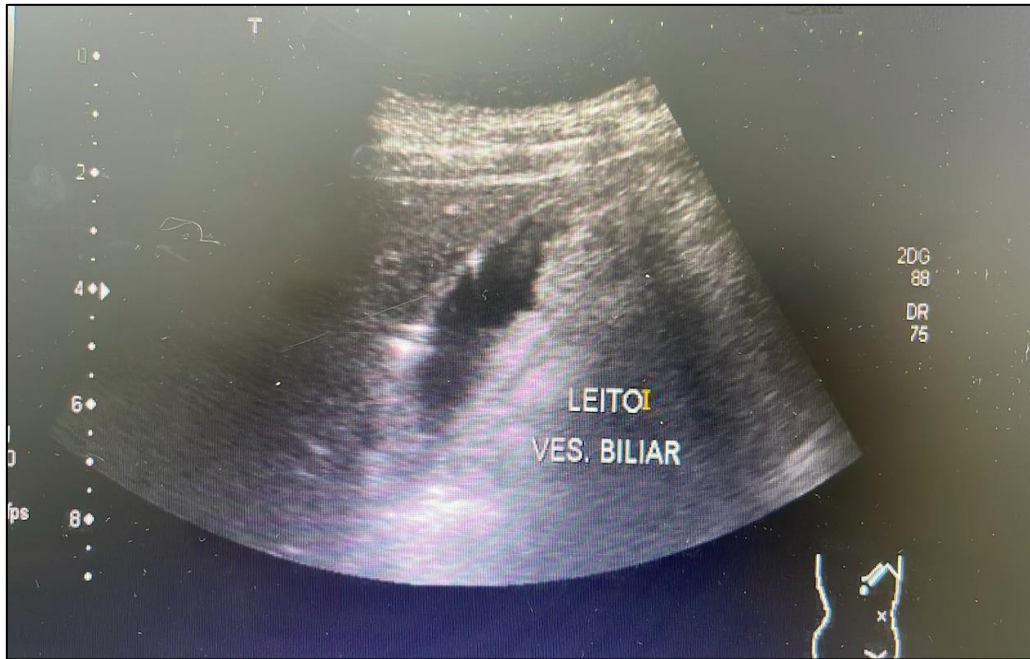Cholecystectomy can be done using two techniques: open or laparoscopic. The open operative technique has been gradually replaced by the laparoscopic technique due to its less invasive characteristics and an improvement in post-surgery responses, in addition to a relatively shorter recovery time (ALMEIDA et al., 2021).

For cases of superficial tumors, limited to the mucosa, simple cholecystectomy will be adequate, not requiring enlarged resection (hepatic) or hilar lymphadenectomy. However, in more advanced stages, in which there is involvement beyond the mucosal layer, most studies suggest that some type of liver resection complemented with hilar lymphadenectomy be included for treatment (TORRES et al. 2002) (SANTOS et al. 2008).

The good results of the procedure are dependent on the neoplasm-free hepatic margin and adequate regional lymphadenectomy. However, despite these interventions, overall survival for GC is low due to local invasion, peritoneal dissemination, and extensive early lymphatic infiltration (SANTOS et al. 2008).

CASE DESCRIPTION

Patient A.R.C., male, 61 years old, sought care in a private office reporting diffuse abdominal pain and weight loss for 2 months. On physical examination, the patient presented pain on abdominal palpation, being more intense in the right hypochondrium and positive Murphy's sign. In the preoperative ultrasound, he found a picture of cholecystopathy associated with liver cirrhosis. After 2 days, the patient was admitted to the Santa Casa da Misericórdia de Presidente Prudente for a videolaparoscopy cholecystectomy associated with intraabdominal fluid drainage due to acute cholecystitis with gallbladder perforation and peritonitis. The surgery was well and uneventful, and the patient recovered well and was discharged the day after surgery.



DISCUSSION

In the evaluation of personal and pathological history, the factors that could be considered risk for the patient in relation to the presence of a GC are: being 61 years old and living in a South American country (Brazil). GC is more common in the elderly, especially after the age of 60, and can vary considerably according to the geographic region where the patient resides, as in the case of the patient in this study (COIMBRA et al. 2020).



Patients with GC more often present symptoms that are barely noticeable or symptoms that are nonspecific to patients. Among the main nonspecific symptoms observed, we found abdominal pain located in the right upper quadrant and weight loss (RODRIGUEZ et al. 2015), as reported in the case where the patient presented diffuse abdominal pain and weight loss 2 months ago. In addition, on physical examination, the patient presented pain on abdominal palpation, which was more intense in the right hypochondrium and Murphy's sign was positive.

Most cases of GC are diagnosed late, which results in more advanced stages of the disease, in addition to contributing to treatment difficulties and a high mortality rate (APODACA-RUEDA et al. 2017). About 1/3 of patients are already in the process of metastasis by the time they are diagnosed. In addition, in 85% of these cases, death will come within one year after the pathology is identified (COIMBRA et al. 2020) (ARROYO et al. 2016). Diagnoses are usually made incidentally, soon after a cholecystectomy or by an anatomopathological study after evidence of a change in the gallbladder, detected during a radiological examination (BENASSI et al. 2022).

As liver cirrhosis and cholelithiasis are diseases that have a high prevalence in the population, the association between the two is not uncommon, especially if we consider that cirrhosis is a predisposing factor for the appearance of cholelithiasis. Liver cirrhosis (HC) is characterized by the progressive destruction of hepatocytes, which are replaced by fat and fibrous tissue and can lead to several serious complications, including the predisposition to the development of cancer in nearby organs. However, the direct link between liver cirrhosis and gallbladder cancer is not as clear as the relationship between liver cirrhosis and liver cancer (hepatocellular carcinoma). It increases the risk of liver cancer due to the chronic inflammation and constant cell regeneration that occur in the damaged liver. Although not a primary risk factor for gallbladder cancer, chronic liver disease and inflammatory biliary tract conditions such as primary sclerosing cholangitis can increase the risk of developing gallbladder cancer.

The most frequent condition of cirrhosis is chronic alcoholism (MOORE). Cirrhotic liver has great variation in volume and weight. The organ can reach more than 2 kg, while in the terminal stages of the process it can be reduced to 600 to 800 g (BOGLIOLO). As the disease progresses, the organ becomes hardened, atrophied and nodular, and exhibits a deficient function due to a decrease in functional liver tissue (FERNANDES). Patients with HC may present a variety of symptoms, which include: abdominal pain, weight loss, jaundice, and bruising. In addition, in addition to alcoholism, several other existing etiologies justify the appearance of cirrhosis, such as: viral hepatitis (viruses B and C), autoimmune hepatitis,



hepatotoxic drugs, cholestatic diseases, genetic abnormalities, non-alcoholic fatty liver diseases and non-alcoholic steatohepatitis (FERNANDES).

The importance lies in the fact that biliary surgery in cirrhotic patients tends to have an increased risk for transoperative and postoperative complications (FONTES et al. 1998). In critically ill patients with few symptoms related to cholelithiasis, the initial treatment should be clinical with the use of antibiotics and later analyze the need for surgery. In addition, oral administration of bile salts reduces bile cholesterol saturation, in other words, it inhibits the synthesis and excretion of hepatic cholesterol and consequently reduces liver activity. When bile becomes unsaturated, stones in the gallbladder tend to dissolve slowly. However, this drug treatment may be ineffective in pigmentary stones and contraindicated in the presence of cirrhosis, and is not indicated in the case described above.

Cholelithiasis can also favor the development of gallbladder cancer. The presence of gallstones is associated with chronic inflammation and irritation of the gallbladder wall, which can lead to cellular changes and eventually the development of carcinomas. The ongoing inflammation caused by gallstones results in chronic cholecystitis, which is a known risk factor for gallbladder cancer. In addition, gallstones larger than 3 cm, and present in large quantities, further increase this risk.

After verifying a picture of cholecystopathy associated with liver cirrhosis, the therapeutic approach considered the gold standard is laparoscopic surgery, with removal of the gallbladder (cholecystectomy) (COIMBRA et al. 2020) (HANI OWEIRA et al. 2018). This surgical procedure is minimally invasive, helping in an action with less tissue damage and also a quick postoperative recovery (ALMEIDA et al. 2021). Even so, it is important to highlight the possible complications that may occur during the surgical intervention, such as biliary fistulas, which can be caused by the loss of the cystic duct clip, perforation of the bile duct or the presence of hepatic bed canaliculi. The presence of intracavitary stones can lead to the formation of abscesses and bleeding can occur both from the hepatic bed and from the cystic artery. However, the most significant and most feared is the lesion of the main bile duct, which leads to high morbidity and mortality (PINOTTI et al. 2000). The closure of the peritoneum over the hepatic bed and the intraoperative use of IV vasopressin, reducing the pressure in the portal system, are also measures that can help prevent hemorrhage.

Peritoneal carcinomatosis (PC) consists of the presence of tumor implants in the peritoneum that can be of both primary and secondary origin. The vast majority are caused by



secondary (metastatic) tumors, that is, tumor cells from other carcinomas that have spread to the membrane (CÉSAR. 2022).

The peritoneum has an extensive surface area with vast lymphatic drainage, facilitating invasion by tumor cells. The types of secondary peritoneal carcinomatosis vary according to the site of origin of the disease. For good survival and tumor growth, cancer cells produce a set of factors that disrupt the functioning of the peritoneal blood barrier, leading to neogenesis and the creation of an immunosuppressive microenvironment, rich in peritoneal mesothelial cells, fibroblasts, and peritoneal macrophages (CÉSAR. 2022).

There are comparative studies between conventional and laparoscopic surgery. Of particular note is a study carried out by Gouma® and collaborators, at the Academic Medical Center in Amsterdam and University Hospital in Maas-tricht, around the 2000s, which evaluated 122 centers, with a total of 11,712 cholecystectomies, 2,932 laparoscopic and 8,780 conventional; showed a higher percentage of lesions of the main bile duct, reaching 1.09% as a result of the laparoscopic procedure, against 0.51% of the conventional surgery. This may be debatable since the evaluation carried out is in the period belonging to the learning curve, about professionals, instruments and equipment, against a well-established method for almost 100 years (PINOTTI et al. 2000). However, more recent studies have proven that laparoscopic surgery is currently the gold standard and the most chosen among health professionals because it is considered less invasive and with lower rates of surgical complications.

In this patient, intraabdominal fluid drainage was also performed due to acute cholecystitis with gallbladder perforation and peritonitis. However, the drainage of the hepatic bed is a controversial topic, since it allows the detection and drainage of bleeding in the surgical field, it also allows postoperative leakage of ascites through the drainage hole. After surgery, the patient was discharged from the hospital and provided dietary guidance.

METHODOLOGY

From a medical case that occurred at the Santa Casa da Misericórdia de Presidente Prudente, together with his medical record, information was collected to carry out this case report. In addition, a search for information was carried out in databases.

RESULTS

Gallbladder cancer is considered a malignant neoplasm that poses a challenge in both diagnosis and treatment, as patients are usually asymptomatic or have nonspecific symptoms.



The definitive treatment considered the gold standard for GC is laparoscopic surgery, with removal of the gallbladder (cholecystectomy) and the good results of the procedure depend on the hepatic margin free of neoplasia and adequate regional lymphadenectomy.

CONCLUSION

The case reported and the publications on gallbladder cancer (GC) raise important questions about the therapeutic approach and the role of early diagnosis for a successful approach. Although the pathogenesis of GC has not yet been clearly established, there are indications of an association between environmental and genetic factors in the development of the pathology. Cholelithiasis is the main risk factor identified for GC, thus increasing the burden of early diagnosis of this finding. In the patient of the case presented, a picture of cholecystopathy associated with liver cirrhosis was found, with cirrhosis being a risk factor for the development of cholelithiasis.

It was evident that it is necessary for a better understanding of the pathology, in addition to studies on the behavior of the GC and its identification in the profile of Brazilian individuals. This type of study would enable prevention, screening, and the adoption of an effective therapeutic indication.



REFERENCES

- Almeida, D. P. A. de, Silva, L. A., & Oliveira, F. M. (2021). Colectomia: Técnicas e suas indicações / Cholecystectomy: Techniques and their indications. *Brazilian Journal of Health Review*, 4(6), 25953–25957. <https://doi.org/10.5935/1678-4464.20210012>
- Apodaca-Rueda, M., Carvalho, M. R., & Mendonça, S. A. (2017). Prevalência do câncer de vesícula biliar em pacientes submetidos à colecistectomia: Experiência do Hospital de Clínicas da Faculdade de Ciências Médicas da Universidade Estadual de Campinas – UNICAMP. *Revista do Colégio Brasileiro de Cirurgiões*, 44(3), 252–256. <https://doi.org/10.1590/0100-69912017003007>
- Are, C., Gonen, M., & D'Angelica, M. (2017). Global epidemiological trends and variations in the burden of gallbladder cancer. *Journal of Surgical Oncology*, 115(5), 580–590. <https://doi.org/10.1002/jso.24595>
- Arroyo, G. F., Gentile, A., & Parada, L. A. (2016). Gallbladder cancer: South American experience. *Chinese Clinical Oncology*, 5(5), 67. <https://doi.org/10.21037/cco.2016.10.04>
- Benassi, A. C., Silva, M. A., & Campos, J. A. (2022). Câncer de vesícula biliar - diagnóstico diferencial de icterícia obstrutiva: Relato de dois casos / Gallbladder cancer – Differential diagnosis of obstructive jaundice: Report of two cases. *Brazilian Journal of Health Review*, 5(6), 24395–24406. <https://doi.org/10.5935/1678-4464.20220012>
- César, J. R. M. (2022). Tratamento Cirúrgico da Carcinomatose Peritoneal do Carcinoma Colorretal (Master's thesis). Universidade Estadual de Campinas.
- Coimbra, F. J. F., Andrade, A. M., & Silva, A. C. (2020). Brazilian consensus on incidental gallbladder carcinoma. *ABCD. Arquivos Brasileiros de Cirurgia Digestiva (São Paulo)*, 33(1). <https://doi.org/10.1590/0102-6720200001>
- Elmagarmid, A., & Koonin, L. M. (2014). Rayyan: A systematic reviews web app for exploring and filtering searches for eligible studies for Cochrane Reviews. In *Evidence-Informed Public Health: Opportunities and Challenges. Abstracts of the 22nd Cochrane Colloquium* (pp. 21–26). John Wiley & Sons.
- Fernandes, I. C. (2021). Cirrose Hepática: Fisiopatologia e cuidados de enfermagem (Undergraduate thesis). Universidade Federal de Minas Gerais.
- Filho, G. B. Bogliolo. (2021). Patologia. Grupo GEN. ISBN 9788527738378. Available at: <https://integrada.minhabiblioteca.com.br/#/books/9788527738378/>. Accessed on: July 13, 2024.
- Fontes, P. R. O., Nectoux, M., & Eilers, R. J. (1998). Colelitíase e cirrose hepática. *Revista do Colégio Brasileiro de Cirurgiões*, 25(2), 129–133. <https://doi.org/10.1590/S0100-69911998000200006>
- Graaff, K. M. Van de. (2003). Anatomia Humana. Editora Manole. ISBN 9788520452677. Available at: <https://integrada.minhabiblioteca.com.br/#/books/9788520452677/>. Accessed on: July 13, 2024.



- Hani Oweira, M., & Boffa, D. J. (2018). External validation of the 8th American Joint Committee on Cancer staging system for gall bladder carcinoma. *Journal of Gastrointestinal Oncology*, 9(6), 1084–1090. <https://doi.org/10.21037/jgo.2018.11.10>
- Moore, K. L., Dalley, A. F., & Agur, A. M. R. (2022). *Anatomia Orientada para Clínica*. Grupo GEN. ISBN 9788527734608. Available at: <https://integrada.minhabiblioteca.com.br/#/books/9788527734608/>. Accessed on: July 13, 2024.
- Narayan, R. R., Klein, R., & Deshpande, V. (2018). Regional differences in gallbladder cancer pathogenesis: Insights from a multi-institutional comparison of tumor mutations. *Cancer*, 125(4), 575–585. <https://doi.org/10.1002/cncr.31986>
- Pinotti, H. W., & Lima, R. (2000). Colectomia laparoscópica: Estruturação de um modelo de trabalho. *Revista do Colégio Brasileiro de Cirurgiões*, 27, 94–98. <https://doi.org/10.1590/S0100-69912000000100013>
- Rodriguez, S., Arnaiz, A., & Hernandez, M. (2015). Lipids, obesity and gallbladder disease in women: Insights from genetic studies using the cardiovascular gene-centric 50K SNP array. *European Journal of Human Genetics*, 24(1), 106–112. <https://doi.org/10.1038/ejhg.2015.35>
- Santos, J. S., Oliveira, L. A., & Sousa, J. F. (2008). Colectomia: Aspectos técnicos e indicações para o tratamento da litíase biliar e das neoplasias. *Medicina (Ribeirão Preto)*, 41(4), 449–464. <https://doi.org/10.11606/issn.2176-7262.v41n4p449-464>
- Siegel, R. L., Miller, K. D., & Jemal, A. (2019). Cancer statistics, 2019. *CA: A Cancer Journal for Clinicians*, 69(1), 7–34. <https://doi.org/10.3322/caac.21551>
- Silverthorn, D. U. (n.d.). *Fisiologia humana*. Grupo A. ISBN 9788582714041. Available at: <https://integrada.minhabiblioteca.com.br/#/books/9788582714041/>. Accessed on: July 13, 2024.
- Torres, O. J. M., Castro, S. J., & Almeida, J. P. (2002). Colelitíase e câncer de vesícula biliar. *Revista do Colégio Brasileiro de Cirurgiões*, 29(2), 88–91. <https://doi.org/10.1590/S0100-69912002000200006>