



Chronic ankle ligament injury and its clinical management: A literature review

DOI: 10.56238/isevjhv3n4-026

Receipt of originals: 06/11/2024

Acceptance for publication: 07/31/2024

Angelo Augusto Martins Pistori, Guilherme Prianti de Andrade, Thiago Ferreira Delneri, Karlos Adryano Priscinotte Rodrigues Lima, Leonardo Oliveira Coelho, Heitor Ribeiro Mendonça, Gabriella Fernandes Trindade, Wander Arraes Gonçalves, Pedro Pereira Barbosa, Ítalo Nunes Vieira, Ricardo Hypolitho de Carvalho, André Luiz Cruz Esteves, Renan da Silva Andrade, Ana Laura Gontijo de Faria, Guilherme Silva Miranda and Stephany Fernandes de Paiva

ABSTRACT

INTRODUCTION: It is necessary to understand the principles of chronic ligament injuries involving the ankle, which happen when there is damage or weakening, which can happen due to repeated or untreated injuries (AMODIO, 2013). In general, chronic ligament injuries occur due to recurrent sprains or sprains of the ankle. Ligaments are fibrous tissues that connect bones and provide stability to joints. In the ankle, the ligaments usually affected are the anterior talofibular ligament and the calcaneofibular ligament. **METHODOLOGY:** This is a literature review, whose databases were taken from the SciELO and PubMed data platforms. The research period was from July 2023, meeting the inclusion criteria, which were articles from the years 2000 to 2023, in Portuguese and English, online texts, and in full texts. The following health descriptors (DeCS) were used as strategies for better evaluation of the texts: "Ligament injury", "Ankle" and "Chronic". **RESULTS:** Ankle sprains, which are very common in athletes and individuals with an active life, are an injury caused, in most cases, by eversion or inversion of the foot due to sudden and violent movements, which may or may not cause ligament rupture (BARONI, 2010). Acute ankle ligament injuries are common, with the most prevalent being injuries to the lateral ligament complex. In the neutral position, the bony anatomy of the ankle joint is responsible for stability. Bone stability is increased by compressive loads in the body load position. Most lateral ligament injuries of the ankle resolve spontaneously with conservative treatment (LYNCH, 1999), and such conservative treatment leads to the mechanical stability of this joint in a large percentage of cases. (AMODIO, 2013). On the other hand, persistent problems after ankle ligament injuries are not uncommon. After both conservative and surgical treatment, 10% to 30% of patients with lateral ligament injury may present with chronic symptoms (Lynch, 1999). **CONCLUSION:** By understanding the treatment modalities, it is understood that the chronicity of ankle ligament injuries require surgical treatment in severe cases in an acute way, the cases in which more extensive injuries are involved in time, require different treatment modalities, in order to prevent progression and instability in the patient.

Keywords: Ligament Injury, Ankle, Chronic Injury.

INTRODUCTION

It is necessary to understand the principles of chronic ligament injuries involving the ankle, these happen when there is damage or weakening, which can happen due to repeated or untreated injuries (AMODIO, 2013). In general, chronic ligament injuries occur due to recurrent sprains or sprains of the ankle.

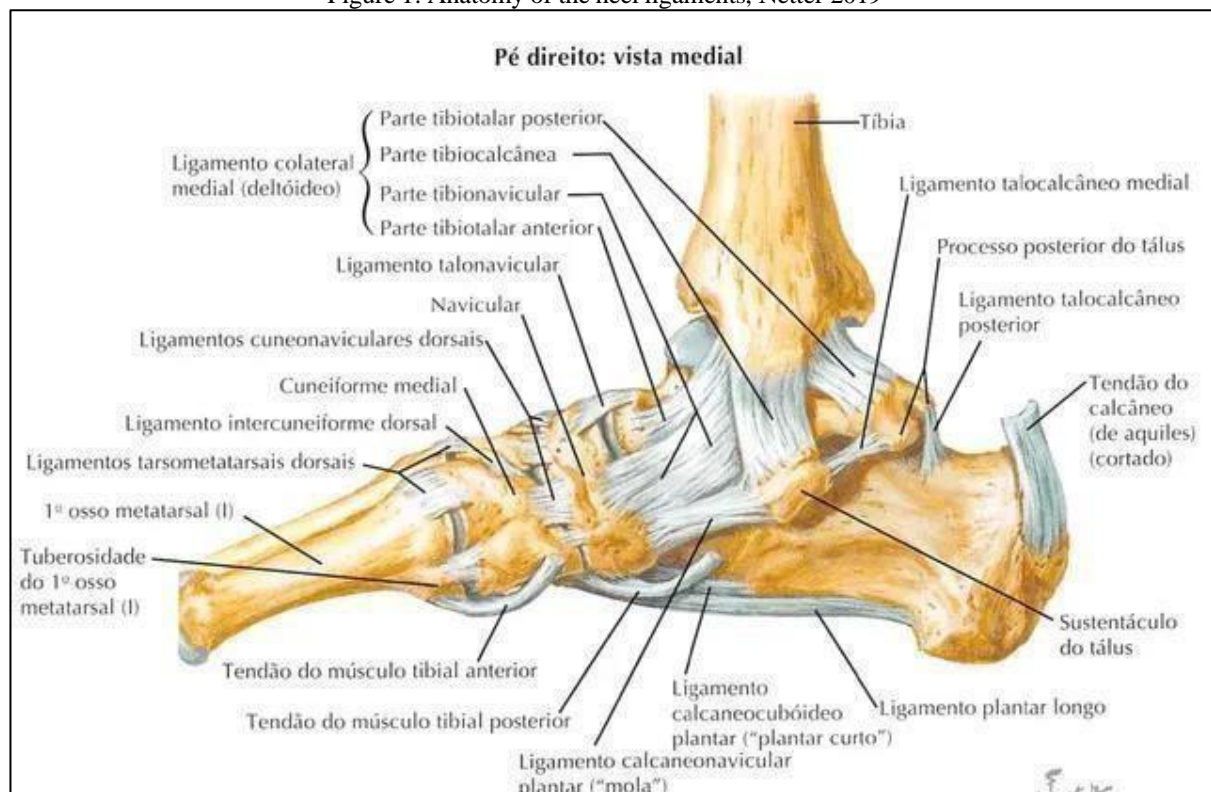
Ligaments are fibrous tissues that connect bones and provide stability to joints. In the ankle, the ligaments usually affected are the anterior talofibular ligament and the calcaneofibular ligament.

In cases of injury without treatment or follow-up, the healing process of the ligaments is strongly impaired and the formation of scar tissue is weak or disorganized, causing a chronic and unstable condition (MARTINS, 2020).

The treatment for this type of lesion involves conservative and chronic treatment, about the two types that hover the most discussed and conditional.

It is understood that surgical cases are for more severe conditions, in which instability persists even after conservative treatment (AMODIO, 2013).

Figure 1: Anatomy of the heel ligaments, Netter 2019



METHODOLOGY

This is a literature review, whose databases were taken from the SciELO and PubMed data platforms. The research period was from July 2023, meeting the inclusion criteria, which were articles from the years 2000 to 2023, in Portuguese and English, online texts, and in full texts. The following health descriptors (DeCS) were used as strategies for better evaluation of the texts: "Ligament injury", "Ankle" and "Chronic".

RESULTS AND DISCUSSION

Ankle sprains, very frequent in athletes and individuals with an active life, is an injury caused, most of the time, by the eversion or inversion of the foot due to sudden and violent movements, which may or may not cause ligaments to rupture (BARONI, 2010).

Acute ankle ligament injuries are common, with the most prevalent being injuries to the lateral ligament complex. In the neutral position, the bony anatomy of the ankle joint is responsible for stability. Bone stability is increased by compressive loads in the body load position. Most lateral ligament injuries of the ankle resolve spontaneously with conservative treatment (LYNCH, 1999), and such conservative treatment leads to the mechanical stability of this joint in a large percentage of cases. (AMODIO, 2013).

On the other hand, persistent problems after ankle ligament injuries are not uncommon. After both conservative and surgical treatment, 10% to 30% of patients with lateral ligament injury may present chronic symptoms (Lynch, 1999).---

Chronic ankle instability due to sequelae of lateral ligament complex injury is relatively rare and occurs most of the time after acute ligament injury, probably not treated correctly (CILLO, 1996). In patients with persistent problems or unusual symptoms, other problems should be considered, stress fractures (particularly Jone's fracture), osteochondral fractures, osteochondritis dissecans, midfoot sprain, and tendinitis or subluxation of the peroneal muscles (Lynch, 1999).

Some patients remain with pain or instability after six months of treatment for acute ligament injury. Possible associated injuries are usually in decreasing order of frequency: chronic instability, osteochondral injury, impingement with distal tibiofibular inflammatory process, and anterior impingement with exostosis. (DIRETRIZES, 2008).

Symptoms usually include persistent synovitis or tendonitis, ankle stiffness, edema, pain, muscle weakness, and frequent falsehoods. Many of these problems are associated with ankle instability. It is important to differentiate the two types of ankle instability – mechanical and

functional. Mechanical instability refers to abnormal laxity of ligament stabilizers and functional instability to normal but abnormally functioning ligament stabilizers with recurrent episodes of falsehood. Isolated mechanical instability is of minimal clinical importance, but often mechanical and functional instability occur together. It is also important to consider the subtalar joint as part of the cause of instability (Lynch, 1999). Chronic pain is a common feature in patients with ICH, being present in about 60% and often associated with conflict syndrome. If there is no adequate treatment, there will be the development of an inflammatory process that, in turn, will lead to the formation of scar tissue that will occupy the space between the ligaments of the CLL (meniscoid injury), thus exacerbating pain and local inflammation (MARTINS, 2020).

It is difficult to separate subtalar instability from lateral ankle ligament instability, and in fact, these problems can coexist. The symptoms of both are chronic episodes of ankle distortion during activities, with a history of recurrent injuries and/or pain, edema and stiffness (Lynch, 1999).

An incorrect diagnosis regarding the severity of the injury, as well as an omission by the patient in relation to his injury, can lead to inadequate treatment and, consequently, to chronic instability of ATPA. (CILLO, 1996). Ligament injuries are classified according to severity as grade 1, stretching of the affected ligament, and grade 2, partial lesions, without joint instability. Complete injuries are classified as grade 3, when there is impairment of joint stability. (AMODIO, 2013). —

The main objective of ankle sprain treatment is to prevent chronic ankle instability, which will later lead to fractures, ligament injuries, or both. In order to treat an ankle sprain, physical therapy resources (conservative treatment) are used that promote an early return to daily activities, preventing the patient from being submitted to a more aggressive surgical procedure (CRISTINA, 2001).

For the treatment of grade I and II lesions, the prognosis is excellent, where resources are used to reduce edema, such as cryotherapy, bandages and elevation of the limb, followed by a period of immobilization with bands or orthoses. Subsequently, with the reduction of pain, flexibility movements begin, with progressive loading and proprioception (CRISTINA, 2001).

In grade III sprains, both conservative and surgical treatment are used, depending on the clinical picture. Conservative treatment is based on the use of cryotherapy, bandaging, early positioning and mobilization. Surgical treatment consists of ligament sutures or ligament reconstruction, according to the level of joint rupture and instability (CRISTINA, 2001).

Although anamnesis and physical examination are essential in the diagnosis, it is important to perform an imaging evaluation, not only to describe the lesions present, but also to exclude associated pathologies. For this, and depending on the objective, we can use load and stress radiographs, ultrasound, MRI and arthroscopy. (MARTINS, 2020).

Conservative treatment includes the application of the RICE principle (rest, ice-freeze, compression, and elevation), a short period of immobilization (1 to 2 weeks), followed by early joint mobilization, progressive load increase, and muscle strengthening in conjunction with proprioception exercises. Usually this approach is enough for patients to resume their daily activity and sports and the injury to heal. When conservative treatment does not have the desired results or in the case of a high-level athlete, we must consider surgical treatment. (MARTINS, 2020).

The need and duration of immobilization depends on the degree of injury. A grade I sprain does not require immobilization, so we can only recommend the use of an elastic bandage for a few days. For grade II sprains, a more rigid immobilization may be necessary during the first few days, until the pain resolves.⁹ In case of fracture or grade III sprains, the range of motion of the joint should be controlled by applying a cast or immobilizing boot. (MARTINS, 2020).

Physical therapy should be started as soon as possible in order to improve range of motion and minimize the risk of muscle loss. This should include amplitude exercises and proprioception training, and should last between 3-6 weeks (MARTINS, 2020). Although the literature is scarce in relation to clinical trials related to the topic in theory, the responses to stimuli generated by proprioceptive training cover mechanisms of physiological effects and evidence its effectiveness in improving neuromuscular control and balance, increasing joint stability (ROCHA, 2023).

FINAL CONSIDERATIONS

By understanding the treatment modalities, it is understood that the chronicity of ankle ligament injuries require surgical treatment in severe cases in an acute way, the cases in which more extensive injuries are involved in time, require different treatment modalities, in order to prevent progression and instability in the patient.

REFERENCES

- Renström PAFH, Lynch SA. Lesões ligamentares do tornozelo. Rev Bras Med Esporte [Internet]. 1999Jan;5(1):13–23. Available from: <https://doi.org/10.1590/S1517-86921999000100004>
- BARONI, Bruno Manfredini. Adaptações neuromusculares de flexores dorsais e plantares a duas semanas de imobilização após entorse de tornozelo. Rev Bras Med Esporte, v.16, n.5, set./out. 2010. Disponível em: <http://www.scielo.br/scielo.php?script=sci_arttext&pid=S1517-86922010000500008>.
- Horizonte B. ENTORSE DE TORNOZELO: MELHORES CONDUTAS TERAPÊUTICAS - uma revisão narrativa [Internet]. 2016. Available from: https://repositorio.ufmg.br/bitstream/1843/BUBD-AQCGLT/1/tcc_finalizado_29_12_2016.pdf
- Diretrizes P. Entorse de Tornozelo Autoria: Sociedade Brasileira de Ortopedia e Traumatologia [Internet]. 2008. Available from: https://amb.org.br/files/_BibliotecaAntiga/entorse-de-tornozelo.pdf
- Cillo R. Tratamento cirúrgico das lesões ligamentares crônicas laterais do tornozelo pela técnica de Bröstrom. Revista Brasileira de Ortopedia [Internet]. 1996;31(10). Available from: <https://www.rbo.org.br/detalhes/1888/pt-BR/tratamento-cirurgico-das-lesoes-ligamentares-cronicas-laterais-do-tornozelo-pela-tecnica-de-brostrom>
- Amodio M. INSTABILIDADE MECÂNICA PÓS LESÃO LIGAMENTAR AGUDA DO TORNOZELO. COMPARAÇÃO PROSPECTIVA E RANDOMIZADA DE DUAS FORMAS DE TRATAMENTO CONSERVADOR. Revista Brasileira de Ortopedia [Internet]. 2013 [cited 2023 Jul 12];48(4):307–16. Available from: <https://rbo.org.br/detalhes/1543/pt-BR/instabilidade-mecanica-pos-lesao-ligamentar-aguda-do-tornozelo--comparacao-prospectiva-e-randomizada-de-duas-formas-de-tratamento-conservador->
- Cristina E, Garcia B, Oliveira R, Patrizi V, Fernando O, Ferrari P, et al. MECANISMOS DE LESÃO DAS ENTORSES DE TORNOZELO NAS PRÁTICAS ESPORTIVAS ESPECÍFICAS [Internet]. 2001. [cited 2023 Jul 12]. Available from: <https://www.multitemas.ucdb.br/multitemas/article/download/1001/965>
- Martins D. Instabilidade Crônica do Tornozelo [Internet]. 2020. Available from: <https://repositorio-aberto.up.pt/bitstream/10216/128479/2/411972.pdf>
- ROCHA, Alessandra Lima da. Efeitos dos exercícios proprioceptivos na prevenção de lesões no tornozelo: uma revisão integrativa. 2023.
- ROCHA, Alessandra Lima da. Efeitos dos exercícios proprioceptivos na prevenção de lesões no tornozelo: uma revisão integrativa. 2023.
- BOCHI, Gabriela Silva; ALFENAS, Federal de Alfenas; GERAIS, Minas. Fatores de risco nas entorses de tornozelo em crianças e adolescentes atletas: uma revisão integrativa.



FERREIRA, Matheus Pouquiviqui et al. FISIOTERAPIA DESPORTIVA: PREVENÇÃO E TRATAMENTO DAS ENTORSES DE TORNOZELO. Revista Multidisciplinar Saberes da Faculdade Estácio do Pantanal, v. 10, n. 1, 2022.