



Extensive septic pelvic thrombophlebitis in a puerperal woman: a case report

Tromboflebite pélvica séptica extensa em puérpera: relato de caso

DOI: 10.56238/isevjhv2n2-008

Receiving the originals: 06/03/2023

Acceptance for publication: 28/03/2023

Bruna Benigna Sales Armstrong
Email: brunabenigna38@gmail.com

Isabela Ceccato Barili

Claudia Ariel Tienne Monteiro

Fábio Arcoverde

Coutinho de Meneses

Nayana de Oliveira Costa

José Arimatea dos Santos Júnior

ABSTRACT

OBJECTIVE: This article aims to report an extensive case of septic pelvic thrombophlebitis, a rare, severe, and challenging diagnostic condition. The clinical picture may range from mild to severe sepsis. Its diagnosis is of exclusion, but it can be complemented with imaging exams. **CASE DESCRIPTION:** We report a case of postpartum thrombophlebitis in the infrarenal portion of the inferior vena cava, external and internal common iliac veins, bilateral common femoral veins, as well as in the right ovarian vein, presenting with persistent fever and negative cultures. The patient showed significant clinical improvement after association of anticoagulation and antibiotic therapy. **CONCLUSION:** Septic pelvic thrombophlebitis is an important differential diagnosis for abdominal pain and fever in the postpartum period, but the absence of specific complementary tests makes its diagnosis challenging, which often leads to misdiagnosis of acute appendicitis, endometritis, pelvic inflammatory disease, pyelonephritis, nephrolithiasis, adnexal torsion, or pelvic abscess. The key to correct diagnosis is a high level of clinical suspicion, especially when there is resistance to broad-spectrum antibiotic therapy and remission after systemic anticoagulation. Given the large number of cesarean sections performed today and their correlation with septic pelvic thrombophlebitis, an increase in the number of cases should be accompanied by greater familiarity of health professionals with this complication, in order to avoid inadequate propaedeutics and conducts. In this context, the present case report documents the importance of investigating pelvic septic thrombosis in patients with fever in the puerperium and its differential diagnoses for early initiation of therapy to reduce morbidity and mortality.

Keywords: Thrombophlebitis, Puerperal Infection, Sepsis.



1 INTRODUCTION

Septic pelvic thrombophlebitis is a rare condition with a challenging diagnosis. It was first described in the 19th century, when a picture of fever was observed after obstetric or gynecological procedures, associated with pelvic vein thrombosis and the presence of purulent material identified in the pelvic cavity during exploratory laparotomy⁽¹⁾.

It consists of a persistent febrile syndrome associated with abdominal pain in a postoperative setting in the population described above. The clinical picture may vary from mild to severe sepsis². Its diagnosis is of exclusion, but it is possible to complement it with imaging exams, such as Computed Tomography or Magnetic Resonance to investigate thrombi in the vascular bed⁽³⁾.

Two types of septic pelvic thrombophlebitis have been described: Ovarian Vein Thrombophlebitis and Deep Septic Pelvic Thrombophlebitis, with similar pathophysiologic mechanisms but variable clinical presentation⁽⁴⁾.

The main risk factors include conditions in which there is activation of Virchow's triad, especially in postoperative cesarean or vaginal delivery. In addition, infectious conditions such as chorioamnionitis or endometritis, metastatic neoplastic complications and even gestational hypertensive syndromes are widely related⁽²⁾.

The treatment has been modified with the development of new research. Going from a surgical approach to clinical, with a significant reduction in mortality^(1,5).

We report a case of postpartum thrombophlebitis in the infrarenal portion of the inferior vena cava, external and internal common iliac veins, bilateral common femoral veins, as well as the right ovarian vein, presenting with persistent fever and negative cultures.

2 CASE DESCRIPTION

Patient ACL, 24 years old, G3P3 (N1C2) A0, is admitted to the maternity ward, transferred from an emergency service, with diagnosis of deep venous thrombosis (DVT) in the right lower limb (RLL). She reported a history of previous cesarean section at 40 weeks gestation due to inactivity, with no interurrences, and was discharged on the 2nd postoperative day (POD). The patient evolved with painful edema in the MID and swelling on the following day, associated with fever and lower abdominal pain. Doppler ultrasonography (US) was performed, and DVT in the right femoral artery was diagnosed. At the maternity, she was given anticoagulation (OAC) with enoxeparin 60mg SC 12/12h and warfarin 5mg once a day, and the fever was investigated (daily and evening) with blood count, blood culture, urine culture, and serology, but no infectious focus

was identified. The patient evolved with pain in the left inguinal region during the investigation period and, after performing a new Doppler US, another DVT in the left inferior limb was confirmed. Continued the diagnostic investigation with abdominal computed tomography (CT) without contrast, a small perivesical collection was visualized, possibly corresponding to residual post-surgical edema. The CT showed venous thrombosis in the infrarenal portion of the inferior vena cava, in the external and internal common iliac veins, in the bilateral common femoral veins, and in the infrarenal portion of the inferior vena cava. Antibiotic therapy (ATBT) was started with intravenous (IV) meropenem 1g 8/8h and gentamicin, and a new contrast-enhanced CT was ordered, which showed edema in the fat planes of the pelvic region associated with DVT in: the infrarenal portion of the inferior vena cava; external and internal common iliac veins; bilateral common femoral veins; and the right ovarian vein. After five days' maintenance of the combined use of ATBT and ACO, there was complete regression of symptoms.

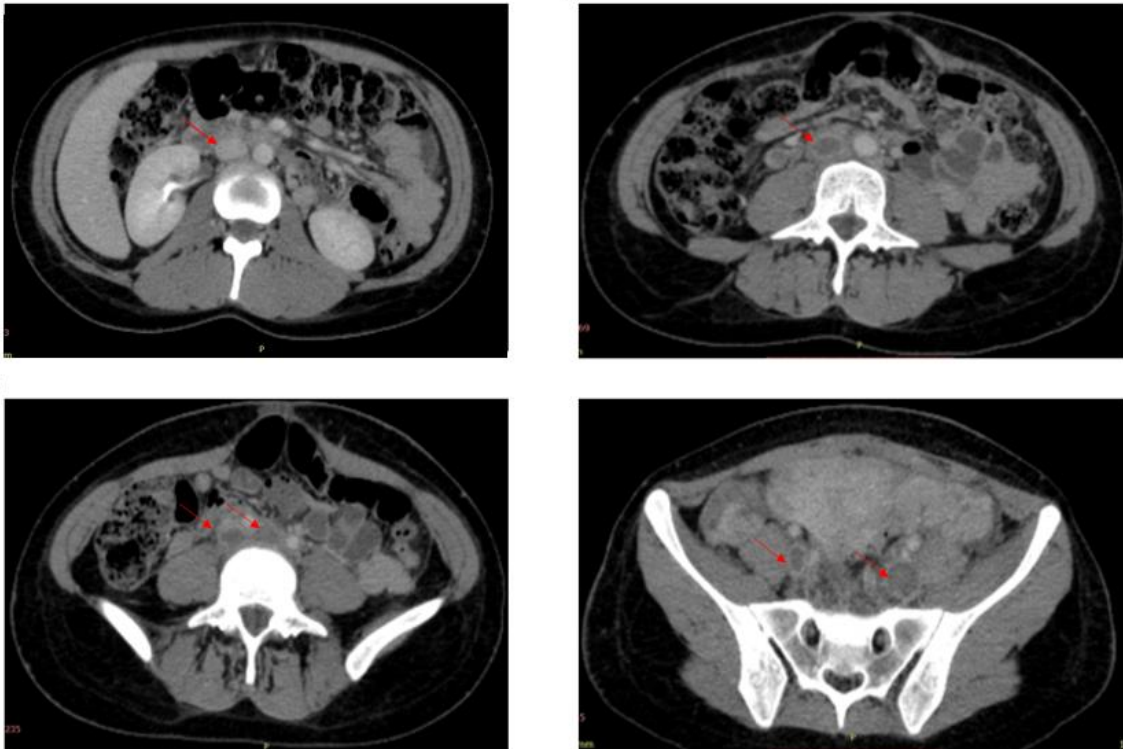
Figure 1: Coronal section of contrast-enhanced CT of the pelvis in the portal phase.

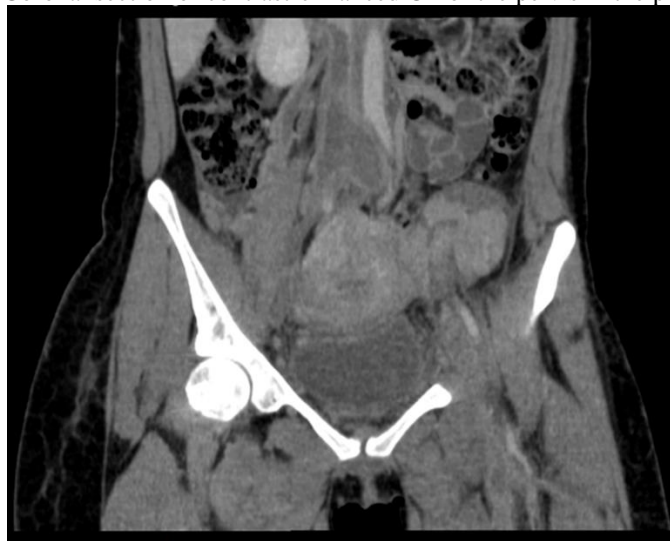

Figure 2:

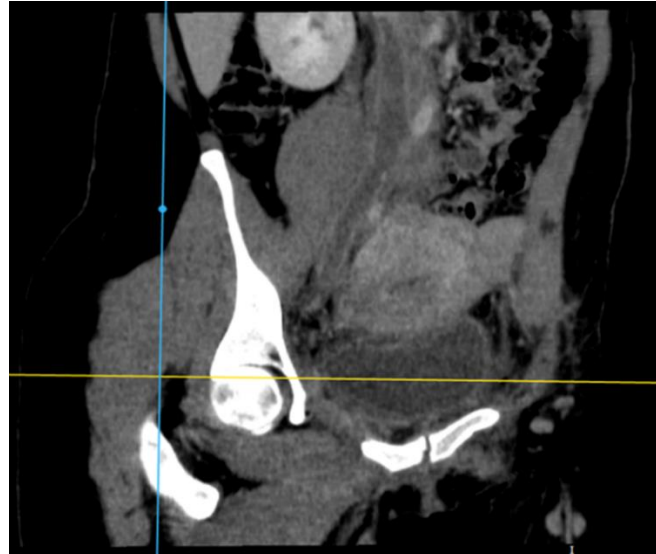

Figure 3: Contrast-enhanced CT of pelvis in the portal phase. Extensive venous thrombosis in the infrarenal portion of the inferior vena cava, in the external and internal common iliac veins, in the common femoral veins, bilaterally, in the right ovarian vein associated with edema in the adipose planes of the pelvic region.



3 DISCUSSION

Septic pelvic thrombophlebitis (SPT) is a recognized but rare (1/3,000 deliveries) puerperal complication whose development in the postpartum period is related to several obstetric, gynecologic, demographic, and surgical risk factors^(6,7). The higher frequency after cesarean section (1/800) compared to vaginal delivery (1/9000) is noteworthy, which is probably due to the

greater vulnerability of the postpartum period to several factors predisposing to the pathophysiology of SPT, including inflammation, thrombophilia and higher rate of puerperal infection in the surgical intervention.⁽⁷⁾The only risk factor for SPT identified in this case was cesarean section.

Its most common complications are the extension of thrombosis to the renal veins, iliofemoral vein and inferior vena cava, all of which were described in this case report⁽⁸⁾. There is also a 13% risk of evolution with pulmonary embolism and sepsis with septic emboli that can be fatal in 5% of complicated cases.^(4,8).

There can be uni or bilateral involvement, being about 5 times more frequent in the right ovarian vein, a fact justified by the pathophysiological mechanisms of SPT, outlined by Virchow's triad:

1- Endothelial damage: resulting either from injury to the tunica intima of the pelvic vein secondary to disseminated uterine infection, bacteremia, and endotoxins; or from the trauma of childbirth or surgery.³

2- Venous stasis: consequence of the tripled diameter of the ovarian vein due to pregnancy, with an increase in blood volume of about 60 times and consequent ovarian valve incompetence, together with low ovarian venous pressures in the postpartum period that promote the collapse of the pelvic veins, resulting in stagnation of blood inside them^(5,7). Thus, retrograde ovarian venous flow from the left uterine and ovarian veins into the right ovarian vein, with persistent anterograde flow in the right ovarian vein, promotes the higher frequency of thrombophlebitis in the right ovarian vein in postpartum.

3- Hypercoagulability: alteration favored by the physiology of pregnancy itself, due to alterations in platelet adhesion and coagulation factors that favor the creation of a thrombogenic environment^(3,7).

This pathophysiology is shared by the two manifestations of TPS: ovarian vein thrombophlebitis (OVT) and deep pelvic septic thrombophlebitis (SPPT)⁽⁷⁾. However, while TPS presents late development, with obscure high fever, minimal or absent abdominal pain and difficult to diagnose by imaging; the most common manifestation of TPS: TVO, is acute and has characteristic clinic of thrombophlebitis (fever, abdominal pain and leukocytosis) in 2 to 15 days postpartum, and may manifest mild gastrointestinal symptoms; its physical examination presents painful palpation of the pelvic region and, rarely, a cord is palpated from the uterus to the upper lateral abdomen, and its diagnosis is favored by the demonstration of the obstructed ovary vein on CT^(6,7,9).

These characteristics are consistent with the clinical manifestation described in this study: a TVO, presenting with persistent fever associated with diarrhea and abdominal pain mainly in the iliac fossa and right flank, 15 days after cesarean delivery.



SPT is an important differential diagnosis for abdominal pain and fever in the postpartum period, but the lack of specific complementary tests makes its diagnosis challenging, which often leads to misdiagnoses of acute appendicitis, endometritis, pelvic inflammatory disease, pyelonephritis, nephrolithiasis, adnexal torsion or pelvic abscess^(7,9). The key to correct diagnosis is a high level of clinical suspicion, especially when there is resistance to broad-spectrum antibiotic therapy and remission after systemic anticoagulation⁽⁷⁾. Laboratory tests such as CBC, urinalysis with culture and blood cultures (often negative in TPS) can help in the differential diagnosis.⁽³⁾

The propedeutics adopted in the reported case is in accordance with the literature. Ultrasonography, due to its technical limitations, assumes a secondary role in the diagnostic elucidation; the combination of persistent fever with the typical appearance of thrombosis at CT is a good method for confirming this diagnosis^(2,4). It is worth noting, however, that CT cannot be used in the diagnosis of thrombosis in all pelvic veins, since about 40% of clots are found within the uterus or paravaginal vessels, usually not visualized with current imaging techniques.⁽²⁾ Typical CT findings are: filling defect within the ovarian vein, thickened and enlarged vessel wall, possible venous enlargement and perivenous stranding^{3,10}. On post-contrast images it is also possible to note the absence of deflecting flow in the filling of the ovarian vein⁽¹⁰⁾.

The chosen conduct was conservative: antibiotic therapy associated with systemic anticoagulation, which has been safe since the 1960s and is well accepted^{5,2}. Although the use of anticoagulation therapy remains controversial, its use in the treatment of TPS is recommended by many authors in order to prevent new thromboemboli and to reduce the spread of septic emboli.^(5,7) The absence of defined guidelines requires substantiation of the duration from extrapolation of imaging studies of thrombosis, its location and its persistence after initial treatment.⁽⁷⁾ Furthermore, the option for meropenem 1g IV 8/8h is based on the literature reviewed for its action against *Bacterioides* spp. which produce heparinase and can lead to persistent or progressive disease.⁽⁶⁾

4 CONCLUSION

Given the large number of cesarean sections performed today and their correlation with SPT, an increase in the number of cases should be accompanied by greater familiarity of health professionals with this complication, in order to avoid inadequate propaedeutics and management. In this context, the present case report documents the importance of investigating pelvic septic thrombosis in patients with fever in the puerperium and its differential diagnoses for early initiation of therapy to reduce morbidity and mortality.



REFERENCES

- Roepke RML, Campos FPF de, Lovisolo SM, Santos EHS. Septic pelvic thrombophlebitis of unknown origin: an ever threatening entity. *Autopsy Case Rep.* 2014;4(3):39–46.
- Brown CE, Stettler RW, Twickler D, Cunningham FG. Puerperal septic pelvic thrombophlebitis: Incidence and response to heparin therapy. *Am J Obstet Gynecol.* julho de 1999;181(1):143–8.
- Garcia J, Aboujaoude R, Apuzzio J, Alvarez JR. Septic Pelvic Thrombophlebitis: Diagnosis and Management. *Infect Dis Obstet Gynecol.* 2006; 2006:1–4.
- Khelifi A, Kebaili S, Hammami M, Berregaya L, Hidar S, Affes N, et al. Postpartum ovarian vein thrombophlebitis: Report of a case and review of the literature. *North Am J Med Sci.* 2010;2(8):4.
- Rolim MO, Nobre NMA, Barbosa ML, Rebouças E, Martins DM, Nogueira CS. Tromboflebite pélvica séptica em puérpera: relato de caso. :4.
- Chaim W, Burstein E. Postpartum infection treatments: a review. *Expert Opin Pharmacother.* 2003;17.
- da Silva Cunha M, Godinho AB, Botelho R, de Almeida JP. Postpartum septic pelvic thrombophlebitis after caesarean delivery: a case report. *Case Rep Womens Health.* janeiro de 2018; 17:5–7.
- Lamy C, Zuily S, Perdriolle E, Gauchotte E, Villeroy-de-Galhau S, Delaporte M-O, et al. Prise en charge des infections du post-partum. *J Gynécologie Obstétrique Biol Reprod.* dezembro de 2012;41(8):886–903.
- P. Sharma, S. Abdi. Ovarianveinthrombosis. *ClinicalRadiology.* 67 (2012) 893 e 898.
- Laifer-Narin SL, Kwak E, Kim H, Hecht EM, Newhouse JH. Multimodality Imaging of the Postpartum or Posttermination Uterus: Evaluation Using Ultrasound, Computed Tomography, and Magnetic Resonance Imaging. *Curr Probl Diagn Radiol.* novembro de 2014;43(6):374–85.