




HISTOPATHOLOGICAL AND IMMUNOHISTOCHEMICAL FINDINGS OF PLACENTAS IN PREGNANT PATIENTS WITH SARS-COV-2

ACHADOS HISTOPATOLÓGICOS E IMUNO-HISTOQUÍMICOS DE PLACENTAS EM PACIENTES GRÁVIDAS COM SARS-COV-2

HALLAZGOS HISTOPATOLÓGICOS E IMMUNOHISTOQUÍMICOS DE PLACENTAS EN PACIENTES EMBARAZADAS CON SARS-COV-2

 <https://doi.org/10.56238/isevjhv4n5-002>

Receipt of originals: 08/22/2025

Acceptance for publication: 09/22/2025

Mario Roberto Pinto Romero¹, Daniela Rosibel Martinez Caceres²

ABSTRACT

Background: Due to the pandemic, different diagnostic studies are being carried out throughout the world to identify the virus in the first place, determine the accompanying symptoms and complications that can alter normal hemostasis in patients, and in our environment it is no different since pregnant women per se have a diminished immune system.

Objective: determine the histopathological and Immunohistochemical finding of the placentas in pregnant patients with Covid-19.

Methods: a descriptive study of 30 patients was carried out at the Leonardo Martinez Valenzuela Hospital, San Pedro Sula, Honduras during three months of 2021, where a histopathological and immunohistochemical study of the placentas of pregnant patients with Covi-19 was carried out.

Results: histopathological studies of the placentas found congestive, infectious and inflammatory, infectious, and congestive changes, immunohistochemical studies with RT-PCR on each of the placenta samples without finding evidence of vertical transmission.

Discussion: the histopathological changes produced in the placentas by covid infection can determine the degree of affectation of the developing fetus.

Keywords: Immunohistochemistry. Pathology. Placenta. Pregnancy. Covid-19.

RESUMO

Contexto: Devido à pandemia de COVID-19, diversos estudos diagnósticos estão sendo realizados em todo o mundo para identificar o vírus, determinar os sintomas associados e as complicações que podem interromper a hemostasia normal em pacientes. Isso não é

¹ Gynecologist Obstetrician specializing in Gynecological Laparoscopy. Hospital Leonardo Martinez Valenzuela, San Pedro Sula, Cortes, Honduras. E-mail: mario1391pinto@yahoo.com
Orcid: <http://orcid.org:0000-0003-0831-5851>

² General Practitioner. Wester International School. E-mail: danielarosibel@yahoo.com
Orcid: <http://orcid.org:0009-0008-8465-8227>



diferente em nosso meio, visto que gestantes geralmente apresentam um sistema imunológico enfraquecido.

Objetivo: Determinar os achados histopatológicos e imuno-histoquímicos em gestantes com COVID-19.

Métodos: Um estudo descritivo de 30 pacientes (casos) foi realizado no Hospital Leonardo Martinez Valenzuela, em San Pedro Sula, Honduras, ao longo de três meses em 2021. Os componentes histopatológicos e imuno-histoquímicos das placentas de gestantes com COVID-19 foram analisados.

Resultados: Os estudos histopatológicos das placentas revelaram alterações inflamatórias, infecciosas e congestivas. Estudos imuno-histoquímicos com RT-PCR também foram realizados em cada uma das amostras de placenta, não encontrando evidências de transmissão vertical.

Discussão: As alterações histopatológicas produzidas na placenta pela infecção por COVID podem determinar o grau de acometimento do feto em desenvolvimento durante a gestação, mas não o grau de transmissão vertical.

Palavras-chave: Gravidez. Imuno-histoquímica. Patologia. Placenta. COVID-19.

RESUMEN

Antecedentes: Debido a la pandemia del virus COVID 19 en todo el mundo se estan realizando diferentes estudios diagnosticos para lograr identificar en primer lugar el virus, determinar los sintomas acompañantes y las complicaciones que pueden llegar alterar la hemostasia normal en los pacientes, y en nuestro medio no es diferente ya que las mujeres embarazadas per- se tienen un sistema inmunitario disminuido.

Objetivo: Determinar los hallazgos histopatologicos e inmunohistoquimicos en las pacientes embarazadas con Covid-19.

Metodos: se realizo un estudio descriptivo de 30 pacientes (expedientes) en el Hospital Leonardo Martinez Valenzuela, San Pedro Sula, Honduras, durante tres meses del 2021. Se analizo el componente histopatologico e inmunohistoquimico de las placentas de pacientes embarazadas con Covi-19.

Resultados: en los estudios histopatologicos de las placentas se encontró cambios inflamatorios, infecciosos, y congestivos; tambien se realizaron estudios inmunohistoquimicos con RT-PCR a cada una de las muestras de placenta sin encontrar evidencia de trasnmission vertical.

Discusion: los cambios histopatologicos producidos en las placentas por la infeccion de covid pueden determinar el grado de afectacion del feto en desarrollo durante el periodo de gestacion, mas no el contagio por transmision vertical.

Palabras clave: Embarazo. Inmunohistoquímica. Patológico. Placenta.Covid-19.



1 INTRODUCTION

On December 31, 2019, the first case of pneumonia due to a novel coronavirus (SARS-COV-2) was announced in the city of Wuhan, Hubei province, China. The Covid-19 epidemic was declared by the WHO (World Health Organization) a public health emergency of international concern on January 30, 2020. 1 Pregnant women with an acute and severe respiratory infection such as SARS-COV-2 may be symptomatic or asymptomatic and those who develop symptoms may develop such a severe infection compared to women of reproductive age who are not pregnant with Covid-19.2

The histopathological examination of placental tissue could provide information such as decidual arteriopathy and abnormal maternal vascular perfusion, which in terms of maternal health leads us to the need for better prenatal surveillance in patients with COVID-19.3 In pregnant patients, we found a greater susceptibility to Sars-Cov-2 infection due to physiological changes in the immune system and respiratory system.4 Pregnant women are at greater risk of infections, since their immune system is altered in order not to reject the fetus.5,6 Histological examination of the placenta has revealed a dense infiltration of macrophages at the interface level, highlighting severe morbidity among women infected with Covid-19.7 Pathological findings of placentas of pregnant women with Covid-19 have been variable; some reports describe no significant changes, some describe evidence of poor maternal or fetal vascular perfusion, or both and others describe inflammatory lesions including chronic histiocytic intervillitis, villitis, funisitis, and chorioamnionitis.8

Only one of the studies reviewed documented placental findings, which consisted of acute chorioamnionitis, retroplacental hematoma, and vascular alterations in the placenta. These conditions predispose to unfavorable outcomes in both mother and newborn.9,10 The extent of vertical transmission (in utero, intrapartum, early postnatal period is still unclear), although the overall rate of congenital infection has been reported to be low, there are well-documented cases of probable intrauterine transmission.11-15 The objective of this study was to describe the histopathological and immunohistochemical findings at the level of placental tissue secondary to Sars-CoV-2. Being a relatively new disease, it is a great challenge to comprehensively manage this type of patient and even more so where we do not know if the virus crosses the placental barrier and thus corroborate if the infections in neonates are by vertical transmission.



2 PARTICIPANTS AND METHODS

Descriptive study, data were obtained from a random sample of 30 patients who came for obstetric care, regardless of gestational age with Covid-19 infection, during January to March 2021 at the Leonardo Martínez Valenzuela Hospital, located in the department of Cortés, Honduras. Clinical data were obtained from the file (perinatal medical history) with prior informed consent. The patients were admitted to the Covid maternity ward for obstetric care, following the protocol implemented by the Covid-19 pandemic. Placentas were processed by the Honlab Laboratory in Tegucigalpa, Honduras and immunohistochemistry by the SMeL3-Pathological Anatomy, Bergamo, Italy. Histological Technique: An anatomopathological study was performed on 30 placentas of patients diagnosed with Covid-19.

All samples were fixed in 37% formalin, which were later included using the paraffin technique. Hematoxylin-eosin staining was performed in all cases and histological sections were reviewed, including chorionic villi, placental membranes, and umbilical cord of each of the specimens studied. RNA extraction was performed on each of the samples. Fixation in Paraffin-Introduced Formalin (FFPE), two 10-micron tissue slices were collected and all paraffin was removed by treating them with deparaffinization solution (QIAGEN). RNA was extracted according to the RNeasy FFPE kit instructions (QIAGEN) and the amount was determined with the Nanodrop spectrophotometer. Verses 16-19

3 RESULTS

In the study, a mean of 23 years of age was observed, most of them came from the department of Cortés with 73% (n=22), with a mean of 39 weeks of gestation; 46.6% (n=14) were asymptomatic and 32.26% (n=10) had fever. The risk factors identified were hypertensive disorders with 23% (n=6), Diabetes Mellitus 17% (n=5), obesity 7% (n=2), Gestational diabetes with 3% (n=1), Heart disease with 3% (n=1). Of the total tests performed for the detection of Sars-CoV-2, 83% (n=25) were positive for covid antibody test (PCR), 12.90% (n=4) positive for antigen test (IgM and IgG) and a total of 6.45% (n=2) with a negative result making a diagnosis by clinic. Among the placental histopathological findings, villitis was found in 100% (n=30), chorioamnionitis in 57% (n=17), congestive membranes 33% (n=10), vascular villus congestion 30% (n=9), hypoplasia 6% (n=2), villus rarefaction 6% (n=2), subchorionitis 10% (n=3), focal dystrophic calcification 40% (n=12), syncytial lymph node augmentation 13% (n=4), intervillous and perivillous fibrin 6% (n=2), intraparenchymal



hematoma 3% (n=1), intervillous hemorrhagic extravasation 3% (n=1). (see Figure 1-4) Among the histopathological findings of the umbilical cord, funisitis was found in 43% (n=13), and ectatic umbilical cord in 3% (n=1).

Figure 1 The results of RNA extraction from each of the samples were successfully amplified for internal control by RT-PCR, but none of them detected the presence of viral RNA sequences from conserved regions of nucleoproteins of the novel coronavirus SARS-CoV-2. (see table 1) The termination of pregnancy resulted in cesarean sections with 83% (n=25) and vaginal delivery with 16.13% (n=5). No fuss. 93% (n=28) of the patients were discharged as medical discharge and 7% (n=2) died and 93% (n=28) of the newborns were discharged as medical discharge, 3% (n=1) referred and 3% (n=1) died.

4 DISCUSSION

Pregnancy is an immunosuppressive state and having had a Covid 19 infection worsens the condition, more comorbidities (Diabetes, Hypertension, Asthma, Obesity, Heart Disease, etc.) increases maternal mortality; that in the three months of the study we reported only two maternal deaths, but at the end of October 2021 there were 47 in the covid maternity ward of the Leonardo Martínez Valenzuela Hospital; maternal and neonatal mortality was lower compared to discharge in our study. The placenta is a transitory organ made up of the mother's tissues and fetal tissues whose main functions are to nourish and protect the fetus.²⁰ Severity may be related to an impaired adaptive immune response and increased release of proinflammatory cytokines, leading to systemic inflammation, severe organ damage, and ultimately death, the same clinical features as a non-pregnant patient, so multidisciplinary management is necessary.^{5,21}

There are studies that have shown that the histological examination of placentas from mothers with Covid-19 have mostly presented inflammatory and vascular changes that suggest involvement of the placenta by the virus. These changes can be attributed to maternal hypoxia and prothrombotic activity resulting from the virus-induced release of proinflammatory cytokines.^{13,14} Other results showed that at the macroscopic and microscopic level no pathological changes suggestive of placental infection were found, the only finding that drew attention was the increase in fibrin deposits at the level of the stroma and syncytial nodules. This can cause a decrease in blood flow at the placental level and therefore generate hypoxia that would lead to micro infarctions in this tissue. ^{5,10,21} In relation to Sars-CoV and MERS, an increase in first-trimester miscarriage, preterm delivery,



premature rupture of membranes, intrauterine growth restriction, and an increased cesarean section rate have been reported, with placental histopathology reporting a large amount of fibrin (intervillous and subchorionic), villus calcifications, infarctions, placental hypotrophy and thrombotic vasculopathy in some villi.²² In many studies carried out, vertical transmission has not been proven, but it cannot be ruled out.²³

The histopathological changes found in the study were villitis, chorioamnionitis, congestive membranes, vascular villus congestion, focal dystrophic calcification, intervillous fibrin, and increased lymph nodes syncytial hematomas, intraparenchymal hematomas, and funisitis, which are consistent with those reported in other previous studies at the international level. The results of RNA extraction from each of the samples sent to Italy were successfully amplified for internal control by RT-PCR, but in none of them was the presence of viral RNA sequences from conserved regions of nucleoproteins of the new coronavirus SARS-COV-2 detected, therefore, the placenta is a protective barrier so that the fetus does not contract the infection by this route. However, it can be said that SARS-CoV-2 infection during pregnancy represents a risk factor for neonatal complications.

According to most studies, there was no vertical transmission; This tells us that such transmission, although it can occur, is a very rare finding.^{22,23} Sars-CoV-2 infection in Honduras, in an analysis of the current situation, was a public health problem, therefore studies with a larger number of samples are required to determine the anatomopathological and immunohistochemical characteristics of the placentas and thus establish the route of transmission to the newborn.

CONTRIBUTIONS

The project was approved by the management of the Leonardo Martínez Valenzuela Hospital, Dr. Mario Roberto Pinto Romero as head of the covid room in the afternoon, trying to establish management protocols for this type of patient and Dr. Daniela Rosible Martínez Cáceres as support and requirement for her thesis to obtain the title of Doctor of Medicine and Surgery.

ACKNOWLEDGMENTS

Thank you to our Elohim for giving us the security and confidence of being alive in the face of the imminent risk of contagion; Thanks to Dr Ruben Valladares for carrying out the



anatomopathological studies of the placentas that were sent to him; finally to Dr. Dennis Morotti in Italy because thanks to her immunohistochemical studies were performed on each of the blocks of the placentas.

REFERENCES

- Allotey, J., Chatterjee, S., Kew, T., Gaetano, A., Stallings, E., Fernández-García, S., Yap, M., Sheikh, J., Lawson, H., Coomar, D., Dixit, A., Zhou, D., Balaji, R., Littmoden, M., King, Y., Debenham, L., Llavall, A. C., Ansari, K., Sandall, J., ... Thangaratinam, S. (2022). SARS-CoV-2 positivity in offspring and timing of mother-to-child transmission: Living systematic review and meta-analysis. *BMJ*, 376, e067696. <https://doi.org/10.1136/bmj-2021-067696>
- Allotey, J., Stallings, E., Bonet, M., Yap, M., Chatterjee, S., Kew, T., Debenham, L., Llavall, A. C., Dixit, A., Zhou, D., Balaji, R., Lee, S. I., Qiu, X., Yuan, M., Coomar, D., Sheikh, J., Lawson, H., Ansari, K., van Wagtenonk, I., ... Thangaratinam, S. (2020). Clinical manifestations, risk factors, and maternal and perinatal outcomes of coronavirus disease 2019 in pregnancy: Living systematic review and meta-analysis. *BMJ*, 370, m3320. <https://doi.org/10.1136/bmj.m3320>
- Baergen, R. N., & Heller, D. S. (2020). Placental pathology in COVID-19 positive mothers: Preliminary findings. *Pediatric and Developmental Pathology*, 23(3), 177–180. <https://doi.org/10.1177/1093526620925569>
- Burton, G. J., & Fowden, A. L. (2015). The placenta: A multifaceted, transient organ. *Philosophical Transactions of the Royal Society B: Biological Sciences*, 370(1663), 20140066. <https://doi.org/10.1098/rstb.2014.0066>
- Chen, S., Huang, B., Luo, D. J., Li, X., Yang, F., Zhao, Y., ... & Zhang, H. (2020). Pregnancy with new coronavirus infection: Clinical characteristics and placental pathological analysis of three cases. *Zhonghua Bing Li Xue Za Zhi*, 49(5), 418–423. <https://pubmed.ncbi.nlm.nih.gov/32114744/>
- Cuadra, T. E., Guadrón Meléndez, A. A., Cruz Aguilar, R. D. J., & Vásquez Rodríguez, E. A. (2021). Factores relevantes sobre el ensayo RT-PCR para la detección de SARS-CoV-2, virus causante del COVID-19. *Alerta*, 4(1), 31–39. https://docs.bvsalud.org/biblioref/2021/701/1146454/factores_relevantes_sobre_el_ensayo_rt-pcr_para_la_deteccion_d_AucnkXH.pdf
- Hecht, J. L., Quade, B., Deshpande, V., Mino-Kenudson, M., Ting, D. T., Desai, N., ... & Roberts, D. J. (2020). SARS-CoV-2 can infect the placenta and is not associated with specific placental histopathology: A series of 19 placentas from COVID-19-positive mothers. *Modern Pathology*, 33(11), 2092–2103. <https://doi.org/10.1038/s41379-020-0639-4>
- Hosier, H., Farhadian, S. F., Morotti, R. A., Deshmukh, U., Lu-Culligan, A., Campbell, K. H., ... & Liu, J. P. (2020). SARS-CoV-2 infection of the placenta. *Journal of Clinical Investigation*, 130(9), 4947–4953. <https://doi.org/10.1172/JCI139569>



- Kirtsman, M., Diambomba, Y., Poutanen, S. M., Malinowski, A. K., Vaudry, W., Morris, S. K., ... & Yudin, M. H. (2020). Probable congenital SARS-CoV-2 infection in a neonate born to a woman with active SARS-CoV-2 infection. *CMAJ*, 192(24), E647–E650. <https://doi.org/10.1503/cmaj.200821>
- Liu, D., Li, L., Wu, X., Zheng, D., Wang, J., Liang, B., ... & Yang, B. (2020). Pregnancy and perinatal outcomes of women with COVID-19 pneumonia: A preliminary analysis. *SSRN Electronic Journal*. <https://doi.org/10.2139/ssrn.3548758>
- Mor, G., Aldo, P., & Alvero, A. B. (2017). The unique immunological and microbial aspects of pregnancy. *Nature Reviews Immunology*, 17(8), 469–482. <https://doi.org/10.1038/nri.2017.64>
- Moore, C. A., Staples, J. E., Dobyns, W. B., Pessoa, A., Ventura, C. V., Da Fonseca, E. B., ... & Rasmussen, S. A. (2017). Characterizing the pattern of anomalies in congenital Zika syndrome for pediatric clinicians. *JAMA Pediatrics*, 171(3), 288–295. <https://doi.org/10.1001/jamapediatrics.2016.3982>
- Morotti, D., Cadamuro, M., Tedeschi, S., Merli, M., Leali, I., Maida, R., ... & Razzetti, F. (2021). Molecular pathology analysis of SARS-CoV-2 in syncytiotrophoblast and Hofbauer cells in placenta from a pregnant woman and fetus with COVID-19. *Pathogens*, 10(4), 479. <https://doi.org/10.3390/pathogens10040479>
- Mulvey, J. J., Magro, C. M., Ma, L. X., Nuovo, G. J., & Baergen, R. N. (2020). Analysis of complement deposition and viral RNA in placentas of COVID-19 patients. *Annals of Diagnostic Pathology*, 46, 151530. <https://doi.org/10.1016/j.anndiagpath.2020.151530>
- Organización Panamericana de la Salud. (2020). Actualización epidemiológica: Nuevo coronavirus (2019-nCoV). <https://covid19-evidence.paho.org/handle/20.500.12663/419>
- Sampieri, C. L., & Montero, H. (2022). Revisión de nuevas evidencias acerca de la posible transmisión vertical de la COVID-19. *Gaceta Sanitaria*, 36(2), 166–172. <https://doi.org/10.1016/j.gaceta.2020.06.008>
- Schwartz, D. A., & Morotti, D. (2020). Placental pathology of COVID-19 with and without fetal and neonatal infection: Trophoblast necrosis and chronic histiocytic intervillitis as risk factors for transplacental transmission of SARS-CoV-2. *Viruses*, 12(11), 1308. <https://doi.org/10.3390/v12111308>
- Sociedad de Información Científica. (n.d.). Anormalidades placentarias en COVID-19. SIIC Salud. <https://www.siicsalud.com/dato/resiiccompleto.php/163837>
- Vivanti, A. J., Vauloup-Fellous, C., Prevot, S., Zupan, V., Suffee, C., Do Cao, J., ... & De Luca, D. (2020). Transplacental transmission of SARS-CoV-2 infection. *Nature Communications*, 11(1), 3572. <https://doi.org/10.1038/s41467-020-17436-6>
- Von Kohorn, I., Stein, S. R., Shikani, B. T., Ramos-Benitez, M. J., Vannella, K. M., Petrarca, A., ... & Chertow, D. S. (2020). In utero Severe Acute Respiratory Syndrome Coronavirus



2 infection. *Journal of the Pediatric Infectious Diseases Society*, 9(6), 769–771. <https://doi.org/10.1093/jpids/piaa127>

Zhao, Z., Cui, H., Song, W., Ru, X., Zhou, W., & Yu, X. (2020). A simple magnetic nanoparticles-based viral RNA extraction method for efficient detection of SARS-CoV-2. *bioRxiv*. <https://doi.org/10.1101/2020.02.22.961268>

Zhu, N., Zhang, D., Wang, W., Li, X., Yang, B., Song, J., ... & Tan, W. (2020). A novel coronavirus from patients with pneumonia in China, 2019. *New England Journal of Medicine*, 382(8), 727–733. <https://doi.org/10.1056/NEJMoa2001017>

ANNEXES

Figure 1

Histopathological findings in placenta

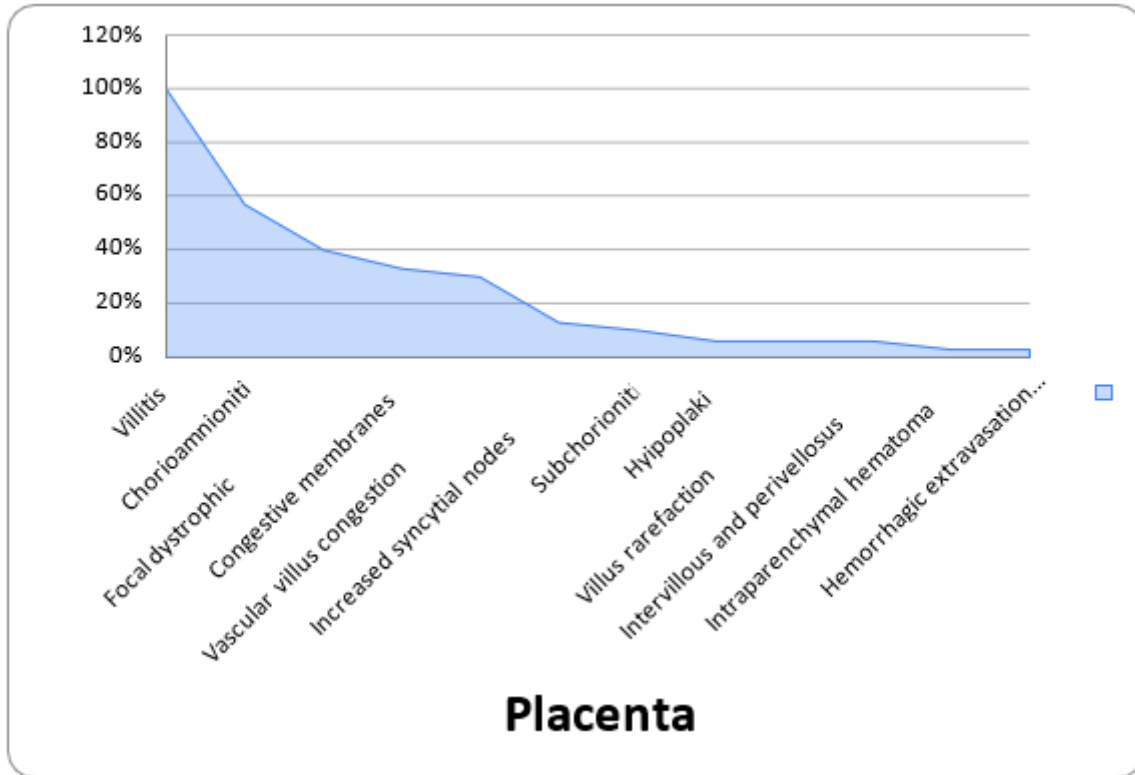


Figure 2

Figure of the different histological sections with inflammatory changes at the level of placental tissue

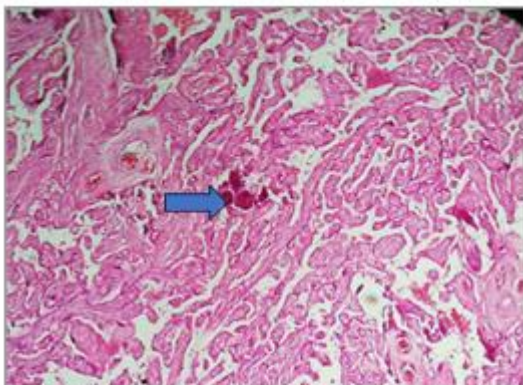


Photo 3. Histological sections showing villi chorionic sections of the 3rd trimester, trimester with dystrophic calcification of an infiltrate (HE stain 10x). lymphocytes (HE stain 10x)

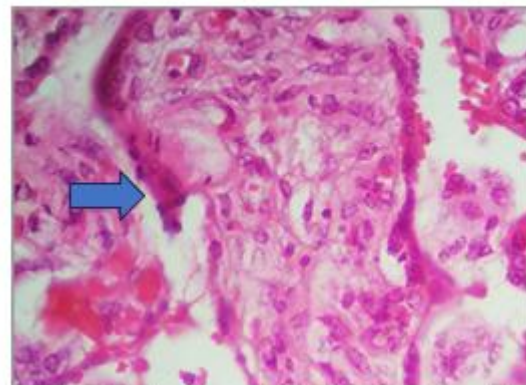


Photo 4. Histological sections show congestive observed in the chorionic villi of the 3rd trimester with inflammatory villus mild in the stroma composed of lymphocytes (HE stain 10x)



Table 1

Results of RNA extraction from placental tissue

Cod AN Pad	Amplify.Ct			Note
	ORF-1A \leq 37	Cin \leq 40	GeneN \leq 37	
I21-22798	No ct.	27.34	No ct.	Negative
I21-22799	No ct.	23.47	No ct.	Negative
I21-22800	No ct.	27.08	No ct.	Negative
I21-22801	No ct.	23.67	No ct.	Negative
I21-22804	No ct.	26.39	No ct.	Negative
I21-22805	No ct.	28.64	No ct.	Negative
I21-22807	No ct.	27.44	No ct.	Negative
I21-22808	No ct.	28.84	No ct.	Negative
I21-22809	No ct.	26.22	No ct.	Negative
I21-22810	No ct.	25.31	No ct.	Negative
I21-22811	No ct.	27.44	No ct.	Negative
I21-22817	No ct.	31.24	No ct.	Negative
I21-22818	No ct.	32.17	No ct.	Negative
I21-22819	No ct.	29.11	No ct.	Negative
I21-22820	No ct.	28.38	No ct.	Negative
I21-22821	No ct.	28.30	No ct.	Negative
I21-22822	No ct.	26.03	No ct.	Negative
I21-22823	No ct.	27.07	No ct.	Negative
I21-22824	No ct.	29.84	No ct.	Negative
I21-22825	No ct.	24.0	No ct.	Negative
I21-22826	No ct.	30.35	No ct.	Negative
I21-22827	No ct.	29.50	No ct.	Negative
I21-22828	No ct.	32.35	No ct.	Negative
I21-22829	No ct.	27.22	No ct.	Negative
I21-22830	No ct.	24.50	No ct.	Negative
I21-22831	No ct.	24.52	No ct.	Negative
I21-22832	No ct.	33.38	No ct.	Negative
I21-22833	No ct.	31.79	No ct.	Negative
I21-22834	No ct.	25.84	No ct.	Negative
I21-22835	No ct.	29.28	No ct.	Negative
NTC	-	-	-	NTC
PC	20.91	22.14	-23.64	PC