



Morphophysiological response of the thyroid gland of female *Mus musculus* exposed to essential oils (bioactive compounds) extracted from *Egletes viscosa* and *Lippia schauerian*

Resposta morfofisiológica da glândula tiroide de *Mus musculus* fêmea exposta a óleos essenciais (compostos bioativos) extraídos de *Egletes viscosa* e *Lippia schauerian*

DOI: 10.56238/isevmjv2n2-004

Receiving the originals: 01/03/2023

Acceptance for publication: 20/03/2023

Melissa Carolina Pereira

Department of General and Applied Biology, Bioscience Institute, São Paulo State University
“Júlio de Mesquita Filho”, UNESP, Rio Claro, SP, Brazil.

Bruna Jéssyca Nascimento Araújo

Department of General and Applied Biology, Bioscience Institute, São Paulo State University
“Júlio de Mesquita Filho”, UNESP, Rio Claro, SP, Brazil.

Odaiza da Silva

Department of General and Applied Biology, Bioscience Institute, São Paulo State University
“Júlio de Mesquita Filho”, UNESP, Rio Claro, SP, Brazil.

Andressa Ferreira Abreu

Department of General and Applied Biology, Bioscience Institute, São Paulo State University
“Júlio de Mesquita Filho”, UNESP, Rio Claro, SP, Brazil.

Eric Lemos Krüger

Department of General and Applied Biology, Bioscience Institute, São Paulo State University
“Júlio de Mesquita Filho”, UNESP, Rio Claro, SP, Brazil.

Gabriel Esbrisse dos Santos

Department of General and Applied Biology, Bioscience Institute, São Paulo State University
“Júlio de Mesquita Filho”, UNESP, Rio Claro, SP, Brazil.

Giovanna Tavares Lima

Department of General and Applied Biology, Bioscience Institute, São Paulo State University
“Júlio de Mesquita Filho”, UNESP, Rio Claro, SP, Brazil.

Giulia Isabelle Marinho Garrito

Department of General and Applied Biology, Bioscience Institute, São Paulo State University
“Júlio de Mesquita Filho”, UNESP, Rio Claro, SP, Brazil.

Nádia Cristina Feltre

Department of General and Applied Biology, Bioscience Institute, São Paulo State University
“Júlio de Mesquita Filho”, UNESP, Rio Claro, SP, Brazil.



Marina Rodrigues de Abreu

Department of General and Applied Biology, Bioscience Institute, São Paulo State University
“Júlio de Mesquita Filho”, UNESP, Rio Claro, SP, Brazil.

Maria Izabel Camargo-Mathias

Department of General and Applied Biology, Bioscience Institute, São Paulo State University
“Júlio de Mesquita Filho”, UNESP, Rio Claro, SP, Brazil.
E-mail: maria.izabel@unesp.br

ABSTRACT

The tick *Rhipicephalus linnaei* (Audouin, 1826), popularly known as the brown dog tick, is of medical and veterinary importance because it transmits several pathogens that cause diseases which are relevant to public health and, consequently, significant economic losses. Previous studies have shown that acaricides that use synthetic active ingredients leave harmful residues in the environment and cause problems for non-target organisms, which include hosts in general. For these reasons, new strategies and control methods, such as biological approaches, vaccines, and bioactive compounds from plants, have been studied. In the present study, the action of essential oils extracted from *Egletes viscosa* and *Lippia schaueriana*, both native to Brazil, were evaluated. Despite having proven effectiveness as acaricides (against this species of ticks), studies on the effects they have on hosts (here simulated by female *Mus musculus*) had not yet been performed. The unprecedented results found here showed that, in treatment group T1 (female mice exposed to *L. schaueriana* oil), there were morphological changes in the thyroid that indicated that these glands would also have the functions of synthesis/transformation of the colloid into thyroid hormones physiologically compromised. There were changes in the morphology of follicular cells (from cuboidal to squamous) and cytoplasmic vacuolation. The colloid inside the follicles did not always appear homogeneous, and in many of them, a fine granulation was noticed, suggesting changes in the pre-hormone. In treatment group 2 (females exposed to *E. viscosa* oil), the follicular cells in the vast majority of follicles also lost their cuboidal shape and became squamous, and their nuclei changed from rounded to flattened and pyknotic. The rounded morphology of the follicles became irregular, causing disorganization of the follicular cells, and the interstitial spaces left between the follicles were filled by connective tissue. Therefore, these results make it clear that the exposure of female mice (simulating tick hosts) to essential oils of *E. viscosa* and *L. schaueriana* at a concentration of 50mg/mL caused morphophysiological changes in the thyroid gland of these subjects, which lead to the loss of organ function, and called attention to the importance of the careful use of acaricides even if they are naturally sourced.

Keywords: Natural bioactive, Control, Toxicity, Thyroid gland.

1 INTRODUCTION

The tick species *Rhipicephalus linnaei* (Audouin, 1826) recently recognised as the “tropical lineage” of *Rhipicephalus sanguineus* sensu lato, is commonly known as the brown dog tick since domestic dogs are its preferred host (CAMARGO-MATHIAS, 2018; NAVA et al., 2012; ORTEGA-MORALES et al., 2019). However, many other mammals have been reported to be hosts, including humans (DANTAS-TORRES, 2010). This ectoparasite has a three-host life cycle,



that is, it requires three hosts to complete all its development stages (DANTAS-TORRES, 2018; SONENSHINE; ROE, 2014).

This species of tick is given special attention in the medical/veterinary, economic/sanitary, and public health fields for being, at all stages of development, a vector for microorganisms, such as *Ehrlichia canis* (ehrlichiosis), *Babesia canis* (babesiosis), and *Hapatozoon canis* (hepatozoonosis), which are responsible for diseases that affect a large number of dogs worldwide every year (DANTAS-TORRES, 2018; DANTAS-TORRES; OTRANTO, 2015). Moreover, the species is responsible for transmitting bacteria of the genus *Rickettsia* spp. to hosts, causing spotted fever in Europe (*R. conorii*) and the US (*R. rickettsii*) (BORGES et al., 2007). In Brazil, there are records of *R. sanguineus* (s.l.) ticks infected by *R. parkeri*, the etiological agent of Brazilian spotted fever (BSF) (CUNHA et al., 2009; MOERBECK et al., 2016; SILVA et al., 2017).

Due to the great importance of this tick species, there has been an exhaustive search for control strategies. It is noteworthy that approximately US\$20 to US\$30 billion are estimated to be wasted annually worldwide due to tick infestations and, consequently, the diseases transmitted by them (LEW-TABOR; RODRIGUEZ VALLE, 2016; NDAWULA; TABOR, 2020). Studies conducted by Oliveira and Camargo-Mathias (2018) showed that acaricides with synthetic active principles, such as fipronil, permethrin, and deltamethrin, are more widely used in the control of these ectoparasites. Nonetheless, they leave harmful residues in the environment (ANHOLETO et al., 2017a; NOLAN, 1985; OLIVEIRA et al., 2009; OLIVEIRA; BECHARA; CAMARGO-MATHIAS, 2008) and affect non-target organisms, including hosts in general (CUNHA et al., 2017; REQUENA et al., 2019; SAKA; TADA, 2021). These factors have been stimulating the search for new strategies and control methods such as biological approaches, vaccines, and bioactive compounds from plants (QUADROS et al., 2020), which are based on secondary metabolites and extracted from roots, stems, leaves, flowers, and fruits of different plants (LORENZI; MATTOS, 2008; QUADROS et al., 2020). These metabolites, according to Martins (2018), are part of plants' defense strategies and have pharmacological and/or toxicological effects on humans and other animals.

Egletes viscosa (L.) Less. is a plant of the Asteraceae family native to tropical America. Popularly known as erect tropical daisy, it is found on the banks of streams and watercourses in the Northeast region of Brazil (LORENZI; MATTOS, 2008; PEREIRA; BEZERRA; ALMEIDA, 2018). It is important for its pharmacological applications, as it has antispasmodic, anti-inflammatory, antimicrobial, analgesic, and sedative properties (ARAÚJO et al., 2008; CALOU et al., 2008; CUNHA, 2003; LEE et al., 2005; PEREIRA; BEZERRA; ALMEIDA, 2018).



Moreover, this plant has bioactive compounds with antifungal and insecticidal potential (SINGH; MAURYA, 2005).

Lippia schaueriana Mart., of the Verbenaceae family, is another plant with acaricidal potential that has been studied. It is native to Brazil and endemic to Caatinga regions, being geographically restricted to the states of Bahia and Pernambuco (LORENZI; MATTOS, 2008; SOUZA et al., 2018). It is popularly known as “lípia-da-serra,” “alecrim-da-serra,” or “alecrim-de-mocó” due to the location where it grows and for being the main diet of native species of rodents such as the rock cavy, “mocó” in Portuguese (*Kerodon rupestris*, Caviidae) (SOUZA et al., 2018).

The use of natural acaricides in the control of tick infestations, despite being hardly used, has stimulated the development of many studies in this area (PEREIRA, 2021). Nevertheless, it is noteworthy that, although natural, little is known about how these bioactive compounds can affect human and animal health, especially concerning their toxicity, as it is well known that, depending on its dosage, a product can have toxic or medicinal effects (FIRENZUOLI; GORI, 2007). Therefore, studies on the toxicity of bioactive compounds extracted from plants, including those natural acaricides, are currently essential so that safe doses can be carefully established (FIRENZUOLI; GORI, 2007; QUADROS et al., 2020).

Mammals are among the organisms that ticks prefer to parasitize. In addition to the liver (detoxifying organ), they have a thyroid, an endocrine gland which performs a crucial role in regulating their metabolism, and are extremely sensitive to the action of toxic products circulating in their bloodstream, even in extremely low doses (CUNHA et al., 2017).

Thus, in order to obtain information that in the near future may help to better understand the action of natural acaricides on hosts when using them to control ticks, the present work aimed to evaluate how the essential oils extracted from *E. viscosa* and *L. schaueriana*, in previously determined concentrations which would act efficiently as acaricides (PEREIRA, 2021), may affect the morphophysiology of the thyroid of female *Mus musculus* (non-target organisms) exposed to them.

2 MATERIALS AND METHODS

2.1 MUS MUSCULUS

Twenty healthy, pathogen-free (SPF), female Swiss mice of the *Mus musculus* species were used. The animals were acquired from the Research Center for Animal Production (CPPA) of the São Paulo State University (UNESP) in Botucatu (SP, Brazil), they weighed approximately 40 g and were between 8 and 10 weeks old. The mice were placed in a room in the vivarium of the



Institute of Biosciences, UNESP Rio Claro campus (SP, Brazil), in rectangular polypropylene boxes (30x20x13cm). Four boxes with five animals each were kept under normal conditions of $22^{\circ}\text{C} \pm 2^{\circ}$ of temperature, 50% humidity, adequate ventilation and exhaustion, and a photoperiod of 12 hours. The mice were fed animal feed and water *ad libitum*.

2.2 EXTRACTION AND ANALYSIS OF THE ESSENTIAL OILS (EOS) OF *Egletes viscosa* Less. AND *L. schaueriana* Mart.

Dried flower heads of *E. viscosa* were purchased at a supermarket in the city of Fortaleza (CE, Brazil) in March 2016. The extraction and analysis of this oil were carried out at the research unit of Embrapa Agroindústria Tropical, in Fortaleza (CE, Brazil). For the extraction of the EO, 300 g of flower heads were mixed with 1.5 L of distilled water in a round-bottomed flask (3 L) and underwent hydrodistillation for 4 h in a Clevenger apparatus. Subsequently, the essential oil ($R = 1.2\%$, v/m) was collected, centrifuged (2000 RPM; 10 min), dried with anhydrous sodium sulfate, and stored in an amber bottle at -20°C for later analysis by gas chromatography with mass spectrometry (GC-MS) and flame ionization detection (GC-FID).

The specimens of *L. schaueriana* were collected in March 2015 ($8^{\circ}22'58.2''$ S, $42^{\circ}18'31.4''$ W) in São João do Piauí (PI, Brazil). A reference sample was deposited in the Leopoldo Krieger Herbarium (CESJ) of the Federal University of Juiz de Fora (MG, Brazil) under registry number 67,395. The essential oil extraction was carried out at the research unit of Embrapa Meio-Norte, in Parnaíba (PI, Brazil). Approximately 2 kg of fresh leaves of *L. schaueriana* were mixed with 3 L of water and underwent hydrodistillation for 3 h in a Clevenger apparatus. The EO ($R = 1.2\%$, v/m) was collected, centrifuged (2000 RPM; 10 min), dried with anhydrous sodium sulfate, and stored in an amber bottle at -20°C for later analysis by gas chromatography with mass spectrometry (GC-MS) and flame ionization detection (GC-FID) in the research unit of Embrapa Agroindústria Tropical, in Fortaleza (CE, Brazil).

2.3 EXPOSURE OF *Mus musculus* TO EOS OF *E. viscosa* AND *L. schaueriana*

The twenty *Mus musculus* females were divided into four experimental groups: two **control groups (C1, C2)**, which were sprayed with distilled water and the oil solvent (ethanol 50%), respectively; and two **treatment groups (T1, T2)**, which were sprayed with the essential oils of *L. schaueriana* and *E. viscosa* diluted in 50% ethanol at a concentration of 50 mg/mL (whose efficacy as acaricide was confirmed in previous studies).

Exposures were performed on 3 consecutive days, with 24-h intervals between them. They were carried out using sterile sprays until the animals were completely wet, as established by Cunha et al. (2017). Approximately 15 mL of each solution (distilled water, 50% ethanol, and essential oils) were used during the bioassay. The experiment time (3 days, 24-h intervals) was determined to simulate the application of commercial acaricides, which must be applied over 3 consecutive days at most.

After exposure, the animals were observed daily for 14 days. On the 14th day, all subjects were euthanized with an overdose of analgesics with ketamine hydrochloride (80 mg/kg MC/IP) and xylazine hydrochloride (20 mg/kg MC/IP) and had their thyroid glands collected. The organ removal procedures were performed by veterinarian Letícia Maria Gráballos Ferraz Hebling (CRMV 5412), according to the methodology approved by the Animal Ethics Committee (CEUA-IB-UNESP/Rio Claro) under protocol number 17/2019.

Table 1. Morphological changes observed in the thyroid of *Mus musculus* in the control groups (C1 and C2) and those exposed to EOs (T1 and T2).

Morphological changes	Control Groups		Treatment Groups	
	Distilled water (C1)	Ethanol 50% (C2)	EO of <i>E. viscosa</i> (T1)	EO of <i>L. schaueriana</i> (T2)
Intact follicles	+	+	-	-
Follicles with altered morphology	-	-	+	+
Hypertrophic follicles	-	-	+	+
Homogeneously stained colloids	+	+	-	+
Colloids with staining variations	-	-	+	+
Colloids with central granulation	-	-	-	+
Disorganized follicular epithelium	-	-	+	-
Vacuolated follicular cells	-	-	-	+
Follicular cells with altered nuclei	-	-	+	-
Increased interstitial connective tissue	-	-	+	-

2.4 HISTOLOGICAL ANALYSIS

After collecting the thyroid glands, they were fragmented and fixed in 4% paraformaldehyde for 7 days. Subsequently, the fragments were transferred to a sodium phosphate buffer solution, where they remained for 24 h. After this period, they were dehydrated using an increasing series of ethyl alcohol (70, 80, 90, 95, and 100%) at 1-h intervals and, shortly thereafter, embedded in Leica® historesin for 7 days. Following that, they were placed in plastic molds containing resin and polymerizer for another 7 days. Afterward, the blocks were sectioned in a Leica RM2255 microtome. Sections of 3 µm thickness were collected on previously cleaned glass



slides, stained with Harris hematoxylin for 10 min, and washed in running water for 5 min. Next, they were stained with aqueous eosin for 5 min and washed again in running water. After drying in the open air, the slides were permanently mounted on Entellan®, covered with a coverslip, and examined and photographed under a bright-field light microscope.

2.5 HISTOCHEMISTRY [DETECTION OF TOTAL PROTEINS WITH BROMOPHENOL BLUE (FLORES, 1978) AND OF CARBOHYDRATES WITH PAS (PEARSE, 1985)]

For the detection of total proteins, samples were collected from the thyroid gland and fixed in 4% paraformaldehyde for 48 h. Subsequently, they were placed in a sodium phosphate buffer, pH 7.4, and embedded in resin. The sectioned material was stained with bromophenol blue for 1 h at room temperature. Afterward, the material was immersed in 0.5% acetic acid for 1 min and washed in running water for 5 min and in tertiary butyl alcohol.

For the detection of carbohydrates, after being sectioned, the material was rehydrated in distilled water for 1 min and transferred to a periodic acid solution for 10 min. Following this, the material was washed again, transferred to Schiff's reagent for 1 h, washed in sulfur water 3 times for 1 min each, and then washed in running water for 15 min.

Following these procedures, the slides were permanently mounted on Entellan®, covered with a coverslip, dried in an oven, and observed and photographed using a Leica DM750 bright-field light microscope located at the UNESP Department of General and Applied Biology, in Rio Claro (SP).

3 RESULTS

In the present work, histological and histochemical techniques were applied to evaluate the morphology of the thyroid gland of female *Mus musculus* mice exposed to essential oils extracted from *E. viscosa* and *L. schaueriana*, plants with laboratory-proven acaricide properties.

3.1 HISTOLOGY

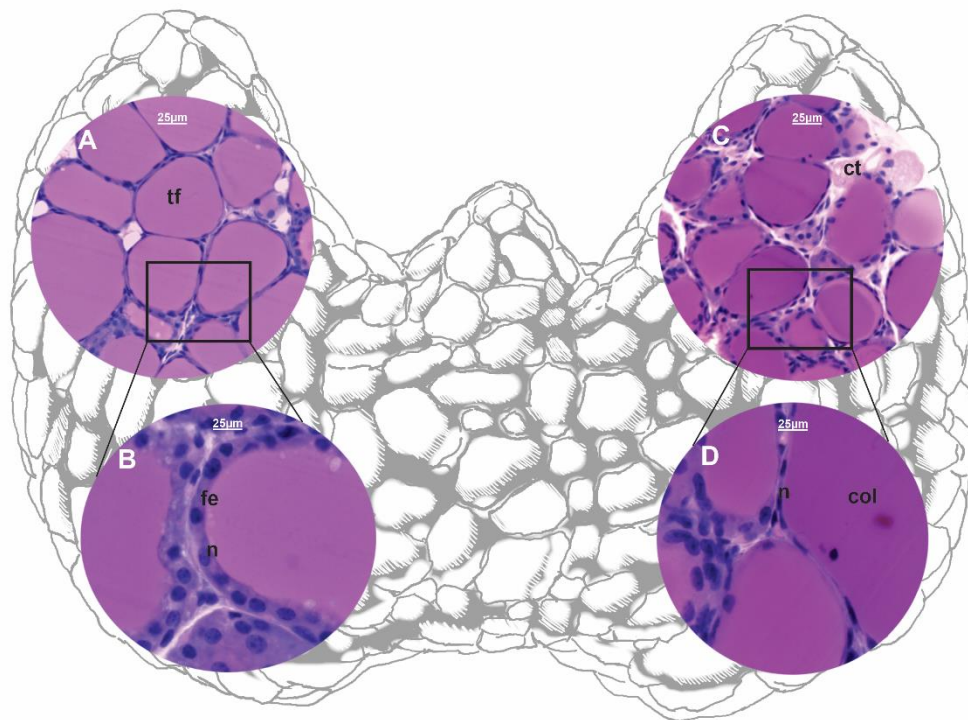
3.1.1 Control groups

The analysis of the thyroid glands belonging to control groups C1 (distilled water) (Fig. 1A-B) and C2 (50% ethanol) (Fig. 1C-D) demonstrated the typical features found in intact thyroid tissue. As described by Junqueira and Carneiro (2017), thyroid follicles externally covered by a simple epithelium made up of follicular cells which varied from squamous to cuboidal (depending

on the activity stage of each follicle), were observed in this study. The mononuclear follicular cells also presented intact and heavily stained nuclei (Fig. 1B and D).

The application of this technique allowed the observation of the colloid in each follicle as it also reacted homogeneously to the staining (Fig. 1A-D). The homogeneous aspect of the colloid changed only in those regions of colloid/follicular epithelium contact, where it looked as if the colloid had been gnawed (small spaces), confirming that the follicular cells were active in the transformation of the colloid into thyroid hormones (Fig. 1A- D).

Figure 1. Scheme and histological sections of the thyroid gland of *Mus musculus* females in control groups C1 (exposed to water, A-B) and C2 (exposed to 50% ethanol, C-D). H&E staining.



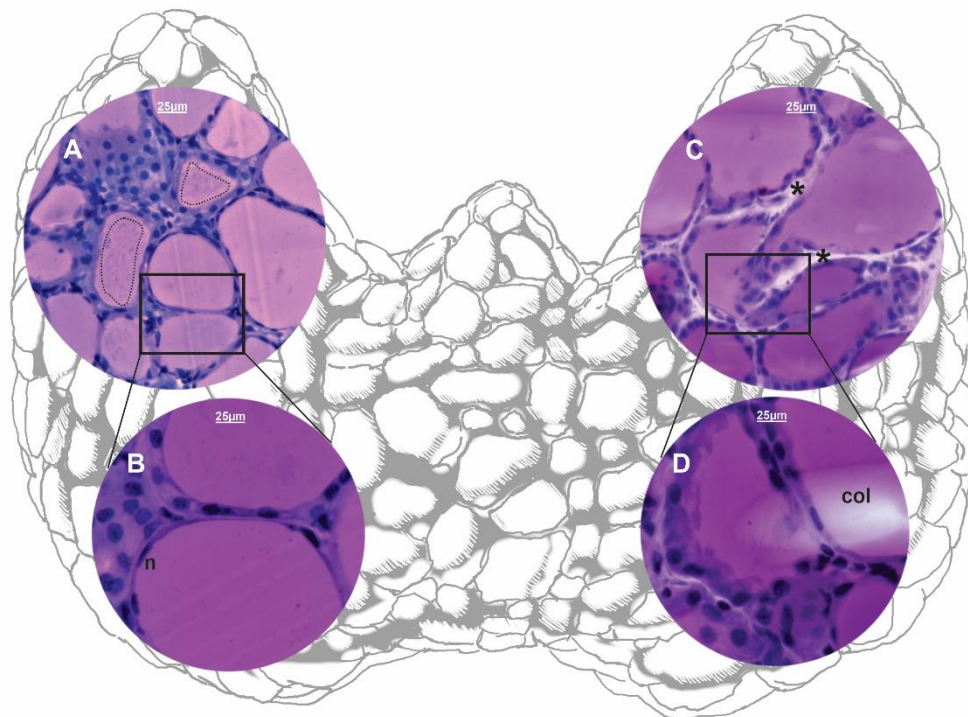
col = colloid; ct = connective tissue; fe = follicular epithelium; n = nucleus; tf = thyroid follicle. Bar = 25 µm.

3.1.2 Treatment group with *L. schaueriana* at a 50 mg/mL concentration

In the thyroids of the animals in the treatment group T1, which had been exposed to *L. schaueriana* oil, morphological changes were also observed, indicating that these glands would have the functions of synthesis/transformation of colloid into thyroid hormones physiologically compromised. It could be observed that the follicular cells showed cytoplasmic vacuolation, flattening of the follicular epithelium, that is, the cells were squamous and had nuclear pyknosis, suggesting cellular inactivation processes (Fig. 2 A-B).

Moreover, the colloid in the follicles was not always homogeneous and, in many of them, a very fine granulation could be observed (Fig. 2A). Also, in some of them, the perimeter of the follicle was less stained than its central region (Fig. 2A), indicating that the secretion changed as well.

Figure 2. Scheme and histological sections of the thyroid of *Mus musculus* females in treatment groups T2 (exposed to *L. schaueriana* essential oil at a concentration of 50 mg/mL, A-B) and T1 (exposed to *E. viscosa* essential oil at a concentration of 50 mg/mL, C-D). H&E staining.



col = colloid; n = nucleus; * = interfollicular space; dashed line= granulation of the colloid in the central region of the follicle. Bar = 25 µm.

3.1.3 Treatment group with *E. viscosa* at a 50 mg/mL concentration

The follicles of the thyroid glands of the animals in the treatment group T2, which had been exposed to *E. viscosa* essential oil at a concentration of 50 mg/mL, showed morphological characteristics which indicate that changes were occurring due to this exposure. Most of the follicular cells in the follicles lost their cuboidal shape and became squamous, which may suggest that the follicles had decreased their activity in the synthesis/transformation of the colloid into thyroid hormones (Fig. 2 C-D). This alteration was clearly noticed in the nuclei of the follicular cells, which, along with the change in morphology of the cell, went from round to flat and pyknotic (Fig. 2C-D).



The colloid in the follicles virtually did not change, except for some of them which had a weaker reaction to the staining (Fig. 2D). On the other hand, it was clear that the rounded morphology of the follicles had changed as indentations could be observed by the follicle walls (Fig. 2C-D). This also disorganized the follicular cells, which certainly altered the functioning of the follicles. Furthermore, the interstitial spaces filled by connective tissue present between the follicles increased greatly in the thyroids of the subjects exposed to *E. viscosa* (Fig. 2C).

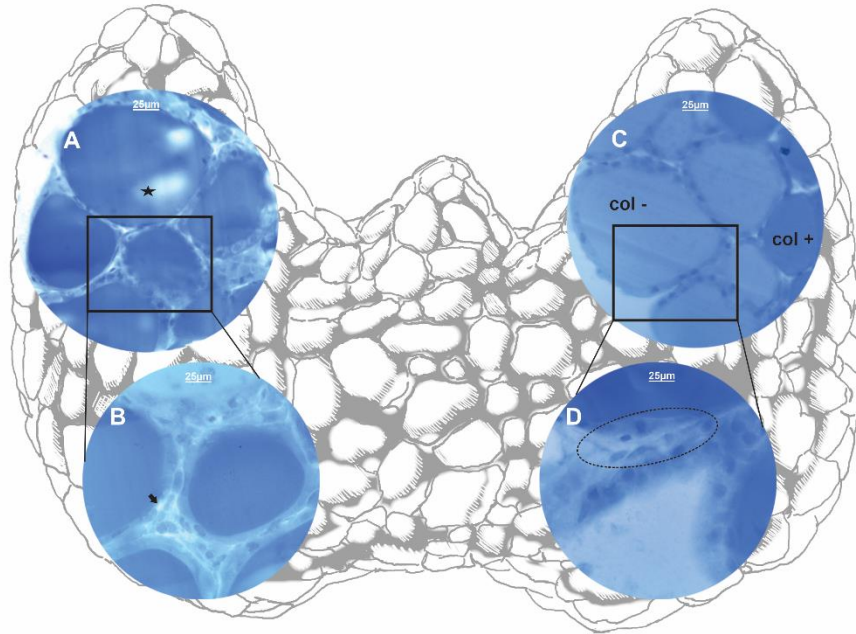
3.2 HISTOCHEMISTRY

3.2.1 Detection of Proteins (Bromophenol blue)

The application of histochemical techniques to the observation of the thyroid glands exposed to the oils of *E. viscosa* and *L. schaueriana* confirmed the results obtained from the histological assays, that is, the exposure to these essential oils caused significant changes in these glands.

Bromophenol blue was used for the detection of proteins. The results of the assay showed that the colloids of the follicles of the glands exposed to *L. schaueriana* were the ones that suffered the greatest changes. Blank spaces were observed in them, showing changes in proteins (Fig. 3A-B). These were not observed in the subjects exposed to *E. viscosa* oil (Fig. 3C-D). The cytoplasm of follicular cells in the thyroid of subjects exposed to *L. schaueriana* seemed to have changed their constitution as well. Also, vacuoles that had not been stained could be frequently observed (Fig. 3B), and this was not seen in the thyroids of the mice exposed to *E. viscosa* (Fig. 3C-D).

Figure 3. Scheme and histological sections of the thyroid of *Mus musculus* females in treatment groups T2 (exposed to *L. schaueriana* essential oil at a concentration of 50 mg/mL, A-B) and T1 (exposed to *E. viscosa* essential oil at a concentration of 50 mg/mL, C-D). Bromophenol blue staining (detection of proteins).

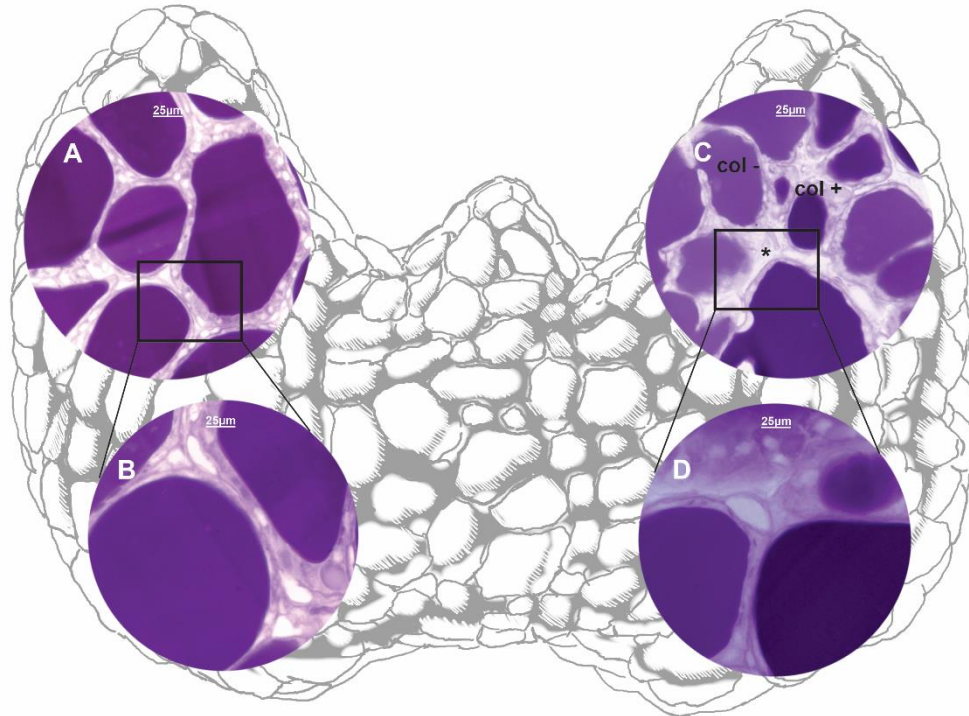


col + = colloid heavily stained; col - = colloid lightly stained; black star= areas in the colloid with no staining; black arrow = cytoplasmic vacuolation; dashed line = epithelial disorganization. Bar = 25 µm.

3.2.2 Detection of Carbohydrates (PAS)

The periodic acid–Schiff (PAS) staining technique was used to detect carbohydrates. It made the presence of colloids in the follicles very evident and, in general, demonstrated that only the glands exposed to *E. viscosa* oil were stained more intensely (heavy or moderate stains) compared to those exposed to *L. schaueriana* oil (Fig. 4A-D).

Figure 4. Scheme and histological sections of the thyroid of *Mus musculus* females in treatment groups T2 (exposed to *L. schaueriana* essential oil at a concentration of 50 mg/mL, A-B) and T1 (exposed to *E. viscosa* essential oil at a concentration of 50 mg/mL, C-D). PAS staining (detection of carbohydrates).



col + = colloid heavily stained; col - = colloid lightly stained; *= interfollicular space; Bar = 25 µm.

4 DISCUSSION

Currently, natural bioactive products, mainly those extracted from plants, have been used as pesticides and acaricides and have responded quite satisfactorily to tests carried out in the laboratory, suggesting that they can be considered an efficient alternative to the control of several arthropods, including ticks (REMEDIO et al., 2014; ROMA et al., 2015; ANHOLETO et al., 2017b; QUADROS et al., 2020; KONIG et al., 2021). However, despite their effectiveness in eliminating or even reducing the reproductive capacity (mainly) of these ectoparasites, there is still little information on their mode of action in non-target organisms and, most importantly, on the safe doses hosts could be given without causing any damage. In this sense, the present study aimed to demonstrate the effects caused by exposure to the essential oils (EOs) of *Egletes viscosa* and *Lippia schaueriana*, at concentrations of 50mg/mL, on the thyroid gland of female *Mus musculus*, used to simulate non-target organisms (tick hosts).

Studies recently performed by Quadros et al. (2020) showed that essential oils are a complex mixture of natural and volatile organic compounds belonging mostly to the class of terpenoids. This is considered the largest chemical class of plant active ingredients and includes



monoterpenes, diterpenes, and sesquiterpenes. Among these, various monoterpenes have been proposed as potential insecticides and acaricides and, therefore, have been used as active principles of pesticides (BOŽOVIC; PIROLI; RAGNO, 2015).

This work presented data on the exposure of *Mus musculus* female to essential oils from *E. viscosa*, whose major component is monoterpene cisisopinocarveyl acetate, and from *L. schaueriana*, whose major component is monoterpene piperitenone oxide. These compounds were characterized, respectively, in previous studies carried out by Vieira et al. (2006) and Souza et al. (2018).

The histological and histochemical analysis performed in this study demonstrated the morphological reaction of the thyroid of *M. musculus* females after their exposure to these oils. This endocrine gland regulates a large part of mammalian metabolism, and its integrity is essential for the efficient performance of its functions (JUNQUEIRA; CARNEIRO, 2017).

It was observed that, as a result of their exposure, the main morphological changes occurred in the thyroid follicles, as well as in the interfollicular spaces. They ranged from changes in the morphology of the follicular cells, which went from cuboidal to squamous (flattened) with nuclei that went from active (dispersed chromatin) to less active (pyknotic), to the disorganization of the follicular epithelium and hypertrophy of the follicle itself.

Part of the alterations observed in the follicular cells, mainly the morphological ones (change in shape), were probably due to the inhibition of their activity in the transformation of colloid into thyroid hormone, caused by the presence of toxic compounds in the system. Despite not all thyroid follicles having a simultaneous synthesis and transformation activity of colloid in the same gland, the presence of thyroid follicles surrounded mostly by a squamous epithelium could indicate that they were in a phase of lower activity in the synthesis/transformation of thyroid hormone components. It could also be inferred that the hypertrophy of some follicles could be occurring because of the greater volume of thyroglobulin stored in the colloid and that it was not being actively absorbed (JUNQUEIRA; CARNEIRO, 2017; SAKR; STEENKAMP, 2021). In a healthy thyroid gland, the thyroglobulin protein (TG) in the colloid would be absorbed by the follicular cells on a regular basis as it is necessary for the synthesis of thyroid hormones (JUNQUEIRA; CARNEIRO, 2017).

Other studies carried out on the exposure of non-target organisms to natural and synthetic acaricides also showed that, when the thyroid gland is under toxicity conditions, it becomes inactive, being morphologically characterized by the hypertrophy of the thyroid follicles, which simultaneously become surrounded by a squamous epithelium and no longer by a cuboidal one



(CAPEN; MARTIN, 1989; CUNHA et al., 2017; REQUENA et al., 2019; SAKR; STEENKAMP, 2021).

Moreover, the results obtained in this study showed that the essential oil of *E. viscosa* at a concentration of 50 mg/mL not only inhibited the degree of thyroid activity but also led to degenerative changes in the tissue, verified by the presence of pyknotic nuclei in the follicular cells, and to the appearance of interfollicular spaces (vacuolated). These were larger and more apparent than those caused by the exposure to *L. schaueriana*, suggesting that there was an accumulation of interstitial fluid in the spaces and the possible formation of edema in the gland due to the toxicity. Hossain (2019) reported this same type of change in the thyroid of rabbits exposed to carbimazole (hypothyroidism inducer), suggesting that the accumulation of fluid and the formation of edema between the thyroid follicles was probably because of a change in the permeability of the blood vessels in the region, which would be unable to remove the liquid due to the intoxication. This hypothesis was also considered by Ferreira et al. (2007) and Cunha et al. (2017) in studies on the thyroid of mice exposed to propylthiouracil (hypothyroidism inducer) and to thymol and fipronil (natural and synthetic acaricides, respectively).

After the exposure to *L. schaueriana* oil, important changes were observed in the thyroid, including cytoplasmic vacuolation in follicular cells and morphostructural disorganization of the follicular epithelium itself. These were, however, less significant than those observed after the exposure to *E. viscosa* oil. Assuredly, in both cases, such changes, although different, resulted in the inactivity or inhibition of thyroid activity and the disorganization of its architecture.

The exposure to the essential oils of these two plants also led to changes in the composition of the colloids contained within the follicles. These, when stained for the detection of proteins and carbohydrates, had a reaction that ranged from weakly to strongly positive when compared with the follicular colloid from the subjects in the control groups. Such findings corroborate what Cunha et al. (2017) observed in studies on the thyroid of female *Mus musculus* exposed to the acaricides fipronil and thymol.

Thus, in general, the present work provided unprecedented data which demonstrated that the thyroid, an important endocrine gland that regulates many metabolic functions, underwent morphological and, consequently, physiological changes. Certainly, these entailed the loss of its morphophysiological integrity, which resulted from the exposure to essential oils of *E. viscosa* and *L. schaueriana*, and called attention to the use of acaricides that, despite being natural (composed of natural bioactive compounds), caused severe damage to the thyroid of female mice exposed to



them at a concentration of 50 mg/mL. These damages are often irreversible and would definitely harm the physiology of the animals.

It is also noteworthy that the unprecedented information on the use of these (natural) essential oils as acaricides made available here reinforces the importance of studies on the toxicity of substances with acaricidal potential regarding the exposure of non-target organisms. Those should also include compounds of natural origin, which are often considered harmless and safe for use in pest control, including ticks.

ACKNOWLEDGMENTS

We would like to thank the São Paulo Research Foundation (FAPESP – processes No. 2019/02831-3, 2019/20185-1, and 2018/02999-9), the Coordination for the Improvement of Higher Education Personnel (CAPES; financing code – 001), and the National Council for Scientific and Technological Development (CNPq; productivity scholarship PQ-1A) for the financial support of this work.



REFERENCES

- Anholeto, I. A. et al. Potential action of extract of *acmella olearacea* (L.) R.K. Jansen to control *Amblyomma cajennense* (Fabricius, 1787) (Acari: Ixodidae) ticks. *Ticks and Tick-borne Diseases*, v. 8, n. 1, p. 65-72, 1 Jan. 2017.
- Araújo, A. A. S. et al. Antinociceptive activity and toxicological study of aqueous extract of *Egletes viscosa* Less (Asteraceae). *Brazilian Journal of Pharmaceutical Sciences*, v. 44, n. 4, p. 707-715, out. 2008.
- Borges, I. M. F. et al. Resistência carrapaticida em larvas de *Rhipicephalus sanguineus* (Acari: Ixodidae) de Goiânia – GO, Brasil. *Revista de Patologia Tropical*, v. 36, p. 87-95, 2007.
- Božovic, M.; Piroli, A.; Ragnó, R. *Mentha suaveolens* Ehrh. (Lamiaceae) essential oil and its main constituent piperitenone oxide: biological activities and chemistry. *Molecules*, v. 20, n. 5, p. 8605-8633, 13 maio 2015.
- Calou, I. B. F. et al. Topically applied diterpenoids from *Egletes viscosa* (Asteraceae) attenuate the dermal inflammation in mouse ear induced by tetradecanoylphorbol 13-acetate- and oxazolone. *Biological and Pharmaceutical Bulletin*, v. 31, n. 8, p. 1511-1516, ago. 2008.
- Camargo-Mathias, M. I. *Inside Ticks: Morphophysiology, Toxicology and Therapeutic Perspectives*. 1 ed. São Paulo: Editora UNESP, 2018.
- Capen, C. C.; Martin, S. L. The effects of xenobiotics on the structure and function of thyroid follicular and C-cells. *Toxicologic Pathology*, v. 17, n. 2, p. 266 – 293, 1989.
- Cunha, A. N. Aspectos químicos do estudo multidisciplinar (químico, farmacológico, botânico e agrônomo) de *Egletes viscosa* Less. 2003. Tese de doutorado – pós graduação em química, Universidade Federal do Ceará, 2003.
- Cunha, N. C. et al. First identification of natural infection of *Rickettsia rickettsii* in the *Rhipicephalus sanguineus* tick, in the state of Rio de Janeiro. *Pesquisa Veterinária Brasileira*, v. 29, n. 2, p. 105-108, fev, 2009.
- Cunha, E. L. R. Da et al. Histopathological changes in the liver and thyroid of mice (*Mus musculus*) caused by the acaricides: fipronil and thymol. *Journal of Histology and Histopathology*, v. 4, n. 1, p. 9, 2017.
- Dantas-Torres, F. Biology and ecology of the brown dog tick, *Rhipicephalus sanguineus*. *Parasites & Vectors*, v. 3, p. 1-11, 2010.
- Dantas-Torres, F.; Otranto, D. Further thoughts on the taxonomy and vector role of *Rhipicephalus sanguineus* group ticks. *Veterinary Parasitology*, v. 208, p. 9-13, 2015.
- Dantas-Torres, F. Species concepts: what about ticks? *Trends in Parasitology*, v. 34, n. 12, p. 1017-1026, 1 dez. 2018.
- Ferreira, E. et al. Model of induction of thyroid dysfunctions in adult female mice. *Arquivo Brasileiro de Medicina Veterinária e Zootecnia*, v. 59, p. 1245-1249, 2007.



Firenzuoli, f.; gori, l. Herbal medicine today: clinical and research issues. Evidence-based complementary and alternative medicine, v. 4, n. S1, p. 37-40, 2007.

Hossain, a. O. Carbimazole and its effects on thyroid gland of female rabbits. Prof. Rk sharma, v. 13, n. 3, p. 310, 2019.

Junqueira, l. C.; carneiro, j. Histologia básica. 13ª edição. Rio de janeiro - rj: guanabara koogan, 2017.

Konig, i. F. M. Et al. Repellent activity of acetylcarvacrol and its effects on salivary gland morphology in unfed *rhhipicephalus sanguineus* sensu lato ticks (acari: ixodidae). Ticks and tick-borne diseases, p. 101760, 4 jun. 2021.

Lee, d. Et al. Diterpene glycosides from *egletes viscosa*. Planta medica, v. 71, n. 8, p. 792-794, ago. 2005.

Lew-tabor, a. E.; rodriguez valle, m. A review of reverse vaccinology approaches for the development of vaccines against ticks and tick-borne diseases. Ticks and tick-borne diseases, v.7, n.4, p.573-585, 2016.

Lorenzi, h.; mattos, r. Plantas medicinais no brasil: nativas e exóticas. Nova odessa: instituto plantarum, 2008.

Martins, c. M. Estudos da cinética de secagem e extração de compostos bioativos presentes em *egletes viscosa* less (macela-da-terra). 2018. Tese de doutorado – pós graduação em química, universidade federal do ceará, 2018.

Moerbeck, l. Et al. *Rickettsia* (rickettsiales: rickettsiaceae) vector biodiversity in high altitude atlantic forest fragments within a semiarid climate: a new endemic area of spotted-fever in brazil. Journal of medical entomology, v. 53, n. 6, p. 1458-1466, 1 nov. 2016.

Nava, s. Et al. Mitochondrial dna analysis of *rhhipicephalus sanguineus* sensu lato (acari: ixodidae) in the southern cone of south america. Veterinary parasitology, v. 190, n. 3-4, p. 547-555, 21 dez. 2012.

Ndawula, c.; tabor, a. E. Cocktail anti-tick vaccines: the unforeseen constraints and approaches toward enhanced efficacies. Vaccines, v.8, n.3, p. 457, 19 ago. 2020.

Nolan, j. Mechanisms of resistance to chemicals in arthropod parasites of veterinary importance. Veterinary parasitology, v. 18, p. 155-166, 1985.

Oliveira, p. R.; bechara, g. H.; camargo-mathias, m.i. evaluation of cytotoxic effects of fipronil on ovaries of semi-engorged *rhhipicephalus sanguineus* (latreille, 1806) (acari: ixodidae) tick female. Food and chemical toxicology, v. 46, p. 2459-2465, 2008.

Oliveira, p. R. De et al. Action of the chemical agent fipronil on the reproductive process of semi-engorged females of the tick *rhhipicephalus sanguineus* (latreille, 1806) (acari: ixodidae). Ultrastructural evaluation of ovary cells. Food and chemical toxicology, v. 47, n. 6, p. 1255-1264, 1 jun. 2009.



Oliveira, p.r.; camargo-mathias, m. I. 10 – controlling ticks (methods). In: camargo-mathias, m. I. (ed.) Inside ticks: morphophysiology, toxicology and therapeutic perspectives. 1th. Ed. São paulo: editora unesp, 2018. P. 83-85.

Ortega-morales, a.l. et al. Detection of *rickettsia* spp. In *hipicephalus sanguineus* (senso lato) collected from free-roaming dogs in coahuila state, northern mexico. Parasites and vectors, v. 12, n. 1, p.130, 26 mar. 2019

Pereira, m. C. Os óleos essenciais de *egletes viscosa* (asteraceae) e *lippia schaueriana* (verbenaceae) e seus potenciais efeitos sobre a biologia reprodutiva e a morfologia (órgão de gené, ovário e singânglio) de carrapatos *hipicephalus sanguineus* sensu lato (acari: ixodidae) e sobre o fígado e a tireoide de camundongos *mus musculus* a eles expostos. 2021. Dissertação de mestrado (biologia celular e molecular), instituto de biociências, unesp campus rio claro, são paulo. 2021.

Pereira, r. De c. A.; bezerra, m. A. E.; almeida, f. Das c.s. produção de mudas de macela (*egletes viscosa* (L.) Less.) Por sementes. Brasília: embrapa, 2018. Disponível em: <https://ainfo.cnptia.embrapa.br/digital/bitstream/item/185091/1/cot18011.pdf>. Acesso em: 30 jul. 2022.

Quadros, d. G. Et al. Plant-derived natural compounds for tick pest control in livestock and wildlife: pragmatism or utopia? Insects, v.11, n.8, p.490, 2020.

Requena, m. Et al. Environmental exposure to pesticides and risk of thyroid diseases. Toxicology letters, v. 315, n. 15, p.55-63, 2019.

Remedio, r. N. Et al. Morphological alterations in the synganglion and integument of *hipicephalus sanguineus* ticks exposed to aqueous extracts of neem leaves (*azadirachtaindica* a. Juss). Microscopy research and technique, v. 77, n. 12, p.989-998, dez. 2014.

Roma, g. C. Et al. Effects of andiroba (*carapa guianensis*) oil in ticks: ultrastructural analysis of the synganglion of *hipicephalus sanguineus* (latreille, 1806) (acari: ixodidae). Acta tropica, v. 141, p. 7 – 15, 2015.

Saka, m.; tada, n. Acute and chronic toxicity tests of systemic inseticides, four neonicotinoids and fipronil, using the tadpoles of thw western clawed frog *silurana tropicalis*. Chemosphere, v.270, p. 129418, 1 mai. 2021.

Sakr, s.; steenkamp, v. Zine oxide nanoparticles induce oxidative stress and histopathological toxicity in the thyroid gland and liver of rats. Toxicological & environmental chemistry, p. 1-24, 2021.

Šlapeta, jan et al. *Rhipicephalus linnaei* (audouin, 1826) recognised as the “tropical lineage” of the brown dog tick *hipicephalus sanguineus* sensu lato: neotype designation, redescription, and establishment of morphological and molecular reference. Ticks and tick-borne diseases, v. 13, n. 6, p. 102024, 2022.

Singh, g.; maurya, s. Antimicrobial, antifungal and insecticidal investigations on essential oils: an overview. Natural product radiance, v.4, n. 3, 2005.



Silva, a. B. Et al. *Rickettsia rickettsii* infecting *riphicephalus sanguineus* sensu lato (latreille 1806), in high altitude atlantic forest fragments, ceará state, brazil. *Acta tropica*, v. 173, p. 30=33, set. 2017.

Sonenshine, d. E.; roe, r. M. *Biology of ticks* (vol. 1). Vol. 1 ed. New york: oxford university press, 2014.

Souza, a. V. De et al. Chemical composition of essential oil of leaves from *lippia schaueriana* mart. Collected in the caatinga area. *Molecules*, v. 23, n. 10, p. 2480, 27 set. 2018.

Vieira, g. A. B. Et al. Chemical composition of teas from two cultivated chemotypes of *egletes viscosa* ('macela-da-terra'). *Journal of the brazilian chemical society*, v. 17, n. 1, p.43-47, 2006.