



## More effective diagnostic methods for the early evaluation of congenital heart disease: A systematic review

### Métodos diagnósticos mais eficazes para a avaliação precoce de cardiopatia congênita: Uma revisão sistemática

DOI: 10.56238/isevmjv3n2-008

Receipt of originals: 02/20/2024

Publication acceptance: 07/03/2024

Jennifer Maria Moschen<sup>1</sup>, Luiza Rossi Kuritza<sup>2</sup>, Jhulie Any Souza<sup>3</sup>, Ariana Centa<sup>4</sup>.

#### ABSTRACT

**Objectives:** To evaluate which diagnostic methods are most effective for the early evaluation of possible cardiac abnormalities in the uterine and neonatal period, in order to analyze the impact of prenatal tests and to correlate early diagnosis with the risk of infant mortality. **Method:** a systematic review was carried out using the Science and Pubmed platforms in the period between 2012 and 2022, where the following descriptors were used in the search 'newborns' OR 'premature infants' AND 'congenital heart disease' OR 'congenital heart defects' OR 'baby's heart' AND "early diagnosis" OR "prenatal diagnosis". Subsequently, the articles found were selected according to the inclusion and exclusion criteria previously determined to suit the type of research. **Results:** after analysis of 97 articles, 23 were in the appropriate parameters and were considered in the study, addressing exams such as ultrasonography, nuchal translucency, fetal echocardiography, genetic tests, pulse oximetry, cardiovascular physical examination and echocardiographic reassessment. **Conclusion:** In view of the assumption, it was found that the previous identification of the pathological alteration results in a more improved and prepared therapeutic plan and better psychological acceptance of the parents. Therefore, the importance of disseminating the various methods available and how to perform them correctly to make the early diagnosis of congenital heart diseases and contribute to the reduction of mortality of these newborns is justified.

**Keywords:** Congenital heart disease, Early diagnosis, Prenatal diagnosis, Neonates.

#### INTRODUCTION

Congenital heart disease (CHD) is a structural and functional alteration of the heart. These abnormalities are mostly due to the defect in the embryology of the cardiac system, which occurs from the third to the eighth week of gestation in the fetal embryonic period, and from the

---

<sup>1</sup> Medical Course, Alto Vale do Rio do Peixe University – UNIARP  
Academic League of Cardiology (LACARDIO) – UNIARP

<sup>2</sup> Medical Course, Alto Vale do Rio do Peixe University – UNIARP

<sup>3</sup> Medical Course, Alto Vale do Rio do Peixe University – UNIARP  
Academic League of Cardiology (LACARDIO) – UNIARP

Translational Health Research Laboratory – UNIARP

<sup>4</sup> Medical Course, Alto Vale do Rio do Peixe University – UNIARP  
Academic League of Gynecology and Obstetrics (LAGO) – UNIARP  
Translational Health Research Laboratory – UNIARP



first month of gestation the formation of the atrioventricular septum (AV) that separates the cardiac chambers begins.<sup>1, 2, 3</sup>

Cardiac malformations occur due to various causes, mostly of maternal origin, such as lifestyle habits, pre-existing diseases and genetic factors.<sup>4, 5</sup>

In addition, heart defects were more evident in preterm infants who were underweight and in the case of twins. Heart diseases are classified according to their severity in relation to the involvement of the cardiopulmonary system, with or without the presence of cyanosis.<sup>6</sup>

Cardiac failures that do not present cyanosis are more prevalent and less aggressive.<sup>7</sup> The most important of this group can be mentioned as atrial septal defect (ASD), established by the defect in the division of the atria; coarctation of the aorta (AC), which occurs due to compression of the aortic segment; aortic stenosis (AS), which occurs due to an abnormality in the constriction of the valves; ventricular septal defect (VSD), which results from a failure in the division of the ventricle, with increased flow in the lung; and patent ductus arteriosus (PDA), which leads to an atrioventricular septal defect. With regard to cyanotic diseases, the pathology most frequently characterized by poor oxygenation of the blood is tetralogy of Fallot (FT4). This pathology is characterized by high cyanosis, by damaging the path from air to the lungs.<sup>8, 9</sup>

Based on these findings, it can be seen that an effective diagnosis is essential to improve the quality of life of these patients. Thus, the main tests performed during prenatal care are fetal ultrasonography (USG), nuchal translucency (NT) and fetal echocardiography, which are more useful for identifying heart defects in the first three months of pregnancy. Ultrasound is routine in the prenatal care of pregnant women, and it is essential to perform this test between the eleventh and fourteenth weeks of gestation. During USG, NT is also measured, which, if increased, may be related to congenital problems.<sup>10</sup>

Echocardiography is a non-invasive test that serves to evaluate the functioning of the heart, and can be performed as early as the eighteenth week, as the chambers of the heart can already be visualized. The period from the twenty-fourth to the twenty-eighth week of pregnancy is the time that increases the chance of early diagnosis of heart diseases. Some factors make it difficult to perform the test, such as excess amniotic fluid and high body weight in pregnant women. Thus, because it has a decisive, positive characteristic and good specificity, fetal echocardiography is the gold standard for documenting cardiac malformations.<sup>11</sup> Thus, echocardiography is the ideal test for the recognition of congenital heart disease, but it is only performed in the prenatal period when the pregnant woman presents some life-threatening complication.<sup>12th</sup>



With regard to the above-mentioned methodologies, the echocardiogram is only performed in the Unified Health System (SUS) when the maternal history presents predisposing factors for a high-risk pregnancy.<sup>13</sup> Thus, the importance of complementary prenatal exams is revealed, because the earlier the diagnosis of congenital heart diseases is made, the more promising the prognosis becomes, as well as the care of the newborn and the path to an effective therapy, whether surgical or not, with the objective of increasing the life expectancy of this newborn.<sup>14th</sup>

In addition, screening through neonatal physical examination, performed in detail by the physician, and pulse oximetry evaluation, which can be performed by nurses, is also important.<sup>13</sup> Covering the period after birth, among the clinical manifestations that the newborn may present are bluish extremities, the appearance of a heart murmur and increased heart rate.<sup>15</sup> In neonates without symptoms, the decrease in oxygen in the blood verified by pulse oximetry helps to initiate the cardiac malformation protocol. After a variation in saturation is found, it is necessary for the newborn to undergo more specific tests to establish a diagnosis.<sup>16</sup> In this context, the echocardiogram (ECHO) comes in, which is a sensitive diagnostic method that recognizes the pathology and speeds up the intervention necessary to improve the prognosis.<sup>17th</sup>

Therefore, considering the importance of early diagnosis of intrauterine and newborn cardiac anomalies, it is extremely important to know the best techniques available for this and how their proper use during prenatal care is essential to develop an effective intervention as soon as possible, in order to reduce the mortality of these neonates and improve the patient's prognosis. Thus, this review sought to evaluate which are the most effective diagnostic methods available in health services for the identification of appropriate anomalies, when they should be performed and which of these are accessible to Brazilians within the scope of the SUS.

## **RESEARCH METHODOLOGY**

### **RESEARCH STRATEGY**

Data collection for this systematic review was carried out in July 2022, with the search for articles indexed in the electronic databases PubMed and ScienceDirect. Articles published in full since July 2012 in English were used. The following descriptors were used to conduct the research: "newborns" OR: 'premature infants" AND 'congenital heart disease", OR 'congenital heart defects" OR 'baby's heart" AND 'early diagnosis" OR "prenatal diagnosis".

The words presented were designated in the titles and abstract fields. For tracking publications associated with the logical operators "AND" to relate terms, and "OR" to sum terms.



On the other hand, articles on clinical trials, review articles (narrative, integrative, and systematic), and *in vitro* and animal research reports, book chapters, theses, dissertations, conference proceedings, technical reports, and ministerial documents were excluded from the approach, as well as articles that did not address the importance of adequate diagnosis of congenital heart disease in neonates.

## EXPERIMENTAL DESIGN

Following what was proposed in the methodology, the total number of articles found in these databases was 97, after submission to the evaluation criteria, 23 studies suitable for systematic review resulted.

The process was carried out by searching for articles in the determined databases, and duplicate and review articles were excluded. Sequentially, we evaluated whether the title and abstract addressed the research theme, and then the inclusion and exclusion criteria were applied. Subsequently, the articles were considered in their entirety, and studies that did not present a relationship between congenital heart disease and neonates were not considered.

The tool used to assess the quality of the research and the risk of bias was the *Quality in Prognosis Studies* (QUIPS), which analyzed the articles as follows: participation in the study, abandonment of the study, evaluation of the result, clarity and objectivity of the study, and statistical analysis. Thus, the articles were classified as having low, moderate or high risk of bias.<sup>18th</sup>

## RESULTS

According to the experimental design, the search using the aforementioned descriptors resulted in a total of 97 articles, of which 70 were found in PubMed and 27 articles in ScienceDirect. Of these, 21 duplicate articles and 25 review articles were excluded. Sequentially, they were evaluated according to the title, in which fifteen elements were discarded, and by the abstract, in which one was dismissed, as they did not address the research theme and were submitted to the application of the inclusion and exclusion criteria. Subsequently, the articles were considered in full, and studies that did not present a relationship between congenital heart disease and newborns were not considered, thus eliminating twelve documents. Thus, in total, the research effectively selected 23 publications (Figure 1).

In addition, the selected articles were evaluated using the QUIPS tool according to the risk of bias, as shown in Table 1. None of the articles presented a high risk of bias, and all were



in agreement with the study.

The articles analyzed were published between 2012 and 2022. Of the 23 articles, two were conducted in Turkey (#1, #6), two in China (#2, #15), two in the United States of America (#9, #18), two in Japan (#10, #14), two in India (#16, #19), and the remaining countries with one study, Poland, Mexico, Germany, United Kingdom, Pakistan, South Korea (#11), Brazil (#12), Italy (#13), Argentina (#17), United Arab Emirates (#20), Australia (#21), Spain (#22), Chile (#23).

Among the 23 articles selected for this systematic review, eight studies evaluated the diagnosis of CHD during prenatal care and also in neonates, five analyzed only in the prenatal period and ten in neonates only.

## PRENATAL DIAGNOSIS

In view of the articles analyzed, those that addressed the diagnosis of CHD during the prenatal period emphasized US between 18 and 21 weeks, being performed primarily in the second trimester of gestation before 28 weeks (#2, #3, #4, #5, #10, #11, #13, #14, #15, #17). Similarly, the combined four-chamber and three-vessel ultrasound was discussed in four articles, which demonstrated a relevance to the cardiac structural part (#5, #14, #15, #23). In addition, two articles (#11, #15) mentioned the importance of NT being performed between 11 and 13 weeks + six days. In addition, fetal echocardiography is an important test that is performed together with ultrasonography in the same period and its importance was mentioned in articles #1, #2, #5, #12, #13, #15, #22, #23.

At this point in the fetal echocardiogram, more specific modes for analysis were mentioned, such as color Doppler (#5, #15, #10, #11, #23), B mode (#5, #23) and also M mode (#23). And with regard to technological innovation in the area, some research has addressed the genetic issue, as in article #3, which pointed out the chromosomal microarray test, and #11, which brought the screening of aneuploidies and chromosomal testing for anomalies.

When it comes to establishing a more effective method in prenatal care, US has limitations, either because of the way the fetus is, the mother's overweight, and the professional's technique (#10). In addition, there is a difficulty in visualizing minute structures, so the echocardiogram is more consistent and sensitive to the diagnosis of CHD in the fetus (#15). As well as the incorporation of color doppler for greater specificity (#11).



## DIAGNOSIS IN THE NEONATAL PERIOD

With regard to the diagnosis in the post-birth period, pulse oximetry was indicated in 16 of the 23 articles evaluated (#2, #4, #6, #7, #8, #9, #10, #13, #14, #16, #17, #18, #19, #20, #21, #22). The articles evaluated indicated different times after birth for the performance of the test, indicating that pulse oximetry should be performed in the first four hours of life (#19), before the first 12 hours of life (#22), after 24 hours (#6, #8), between 24 and 48 hours of life, between 24 and 72 hours, between 48 and 72 hours (#13), up to seven days after birth or before hospital discharge (#17).

Regarding the time that pulse oximetry is analyzed, the articles (#6, #8, #13, #16, #20, #21) reported a decrease in false positives when it is performed after 24 hours of the newborn's life, due to the time it is necessary to avoid physiological interference.

Also with regard to the performance of pulse oximetry in neonates, there were divergences regarding the ideal location of the sensor, which can be placed on the right hand and right foot, index finger of the right hand and big toe of the left foot, pre and post ductal (#8, #22) or on all limbs (#19). It is noteworthy that in one of the articles, an automatic electronic device was used to perform PB (#20).

If the result of the oximetry test is abnormal in the neonate, it is recommended to perform an echocardiogram to confirm the diagnosis (#2, #4, #6, #9, #13, #16, #23). In the article, ECHO should be performed within 7 days and in article it is performed between the first and fourth day of life.

Regarding the echocardiogram performed in the neonate, the objective was to reassess the diagnosis of congenital heart disease in the prenatal period. In addition, the echocardiogram was addressed in an article (#10), but it is not necessarily a reassessment or diagnostic confirmation test, but rather a routine test in all neonates with or without suspicion of CHD.

The importance of cardiovascular physical examination was also pointed out (#2, #13). The relevance of palpation of peripheral pulses along with cardiovascular physical examination in the first 24 hours and reassessment within 48 to 72 hours (#13) has been demonstrated.

In addition to these above-mentioned tests, the use of the electrocardiogram (#13) was discussed, which can also be performed when the pulse oximetry is altered.

Thus, the studies (#7, #10, #13, #15, #16, #17, #18, #22) reinforced that the best test implemented as screening is pulse oximetry, due to its practicality and benefit in terms of low cost compared to echocardiography.



## DISCUSSION

Congenital heart defects are defined as heart defects in terms of the structure or functionality of the heart, can be severe and without an early diagnosis lead to higher mortality of neonates.<sup>42</sup> In view of this assumption, the present study aimed to analyze the best diagnostic methods.

The diagnosis of CHD in the prenatal period can be made with the aid of tests such as ultrasonography, which allows the evaluation of the growth of the fetus as expected for age, the amount of amniotic fluid present and placental aspects<sup>43</sup>, nuchal translucency that is evaluated early in pregnancy in search of trisomies that may be related to CHD, and fetal echocardiography, which is shown to be a more specific test, Being performed from 18 weeks of gestation, but between 24 and 28 weeks it can present a better visualization of the fetal heart.<sup>11</sup> In addition to these, there are genetic tests that analyze chromosomal sequences in order to find alterations in DNA.<sup>44th</sup>

Regarding the diagnosis in the prenatal follow-up, with regard to the exams performed during the fetal period, it was elucidated that ultrasound related to fetal echocardiography has good sensitivity to detect abnormalities.<sup>45</sup> From this perspective, it was elucidated that there are three types of Doppler that correlate with cardiac malformations, namely: B-mode, M-mode, and color Doppler.<sup>41</sup> Exemplifying the peculiarities of each one, it is possible to regulate the wave frequencies and the type of operating mode to better suit the proposed situation. Mode B is used to distinguish the echogenicity of structural scopes by contrasting the illustration. This method has prominence because it allows the image to be renewed at every moment by the computer, providing images in two dimensions, in a more immediate and functional way. In what adheres to the M mode, it is used in echocardiography because it is related to much higher resolution images to evaluate the functionality of cardiac structures.<sup>46th</sup>

One finding that surprised the authors was the delimiting accuracy of the USG visualization of four chambers of three vessels cited in one of the research articles, which reports good detection of abnormalities in the structure of the heart, but without significant predictive value regarding changes in the valves. However, color Doppler examination showed good observation of valvular dysfunction covering this aspect of CHD.<sup>32</sup> This is justified by the fact that the color doppler grades the blood flow, the fitness of the heart valves, and the integrality of the septum.<sup>47th</sup>

As found in the research, it was noted that the diagnosis of congenital heart diseases in the prenatal period is related to a better prognosis for the newborn because, if necessary, it is



possible to plan a therapeutic interference in 48 hours, thus obtaining a decrease in the death of the neonates.<sup>23</sup> As well as instructing the pregnant woman about the diagnosis and directing them to specialized teams, with the elaboration of a viable delivery room for the newborn.<sup>48th</sup>

For the diagnosis of CHD in prenatal follow-up, the best period for performing the nuchal translucency examination is between 11 and 13 weeks and 6 days of gestation<sup>29</sup> and fetal ultrasonography should be performed from 18 weeks<sup>22</sup>, primarily associated with fetal echocardiography, performed between 20 and 24 weeks.<sup>49th</sup>

In relation to the Unified Health System, the fetal echocardiogram is only performed when the pregnant woman has some risk factor that fits her into the high-risk protocol, if she does not have one, this test with greater specificity will only be available in the private network.<sup>13</sup> Concomitantly, in places where fetal echocardiography is recommended in all pregnant women, the identification of CHD is more significant. This model available in Brazil has a negative impact on the early diagnosis of CHD, as many pregnant women without possible complications end up with underreported sick fetuses.<sup>30th</sup>

The early detection of the malformation enables the psychological preparation of the parents for situations arising from the complication and improves the management of the patient in the delivery room, with the availability of intervention measures.<sup>50th</sup>

When greater technology and financial availability are available, genetic testing can be performed on the parents and fetus in order to address joint chromosomal disorders and aneuploidies.<sup>51</sup> In this context, one of the most current methods is the chromosomal microarray test, which evaluates genome duplications and chromosomal loss mutations.<sup>21, 52</sup> The importance of the discovery in the gestational period improves the prognosis of patients, either by possible early interference and referral to specialized services.<sup>6</sup>

In the postpartum period, diagnostic tests such as pulse oximetry can be performed, a test that does not entail any painful, quick, cheap and good sensitivity process. Contributing to the diagnosis, cardiovascular examination along with oximetry increases detection rates. In this sense, to prove the existence of a defect in the heart of the neonate, the echocardiogram is available, a more expensive and more specific method for diagnosis.<sup>53</sup> In addition to these tests, the electrocardiogram can be used as a complementary method in the diagnosis.<sup>45</sup>

Basic evaluation measures in the neonate, such as physical examination of the newborn and cardiac auscultation in the first hours<sup>20</sup> and the notoriety of repeating the examination between 48 and 72 hours, and the possibility of palpating precordial thrill and peripheral pulses<sup>31</sup>, optimize a complete investigation of the clinical picture. Together, it is worth noting



that the professional's verification allows the identification of the presence of cyanosis in peripheral limbs or central pulmonary involvement.<sup>53rd</sup>

In addition to the neonatal exam, pulse oximetry (OP) is performed, also known in Brazil as the little heart test, which has been widely recommended within the SUS since 2014, when it was implemented.<sup>53</sup> OP is a test performed for functional analysis of the cardiopulmonary system by placing an oximeter in the upper and lower limbs, comparing them with each other.<sup>16.</sup>

Regarding the location and period of investigation, there are divergences between the articles studied, and in Brazil the measurement should be made in the right upper limb (preductal) and any lower limb (postductal) between 24 and 48 hours of life.<sup>54</sup> However, LUNA et al. (2018) highlight that PB should be performed before 12 hours of life, however this approach increases the chance of a false positive result, as the baby's ductus arteriosus completes its closure after 12 to 15 hours of birth.<sup>34,54</sup>

Pulse oximetry in Brazil is considered altered or positive when saturation is less than 95%, or a margin of discrepancy between upper and lower limbs greater than or equal to 3%, and the test should be repeated; If the variation persists, a confirmatory echocardiogram must be performed.<sup>55</sup> In comparison, in Spain a level below 90% is considered an abnormal result, with PO being highly positive, relatively positive between 90 and 94%, and normal, if above 95%.<sup>40</sup> In this sense, the test is a strong method for detecting congenital heart disease in neonates, in addition to being more accessible and cheaper.<sup>26</sup> The implementation of pulse screening in countries such as the United States of America, Finland, Sweden, Norway and China has optimized the identification of disorders in asymptomatic neonates.<sup>56</sup>

From an altered pulse oximetry, we look for methods that confirm the diagnosis in a more specific way, so we have the echocardiogram that can investigate and analyze in more detail the cardiovascular system of the newborn, as it is a resource that allows checking the heart, its main arteries, structures and functionality.<sup>24,57</sup> From the Brazilian perspective, ECHO should be performed within 24 hours in these cases.<sup>58th</sup>

The implementation of echocardiographic screening in babies in the first days of life is relevant, however, because it has a more prominent cost, it is not feasible to perform it in great demand in hospitals, in addition to overloading specialist professionals.<sup>28,58</sup>

Another alternative mentioned in the search for an adequate and early diagnosis was the performance of an electrocardiogram to complement the preconceived diagnosis.<sup>31</sup> The electrocardiogram is a method that records/evaluates the electrical activity in the heart, being easy to manage and inexpensive.<sup>57</sup>



Therefore, a cardiac reassessment after screening tests should be performed, as a small fraction of abnormalities may go unnoticed but still possess considerable clinical value. Therefore, establishments that have this procedure as a routine reduce the risks of a newborn being discharged without an effective diagnosis.<sup>13</sup>

## **CONCLUSION**

Early diagnosis of CHD improves the prognosis of life of neonates, as the risk of mortality of individuals in the first year of life is high. Therefore, special attention and adequate training of health professionals are necessary, effective prenatal screening, oximetry performed at the appropriate time and in the correct way, in addition to the availability of specialist professionals and more advanced tests for differential diagnosis and hospital referral.

## **ACKNOWLEDGMENT**

We would like to thank the Alto Vale do Rio do Peixe University, which provided space for this research.



## REFERENCES

- Sociedade Brasileira de Cardiologia. Cardiopatia congênita afeta 29 mil crianças/ano e 6% morrem antes de completar um ano de vida. [acesso 16 marc 2022]. Disponível em: <https://www.portal.cardiol.br/post/cardiopatia-cong%C3%AAnita-afeta-29-mil-crian%C3%A7as-ano-e-6-morrem-antes-de-completar-um-ano-de-vida>.
- Santos Araújo, Adriny, et al. Congenital heart disease in newborns: prevalence assessment at a teaching Hospital in the city of Juiz de Fora. *Brazilian Journal of Health Review*. 2020; 3: 15919–15932.
- Cónsole-Avegliano, Gloria Miriam. *Embriología molecular de las cardiopatías congénitas*. 1 ed. La plata: EDULP; 2018
- Torres-Romucho, Camilo E., et al. Factores asociados a la supervivencia al año de vida en neonatos con cardiopatía congénita severa en un Hospital Nacional de Perú. *Revista Peruana de Medicina Experimental y Salud Pública*. 2019; 36: 433–441.
- Gomes, Thársis Gabryel. *Investigação citogenômica em pacientes com cardiopatias congênitas [dissertação]*. Botucatu: Universidade Estadual Paulista Júlio de Mesquita Filho; 2018.
- Ramos, Joana Cardoso. *Cardiopatias congénitas no período neonatal-estudo retrospectivo [tese]*. Portugal: Universidade de Coimbra; 2019.
- Sá, Emanuelle, et al. O perfil de crianças com cardiopatias congênitas submetidas à cirurgia cardíaca em um centro universitário do Nordeste. *Revista Inspirar Movimento & Saúde*. 2020; 20: 1-17.
- Belo, Wanessa Alves; Oselame, Gleidson Brandão; Neves, Eduardo Borba. Perfil clínico-hospitalar de crianças com cardiopatia congênita. *Cadernos Saúde Coletiva*. 2016; 24: 216–220.
- Neves, Ram da S. et al. *Cardiopatias congênitas: manifestações clínicas e tratamento*. Revista Científica Online. 2020; 12: 2020.
- Almeida Bastos, Guilherme et al. Ultrassonografia obstétrica como ferramenta didática no rastreamento de patologias fetais. *Revista Práxis*. 2012; 4: 45-50.
- Pedra, Simone RF, et al. Diretriz Brasileira de Cardiologia Fetal-2019. *Arquivos Brasileiros de Cardiologia*. 2019; 112: 600-648.
- Pinheiro, Diesa Oliveira, et al. Accuracy of Prenatal Diagnosis of Congenital Cardiac Malformations. *Revista Brasileira de Ginecologia e Obstetrícia*. 2019; 41: 11–16.
- Silva LDC, Pavão T da CA, Souza JCB, Frias L de MP. Diagnóstico precoce das cardiopatias congênitas: Uma revisão integrativa. *J Manag Prim Health Care*. 2018; 9: 1-24.
- Copado Mendoza, D.Y.; Martínez García, A. J.; Acevedo Gallegos, S. Importancia del diagnóstico prenatal de las cardiopatías congénitas. *Perinatología y Reproducción Humana*. 2018; 32: 127–130.



- Ministério da Saúde. Secretaria de Atenção à Saúde. Departamento de Ações Programáticas Estratégicas. Atenção à saúde do recém-nascido: guia para os profissionais de saúde. 2 ed. Brasília: Ministério da Saúde; 2012.
- De Souza Gomes, Isabella Ellen et al. Benefícios da oximetria de pulso na triagem neonatal para detectar cardiopatias congênitas. *Saúde Coletiva*. 2021; 11: 7339-7348.
- Morhy, Samira Saady, et al. Posicionamento sobre Indicações da Ecocardiografia em Cardiologia Fetal, Pediátrica e Cardiopatias Congênitas do Adulto. *Arquivos Brasileiros de Cardiologia*. 2020; 115: 987–1005.
- Hayden, Jill A. et al. Assessing bias in studies of prognostic factors. *Annals of internal medicine*. 2013;158: 280-286.
- Aydin, Emine et al. Congenital heart defects: the 10-year experience at a single center. *The Journal of Maternal-Fetal & Neonatal Medicine*. 2020; 33: 368-372.
- Zhang, Wen et al. Delayed diagnosis of critical congenital heart defects predicting risk factors and survival rate in newborns in Beijing: a retrospective study. *Journal of International Medical Research*. 2021; 49: 03000605211028028.
- Kowalczyk, Katarzyna et al. Prenatal Diagnosis by Array Comparative Genomic Hybridization in Fetuses with Cardiac Abnormalities. *Genes*. 2021; 12: 2021.
- Atilán-gil, Alfonso et al. Implementation of diagnostic screening for congenital heart disease in Hidalgo, Mexico. *Archivos de cardiología de México*. 2020; 90: 35-41.
- Wolter, Aline et al. Perinatal outcomes of congenital heart disease after emergent neonatal cardiac procedures. *The Journal of Maternal-Fetal & Neonatal Medicine*. 2018; 31: 2709-2716.
- Özalkaya, Elif et al. Early screening for critical congenital heart defects in asymptomatic newborns in Bursa province. *The Journal of Maternal-Fetal & Neonatal Medicine*. 2016; 29: 1105-1107.
- Mawson, Isabel E. et al. Pulse oximetry findings in newborns with antenatally diagnosed congenital heart disease. *European journal of Pediatrics*. 2018; 177: 683-689.
- Shahzad, Muhammad et al. Pulse oximetry as a screening tool for critical congenital heart defects in newborns. *J Pak Med Assoc*. 2017; 67: 1220-3.
- , Amy Peterson; Miller, Stephanie D.; McClain, Monica R. Using state birth defects registries to evaluate regional critical congenital heart disease newborn screening. *Birth Defects Research*. 2017; 109: 1414-1422.
- Kondo, Miyuki et al. Can echocardiographic screening in the early days of life detect critical congenital heart disease among apparently healthy newborns. *BMC Pediatrics*. 2018; 18: 1-6.



- Wie, Jeong Ha et al. Prenatal Diagnosis of Congenital Heart Diseases and Associations with Serum Biomarkers of Aneuploidy: A Multicenter Prospective Cohort Study. *Yonsei medical journal*. 2022; 63: 735.
- Silva, Karina Peres et al. Newborns with congenital heart diseases: Epidemiological data from a single reference center in Brazil. *Journal of prenatal medicine*. 2014; 8: 11.
- Zuppa, Antonio Alberto et al. Clinical examination and pulse oximetry as screening for congenital heart disease in low-risk newborn. *The Journal of Maternal-Fetal & Neonatal Medicine*. 2015; 28: 7-11.
- Itsukaichi, Mina et al. Effectiveness of fetal cardiac screening for congenital heart disease using a combination of the four-chamber view and three-vessel view during the second trimester scan. *Journal of Obstetrics and Gynaecology Research*. 2018; 44: 49-53.
- Xia, Yan et al. The value of outflow tract flow tracing in early pregnancy in the screening of structural malformations of fetal cardiac great arteries. *Annals of Translational Medicine*. 2021; 9:1791.
- Taksande, Amar M. et al. Accuracy of pulse oximetry screening for detecting critical congenital heart disease in the newborns in rural hospital of Central India. *Images in paediatric cardiology*. 2013; 15: 5.
- Groisman, Boris et al. Detection of critical congenital heart disease among newborns in Argentina through the national surveillance system of congenital heart disease (RENAC). *Arch Argent Pediatr*. 2022; 120: 6-13.
- Garg, Lorraine F. et al. Rapid implementation of pulse oximetry newborn screening to detect critical congenital heart defects—New Jersey, 2011. *Morbidity and Mortality Weekly Report*. 2013; 62: 292.
- Taksande, A. et al. An update work of pulse oximetry screening for detecting critical congenital heart disease in the newborn. *Images in paediatric cardiology*. 2017; 19: 12.
- Zarouni, Sumaya Al et al. Impact of an electronic medical record-based automated screening program for critical congenital heart disease: Emirates Health Services, United Arab Emirates. *BMC Medical Informatics and Decision Making*. 2022; 22: 1-7.
- Bhola, Kavita; Kluckow, Martin; Evans, Nick. Post-implementation review of pulse oximetry screening of well newborns in an Australian tertiary maternity hospital. *Journal of paediatrics and child health*. 2014; 50: 920-925.
- Luna, Manuel Sánchez et al. Pulse oximetry screening of critical congenital heart defects in the neonatal period. The Spanish National Neonatal Society recommendation. *Anales de Pediatría (English Edition)*. 2018; 88: 112. e1-112. e6.
- Muñoz, Hernán et al. Diagnóstico y manejo prenatal de patología cardíaca fetal. *Revista Médica Clínica Las Condes*. 2016; 27: 447-475.



- De Sousa Amorim, Maria e cols. A realidade das cardiopatias congênitas no Brasil: revisão bibliográfica A realidade das cardiopatias congênitas no Brasil: revisão bibliográfica. *Revista Brasileira de Revista de Saúde*. 2021; 4:19378-19388.
- Agostini, Marcelo De et al . Utilidad de la ecografía y del eco-doppler color en pacientes de alto riesgo obstétrico. *Rev. Urug. Med. Int., Montevideo*. 2021; 6: 67-71.
- Saliba, Aline et al. Genética e genômica na cardiopatia congênita: uma revisão clinica. *Jornal de Pediatria*. 2020; 96: 279-288.
- Linhares, Isabela Costa et al. Importância do diagnóstico precoce das cardiopatias congênitas: uma revisão integrativa. *Revista Eletrônica Acervo Científico*. 2021; 35: e8621-e8621.
- Bisi, Melissa Claudia. Correlação do doppler espectral articular com atividade inflamatória na artrite reumatóide [tese]. Porto Alegre: Universidade Católica do Rio Grande do Sul; 2016.
- Carvalho, Julene S., L. D. Allan, R. Chaoui, J. A. Copel, G. R. DeVore, K. Hecher, W. Lee et al. ISUOG Practice Guidelines (updated): sonographic screening examination of the fetal heart. *Ultrasound Obstet Gynecol*. 2013; 41: 348–359.
- Dos Santos, Maria Louisy Carvalho et al. Implicações do diagnóstico pré-natal de cardiopatias congênitas na mortalidade fetal: revisão de literatura. *Brazilian Journal of Health Review*. 2022; 5: 2491-2497.
- Mellera, César H. et al. Cardiopatías congénitas, diagnóstico y manejo prenatal. *Arch Argent Pediatr*. 2020; 118:149-61.
- Mendoza, Dy Copado; García, AJ Martínez; Gallegos, S. Acevedo. Importancia del diagnóstico prenatal de las cardiopatías congénitas. *Perinatología y Reproducción Humana*. 2018; 32: 127-130.
- Lim, Tingsen Benson; Foo, Sik Yin Roger; Chen, Ching Kit. The role of epigenetics in congenital heart disease. *Genes*. 2021; 12: 390.
- Luo, Shiyu et al. Análise de Teste Genético e de Desfecho da Gestação de 362 Fetos com Cardiopatia Congênita Identificados por Ultrassom Pré-Natal. *Arquivos Brasileiros de Cardiologia*. 2018; 111: 571-577.
- Aguiar, Cristiane Belas et al. Teste do coraçãozinho: importância da oximetria de pulso em neonatos para detecção precoce de cardiopatias. *Revista Eletrônica Acervo Saúde/Electronic Journal Collection Health ISSN*. 2018; 2178: 1349-1357.
- Zanquetta, Márcia Staff; Da Silva Lopes, Valquiria; De GODOY, Moacir Fernandes. Conhecimento da Oximetria de Pulso na Triagem da Cardiopatia Congênita. *Saúde Coletiva (Barueri)*, v. 10, n. 53, p. 2520-2533, 2020.
- Carvelo, Gabriela Muniz Taham et al. Teste da oximetria de pulso em unidade neonatal de referência-avaliação após 3 anos de sua implantação como teste de triagem universal. *Residência Pediátrica*. 2019; 11: n3-197.



Chamsi-Pasha, Mohammed A.; Chamsi-Pasha, Hassan. Critical congenital heart disease screening. *Avicenna Journal of Medicine*. 2016; 6: 65-68.

Franceschi, Jarbas; Marques, Frederico Manoel; De Souza, Patrícia Alves. Cardiopatias congênitas em um hospital pediátrico. *Research, Society and Development*. 2020; 9: 84.

Hishinuma, Gilberto. Rastreamento de cardiopatias congênitas críticas em recém-nascidos assintomáticos de um hospital de ensino [dissertação]. Maringá: Universidade Estadual de Maringá; 2017.

## ATTACHMENT

Figure 1: Flowchart of the research design.

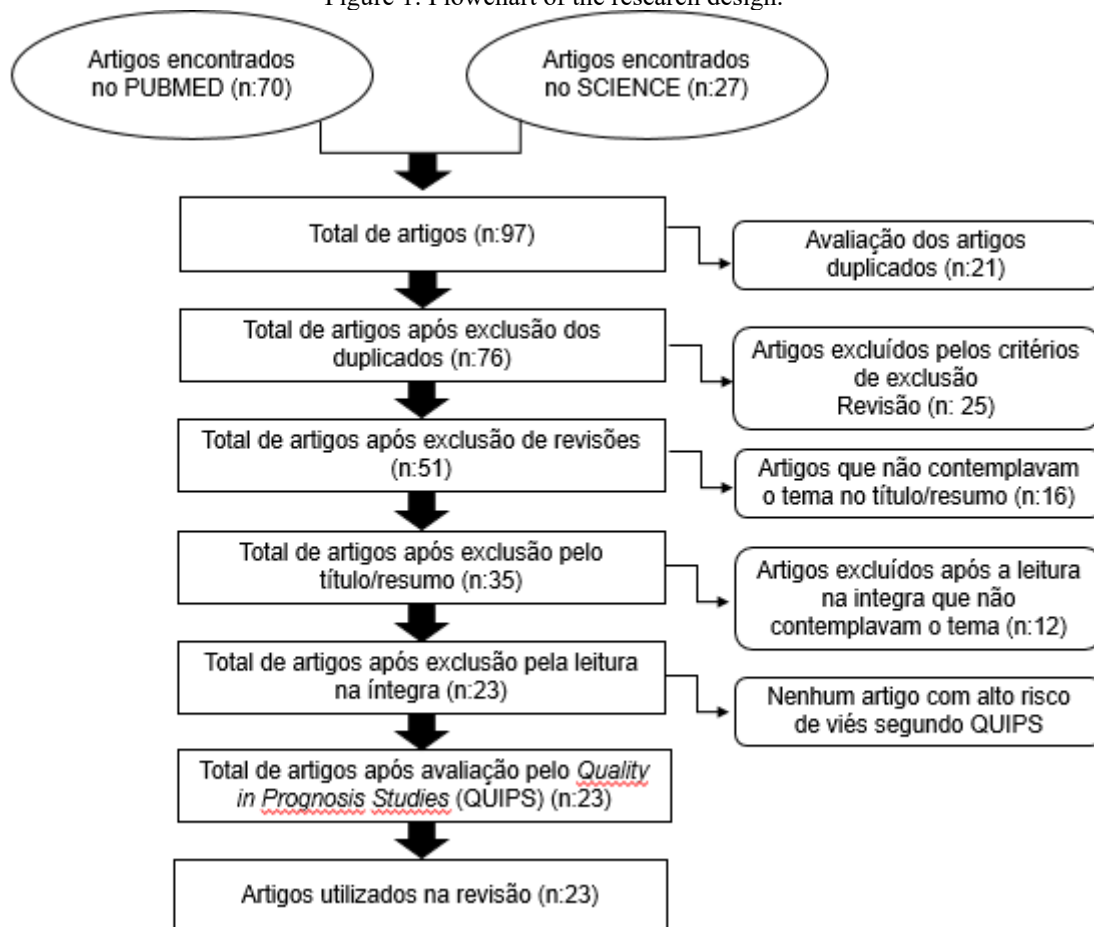


Table 1: Results of the risk of bias assessment of the 23 selected articles (QUIPS tool).

	Participação no estudo	Atrito no estudo	Medida do fator prognóstico	Medição de resultados	Confusão no estudo	Análise estatística e relato	No geral
1	+	+	+	+/-	+	+	+
2	+	+	+	+	+	+	+
3	+	+	+	+	+	+	+
4	+	+	+	+	+	+	+
5	+	+	+	+	+	+	+
6	+	+	+	+	+	+	+
7	+	+	+	+	+	+	+
8	+	+	+	+	+	+	+
9	+	+	+	+	+	+	+
10	+	+	+	+/-	+	+	+
11	+	+	+	+/-	+	+	+
12	+	+/-	+	+	+/-	+/-	+
13	+	+	+	+	+	+	+
14	+	+	+	+	+	+	+
15	+	+	+	+	+	+	+
16	+	+	+	+	+	+	+
17	+	+	+	+	+	+	+
18	+	+	+	+	+	+	+

19	+	+	+	+	+	+	+
20	+	+	+	+	+	+	+
21	+	+	+	+	+	+	+
22	+	+	+	+	+	+	+
23	+	+	+	+	+	+	+

(+) High quality; (+/-) Acceptable; (-) Low quality; (?) Uncertain

Table 2: Main characteristics of the 23 articles used in the systematic review.

	PAÍS DO ESTUDO	POPULAÇÃO	DIAGNÓSTICO PRÉ-NATAL	DIAGNÓSTICO NEONATAL	CONCLUSÃO	REFERÊNCIA
#1	Turquia	180 gestantes	Ecocardiograma fetal.	Com diagnóstico de CC, reavaliar por USG e ecocardiograma.	Importância do diagnóstico no pré-natal para possível interrupção da gestação, cirurgia, encaminhamento precoce.	AYDIN, Emine et al., 2020.
#2	China	1851 neonatos	USG antes das 28 <sup>o</sup> semanas e ecocardiograma fetal.	Exame físico, ausculta, OP e ecocardiograma se suspeita em até sete dias.	Diagnóstico neonatal tardio aumenta fator de risco para óbito.	ZHANG, Wen et al., 2021.
#3	Polônia	484 gestantes	USG fetal e o teste cromossomal Microarray.		Se USG fetal anormal deve-se realizar o teste cromossomal Microarray.	KOWALCZYK, Katarzyna et al., 2021.
Participation in the study	Friction in the study	Prognostic Factor Measurement	Measurement of results	Confusion in the study Ecocardiograma se OP alterada.	Statistical analysis and reporting	Generally
1	+	+	+		+	+
+	2	+		+ Ecocardiograma se OP alterada.	+	+
+	+	3		+	+	+
+	+	+		+	+	+
+	+	+		5	+	+
+	+	+	+	+ Oximetria de pulso.	6	+
+	+	+	+		+	7
+	+	+	+		+	+
8	+	+	+	+ OP entre 48 a 72 horas, se alterada faz o eletrocardiograma e ecocardiograma.	+	+
+	9	+	+	+	+	+
+	+	10	+		+	+/-
+	+	+		+	+	+
+/-	+	+	+	12	+	+/-
+	+	+/-		+	13	+
+	+	+		+	+	14



+	+			+	+	+
15	+	+		+	+	+
+	16	+	+	+	+	+
+	+		+		+	+

Caption: CC, congenital heart disease; TN, nuchal translucency; USG, ultrasonography; OP, pulse oximetry