



Use of tie-in femur osteosynthesis in free-living aracuã scamoso (*ortalis squamata*) with blockage of the femoral and ischiatic nerves

Uso do tie-in em osteossíntese de fêmur em aracuã-escamoso (*ortalis squamata*) de vida livre com bloqueio dos nervos femoral e isquiático

DOI: 10.56238/isevmjv3n2-032

Receipt of originals: 12/04/2024

Publication acceptance: 05/02/2024

Leila Boscato Garcia¹, Lilian Flores Moraes², Ana Paula Morel³, Carolina Depelegrin⁴, Isadora Favreto⁵, Vinícius Ribeiro dos Santos⁶.

ABSTRACT

We report a case of an adult scaly chachaca that arrived for care with a history of being on the ground, in the courtyard of a house, unable to stay in station. On clinical examination, the bird presented immobility in the right femur, with probable comminuted fracture, and it was decided to perform the surgical procedure to correct the fracture. For the treatment, the tie-in technique was used, where a 1.2 mm intramedullary pin was placed in the femur for initial alignment of the bone fragments, while external fixation was performed with three pins of the same thickness as the previous one, two in the cranial region and one in the region distal to the fracture focus. Two months after the date of surgery, an X-ray was performed to verify the formation of bone callus, with satisfactory results. The external fixator was removed on the following day, and seven days after removal, the bird was discharged and released. In addition to the tie-in technique presenting a high success rate with complete return of function, it has the advantage of the fact that its implants are removable, something important when the animal returns to nature, avoiding that, if it dies, these implants do not remain in the environment.

Keywords: Birds, External fixator, Fractures, Galliformis, Rehabilitation.

INTRODUCTION

A bird of the order Galliforme and family Cracidae, the scaly chachachaca (*Ortalis squamata*, Lesson, 1829) is categorized as Least Concern, by the 2019 IUCN Red List of Species, being far from the risk of extinction.

¹ Student of the Biological Sciences course at La Salle University – Unilasalle

E-mail: garcialeilalg@gmail.com

² Student of Veterinary Medicine, Federal University of Pampa – Unipampa

E-mail: lilianfloresmoraes2@gmail.com

³ Veterinarian, Municipal Zoo of Canoas - Mini Zoo

E-mail: apmvet@gmail.com

⁴ Veterinarian, Municipal Zoo of Canoas - Mini Zoo

E-mail: carol.depelegrin@gmail.com

⁵ Veterinarian, Municipal Zoo of Canoas - Mini Zoo

Email: isadoralfavreto@gmail.com

⁶ Veterinarian, self-employed

E-mail: vrsvet1@gmail.com



The most common bird cases in wild animal rehabilitation centers throughout Brazil come from traumatic injuries, usually resulting in various musculoskeletal injuries and fractures, the latter being among the most prevalent causes in the surgical clinic of wild birds (Moreira, 2021). The most affected systems as a result of trauma in birds are osteoarticular, where tibiotarsus, radius, and humeral fractures are the most described, respectively (Ferreira, 2019).

For the correction of fractures, techniques are used that promote the functional union of the bone, without causing damage to the limb or other structures of the body. The choice of appropriate technique in each case should take into account the size of the patient, the presence of simultaneous clinical conditions, the final goal (release or captivity), the surgeon's previous experience, the different fixation techniques, the equipment available by the institution and the temperament of the animal. Possible complications during the treatment of fractures include osteomyelitis, septic arthritis, nonunion or malunion due to instability in the fracture line, prolonged captivity, excessive use of anesthetics, and prolonged immobilization (Helmer; Redig, 2006).

Among the techniques for treating fractures in birds are external coaptation (splints and bandages), external fixation, and internal fixation (intramedullary pins, bone plates, and cerclage wires). Intramedullary pins associated with external fixators (tie-in technique) are currently the most widely used materials for the correction of fractures in birds, and a success rate with complete return of function of more than 65% has been reported. (Redig; Ponder, 2016).

Locoregional anesthesia, through the use of local anesthetics (and also adjuvants) aims to prevent nerve transmission to the central nervous system, leading to motor and sensory blockade, with consequent trans- and post-surgical analgesia (Garcia, 2015). The objective of this study is to report the use of the tie-in technique for the correction of a femoral fracture of free-living *O. squamata* and to evaluate its results and advantages in relation to other existing techniques for the same purpose. In addition to verifying the efficacy of locoregional anesthesia in the same procedure.

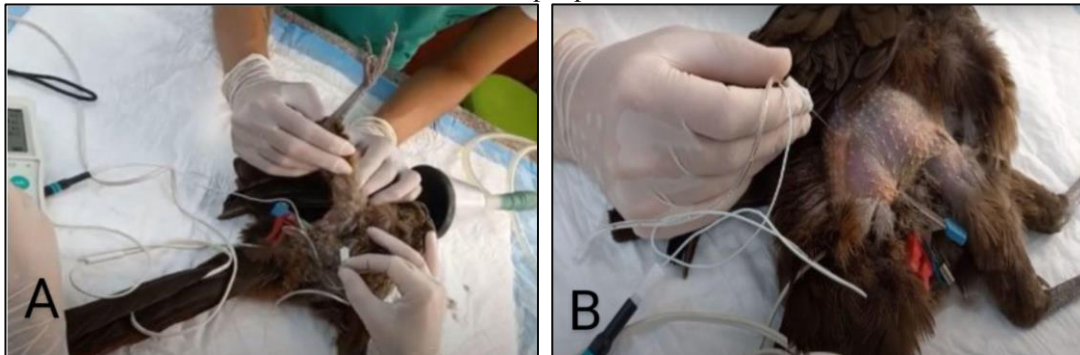
CASE DESCRIPTION

An adult scaly chachachactor (*O. squamata*), sex undefined, arrived for care with a history of being on the ground, in the courtyard of a house, unable to stay in station. On clinical examination, the bird was alert and in good body condition, weighing 360g, with no other noteworthy alterations, except for a crackle in the right femur, with probable comminuted fracture. Because the animal arrived on a weekend at the end of the day, it was not possible to

perform an X-ray immediately. Due to the risk of worsening the fracture, as well as the risk of bone exposure, even with an orthosis, it was decided to perform the surgical procedure for correction on the following day.

For this purpose, morphine 0.5 mg/kg and midazolam 1 mg/kg were used as preanesthetic medication. After 10 minutes, the bird received pre-oxygenation via mask. Induction was performed with 3% isoflurane. Intubation was performed with a 2.0 endotracheal tube without cuff, and anesthesia was maintained with isoflurane vaporized with oxygen at a variable rate of 0.8 to 1.2%. Venous access was performed in the internal saphenous vein with a 24G catheter. For locoregional block, the femoral nerve block was performed by palpating the femoral artery and inserting the neurostimulable needle associated with the peripheral nerve stimulator, cranially to it at 1.0 mhz and 0.2 ms. When there was no response at 0.3 mhz, lidocaine 3 mg/kg was applied. For the sciatic nerve block, the iliac crest and the greater tuberosity of the femur were located, and the needle was inserted between these two points, using the same methodology mentioned above, and then lidocaine 3 mg/kg was applied (Figure 1).

Figure 1: Femoral and sciatic nerve block in squamous aracuã. A. Femoral nerve block with the aid of a peripheral nerve stimulator. B. Sciatic nerve block with the aid of a peripheral nerve stimulator.

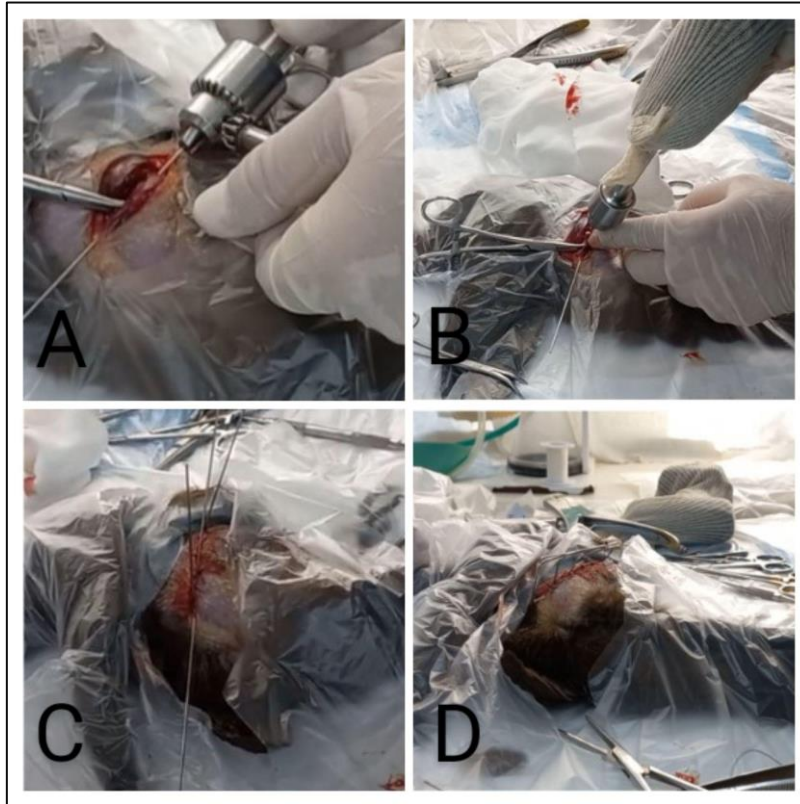


Source: prepared by the author (2023).

The feathers were then removed from the femur region and antisepsis was performed with 2% chlorhexidine. A lateral incision was made to the fractured femur, and it was found that the fracture was complete, in more than one fragment of the femur, with the presence of several squirrels.

For the initial alignment of the bone fragments, a 1.2 mm Kirschner intramedullary pin was placed in the femur. This same pin is bent to be responsible for stabilizing the external fastener. Three transverse pins, of the same thickness as the previous one, were inserted across the cortical bone, two in the cranial region and one in the region distal to the fracture focus (Figure 2).

Figure 2: A. Passage of the 1.2 mm intramedullary pin in the femur. B. Placement of the external fixing pins (1.2mm). C. View of the intramedullary pin and the external fixation pins, two in the cranial position and one in the distal position, appearance before the pins are modeled. D. Tie-in technique being finalized. Modeling of the pins before the application of the self-curing acrylic.



Source: prepared by the author (2023).

The synthesis of the musculature together with the subcutaneous tissue was performed continuously with 3-0 polyglactin thread. Skin synthesis with simple insulated stitches with 3-0 nylon thread. The fixation of the three external pins next to the longitudinal bar of the intramedullary pin was performed with self-curing acrylic resin.

The bird recovered well from anesthesia and was placed in an enclosure with reduced space for the first few days. In the postoperative period, the bird received meloxicam 0.5 mg/kg, once a day, for 5 days, dipyron 25 mg/kg, twice a day, for 15 days, and tramadol 10 mg/kg, twice a day, for 10 days, as antibiotic therapy, a protocol was performed with long-acting oxytetracycline 25 mg/kg, every 72 hours, totaling 3 doses. all intramuscularly.

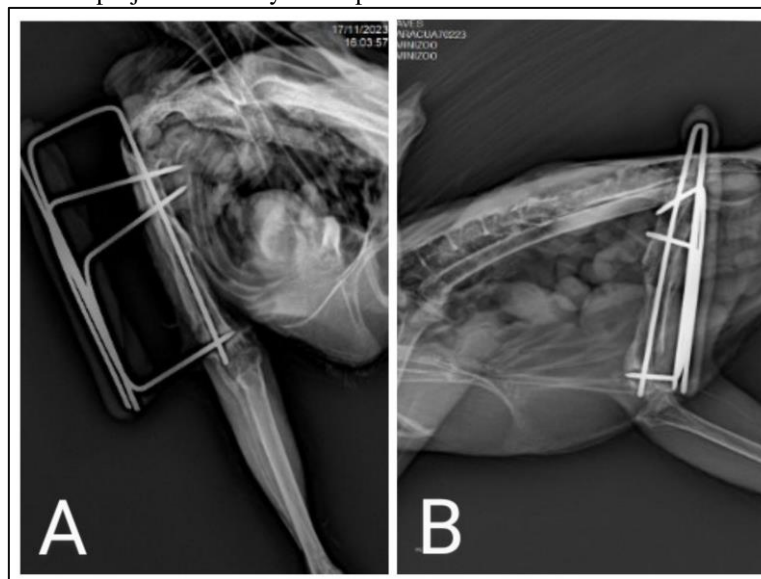
In addition to the drug treatment, movement stimuli were performed twice a day, which consisted of encouraging the animal to get up and move around the enclosure, as well as direct stimulation of the limb, where the bird was suspended to support the affected limb.

An X-ray was performed two days after the procedure to verify the positioning of the pins. Thirty days after the procedure, another X-ray was performed to verify the evolution of the bone callus. There was no evidence of callus formation expected for the duration of surgery, and

it was decided to start oral calcium supplementation at a dose of 25 mg/kg, once a day, for 30 days.

Two months after the date of surgery, another X-ray was performed to verify the formation of a bone callus, this time satisfactory (Figures 3). The external fixator was removed on the following day and during this period the ability to use the limb was evaluated through ambulation and perching. The bird was discharged and released seven days after the removal of the fixator.

Figure 3: A. Radiograph of the right craniocaudal projection 60 days after placement of the external fixator. B. Radiograph: Right mid-lateral projection 60 days after placement of the external fixator



Source: prepared by the author (2023).

DISCUSSION

The tie-in technique is commonly used in medium and large birds because it provides greater solidity to the fracture, its use is possible in the repair of diaphyseal and periarticular fractures of all long bones in birds, with the exception of the tarsometatarsal (Cueva *et al.*, 2020). It has the advantage that its implants are removable, something important when the animal returns to nature, avoiding that, if it dies, these implants remain in the environment. In addition, this technique also has the positive points of reducing intramedullary pin migration, lightness, and the fact that it allows dynamization (Helmer; Redig, 2006). The ease and speed of application, and low invasiveness of the surgical procedure are characteristics that have made the use of a pin as an intramedullary implant or associated with external fixators widespread (Oliveira, 2021).



In 2017, Lucena and collaborators successfully used the same technique on a specimen of shingle-winged hawk (*Parabuteo unicinctus*) with a tibiotarsal fracture. The fact that the technique is less invasive, does not result in bone exposure and consequent injuries to soft tissues, thus favoring the animal's recovery, were considered advantages. In this case, fracture healing occurred 30 days after the procedure. The tie-in configuration was also chosen by Gomes et al. (2022) for the correction of a transverse humeral shaft fracture in a long-eared owl (*Asio clamator*), resulting in complete fracture consolidation and return of limb function 60 days after surgery. Therefore, the fracture healing period was the same as the present report. Due to its low invasiveness, the technique promotes generally fast surgical recovery, with less impact on flight biodynamics compared to more invasive techniques (Jang *et al.*, 2018). Another extremely important factor is that, although properly aligned fractures heal more quickly than in mammals, being stable at 3 to 4 weeks (Cueva, 2020), we must always consider that most birds will be under severe stress after the fracture, both due to trauma and the additional stress of restraint and handling (Bennet, 1995).

It is possible, then, that stress is a factor directly linked to the increase in the healing time of fractures in wild birds, since animals not adapted to captivity may present health and well-being problems, often related to a situation of chronic stress, causing damage to their recovery, due to the non-return to homeostasis. The energy reserves are depleted and the process can evolve from the development of disorders of different natures to the death of the animal (Bondan, 2006). Regarding the anesthetic technique, locoregional blockade with the aid of the peripheral nerve stimulator, the femoral and sciatic nerves, proved to be feasible, based on anatomical points already described in chickens (Silva, 2020; Oliveira, 2021 and also one in peregrine falcon (*Falco peregrinus*) (d'Ovidio, 2015). The isoflurane MAC required for maintenance of general anesthesia was also lower than that described in chickens (Naganobu and Hagio, 2000).

We conclude that the technique used was appropriate for the fracture and for the species. Despite the longer healing time, the result was satisfactory. Minimizing stress management and adequate nutrition favor a more efficient outcome. Anesthetic blockade was also effective, decreasing the rate of overall anesthetic.



REFERENCES

- BENNET, R.; KUZMAN A. Fracture management in birds. *Journal of Zoo and Wildlife Medicine*, v.23, p.5-38, 1992.
- BONDAN, E. F.; ORSINI, H. Fisiopatologia do estresse em animais selvagens em cativeiro e suas implicações no comportamento e bem-estar animal. *Revista do Instituto de Ciências da Saúde*, v.24, n.1, p.7-13, 2006.
- CUEVA, L. O. B; RAHAL, S. C; MESQUITA, L. R; MAMPRIM, M. J; ALVES, A. C. T; KANO, W. T; FILHO, T. G; MATSUBARA, L.M. Considerações sobre fraturas em aves. *Veterinária e Zootecnia, Botucatu*, v. 27, p. 1–11, 2020. Disponível em: <https://rvz.emnuvens.com.br/rvz/article/view/351>. Acesso em: 25 mar. 2024.
- D’OVIDIO, D.; NOVIELLO, E.; ADAMI, C. Nerve stimulator-guided sciatic-femoral nerve block in raptors undergoing surgical treatment of pododermatitis. *Veterinary Anaesthesia and Analgesia*, 42(4), p. 449-453, 2015.
- FERRARI, F. E. Estudo retrospectivo dos atendimentos a animais silvestres de vida livre (2016-2018) no núcleo de conservação e reabilitação de animais silvestres da universidade federal do rio grande do sul. TCC Medicina Veterinária, UFRGS. Porto Alegre, 2019.
- FERREIRA, G.P. Principais alterações radiográficas osteoarticulares em rapinantes atendidos no HOVET/UFRA. Orientador: Leandro Nassar Coutinho. 2019. 27 f. Trabalho de Conclusão de Curso (Graduação em Medicina Veterinária) - Universidade Federal Rural da Amazônia, Campus Belém, PA, 2019.
- GARCIA, E.R. Local Anesthetics. In: GRIMM, K.A.; LAMONT, L.A.; TRANQUILLI, W.J.; GREENE, S.A. ROBERTSON, S.A. *Veterinary Anesthesia and Analgesia*. 5th. Ed. John Wiley & Sons, Inc. p. 332-356. 2015.
- GOMES, A. C. da S.; HONORATO, R. dos A.; BABINSK, T. C. .; FEITOSA, M. L. T.; MOUTA , A. N.; VENUTO, A. M.; ORIENTE, V. N. do; VIANA, G. A.; SOARES, M. J. C.; PAIVA, B. L. Tie-in configuration as a strategy for correction of transverse humerus fracture in striped owl (*Asio clamator*) - Case report. *Research, Society and Development, [S. l.]*, v. 11, n. 8, p. e24111830692, 2022. Disponível em: <https://rsdjournal.org/index.php/rsd/article/view/30692>. Acesso em: 26 mar. 2024.
- HELMER P.; REDIG, P, T. Surgical resolution of orthopedic disorders. Harrison GJ, Lightfoot TL (Ed.) *Clinical Avian Medicine 2*, Palm Beach: Spix Publishing Inc. Publishing; 2006. p.761-74.
- JACOBS, Fernando; FENALTI, Paulo. Guia de identificação: Aves do Rio Grande do Sul. 1.ed. Pelotas: Editora Aratinga, 2020. 454p.
- JANG J; LEE M; PARK Y; KIM M; YUN Y; Surgical Repair of Proximal Humeral Fracture in Common Kestrel (*Falco tinnunculus*). *Journal of Veterinary Clinics*. v. 35, n. 2 p.46–9. 2018. Disponível em: https://www.researchgate.net/publication/325088006_Surgical_Repair_of_Proximal_Humeral_Fracture_in_Common_Kestrel_Falco_tinnunculus. Acesso em: 24 mar. 2024.



- LUCENA, M. F. de; ROCHA, L. L. C. V; SOUZA, A. K. L. de; SANTOS, A. de A. C. dos; MENDES FILHO, L. Osteossíntese de tibiatarso através de configuração tie-in em Gavião Asa-de-telha (*Parabuteo unicinctus*) - Relato de caso. *Ciência Animal*, [S. l.], v. 27, n. 2, p. 50–54, 2023. Disponível em: <https://revistas.uece.br/index.php/cienciaanimal/article/view/11870>. Acesso em: 25 mar. 2024.
- MOREIRA, N. C. Caracterização das Ocorrências Cirúrgicas das Aves Atendidas no CETRAS da Universidade Federal Rural da Amazônia. TCC - Curso de Medicina Veterinária, Campus Universitário de Belém, Universidade Federal Rural Da Amazônia, Belém, 2021.
- NAGANOBU, K.; HAGIO, M. Dose-related cardiovascular effects of isoflurane in chickens during controlled ventilation. *The Journal of Veterinary Medical Science*, 62(4): p. 435–437, 2000.
- OLIVEIRA, S.P. Bloqueio dos nervos femoral e isquiático com auxílio de neuroestimulação em galinhas (*Gallus gallus domesticus*). Dissertação. Mestrado em Ciência Animal. Faculdade de Medicina Veterinária de Araçatuba da Universidade Estadual Paulista. 58p, 2021.
- REDIG, P. T.; Ponder J. Orthopedic surgery. Samour J (Ed.) *Avian Medicine*, 3a Ed, Elsevier, p. 312-358, 2016.