




## SURGICAL TREATMENT OF MAXILLARY FRACTURES: APPROACHES BASED ON LE FORT CLASSIFICATIONS AND THEIR CLINICAL IMPLICATIONS

 <https://doi.org/10.56238/isevmjv4n2-001>

Receipt of originals: 02/04/2025

Acceptance for publication: 03/04/2025

**Maria Josilaine das Neves de Carvalho<sup>1</sup>, Bruna Beatriz Freitas Ferreira da Silva<sup>2</sup>, Bruna Raquel Barbosa Olinto<sup>3</sup>, Cleyslla Rebeca de Oliveira Matos<sup>4</sup>, José Luciano Brainer de Farias Filho<sup>5</sup>, Marcos Vinicius Soares Teixeira de Lima<sup>6</sup>, Mayra Eduarda Conceição Lima<sup>7</sup> and Priscila dos Santos Silva<sup>8</sup>**

### ABSTRACT

Maxillary fractures are complex injuries with great functional and aesthetic impact, often caused by high-energy traumas, such as traffic accidents and assaults. The surgical treatment of these fractures has evolved considerably over time, with the advancement of rigid internal fixation techniques, which offer greater precision and lower morbidity compared to conventional methods. The Le Fort classification, proposed in 1901, remains a crucial tool for the diagnosis and surgical planning of these fractures, dividing them into three distinct types, which require different approaches. Le Fort I involves horizontal fractures, while Le Fort II and III are more complex, affecting the maxilla, nasal bones, and orbital structures. Early treatment with open reduction and rigid fixation has shown better clinical results, with a lower risk of long-term complications. In addition, the use of advanced technologies, such as CT scans and 3D models, has improved the planning and execution of surgeries, contributing to the faster and more efficient recovery of patients. This article reviews surgical approaches based on Le Fort's classifications, discussing their clinical implications in the management of maxillary fractures.

**Keywords:** Maxillary fractures. Le Fort. Surgical Treatment. Rigid Fixation. 3D technology.

---

<sup>1</sup> Undergraduate student in Dentistry Centro Universitário UNINASSAU - Caruaru  
ORCID: <https://orcid.org/0009-0003-0718-2046>

<sup>2</sup> Undergraduate student in Dentistry Centro Universitário UNINASSAU - Caruaru

<sup>3</sup> Undergraduate student in Dentistry Centro Universitário UNINASSAU - Caruaru

<sup>4</sup> Undergraduate student in Dentistry UNINASSAU University Center – Caruaru

<sup>5</sup> Undergraduate student in Dentistry UNINASSAU University Center - Caruaru

<sup>6</sup> Undergraduate student in Dentistry UNINASSAU University Center – Caruaru

<sup>7</sup> Undergraduate student in Dentistry UNINASSAU University Center – Caruaru

<sup>8</sup> Undergraduate student in Dentistry UNINASSAU University Center – Caruaru



## INTRODUCTION

Maxillary fractures represent one of the most challenging forms of facial trauma, often associated with high-energy episodes such as traffic accidents, falls from heights, and physical assaults. These fractures are considered not only for their aesthetic implications, but also for their effects on essential functions such as chewing, breathing, and speech, which can be compromised depending on the severity of the injury. According to Bagheri et al. (2013), the impact of these fractures on the patient goes beyond the physical aspect, affecting their quality of life, psychological well-being, and even their social skills, since changes in facial appearance can lead to stigma and emotional difficulties.

In the context of oral and maxillofacial surgery, the treatment of maxillary fractures has evolved considerably over time, particularly with the advent of new technologies and surgical techniques. In the past, the management of these lesions was predominantly conservative, with the use of closed reduction and maxillomandibular fixation methods, which, although effective, were often associated with high rates of complications, such as infection, tooth loss, and temporomandibular disorder (Haug et al., 1995). However, the development of rigid internal fixation techniques has revolutionized the treatment of maxillary fractures, allowing more precise control of bone position and promoting faster recovery with fewer sequelae. The use of plates and screws to stabilize bone fragments represents an important advance, providing not only greater patient safety but also more satisfactory aesthetic results (Haug et al., 1992).

In addition to technical innovations, the classification of maxillary fractures plays a fundamental role in treatment planning, since different types of fractures require different approaches. The Le Fort classification, proposed by René Le Fort in 1901, is still widely used to categorize fractures of the middle third of the face. This classification, although relatively simple, has profound clinical implications, as it divides maxillary fractures into three distinct types, each with specific characteristics of bone involvement and with different implications for reconstruction. Le Fort I, for example, describes a horizontal fracture that involves only the maxilla and palate, while Le Fort II and III, more complex, involve fractures that affect the maxilla, nasal bones, and orbital structures, requiring more extensive surgical approaches (Le Fort, 1901; O'Donovan C Antonyshyn, 2004).

Contemporary studies have shown that the early surgical approach to maxillary fractures, with open reduction and rigid fixation, is associated with lower rates of



complications, such as facial deformities, occlusal dysfunctions, and limitations in physiological functions (Manson et al., 1985). In particular, early surgery is essential to prevent the occurrence of bone atrophy and unwanted scarring, factors that can compromise facial aesthetics and masticatory function (Markowitz C Manson, 1989). Early surgery also facilitates bone reconstruction, especially in cases of complex fractures, which may require bone grafts to ensure the structural integrity of the face (Peterson et al., 2000). Thus, surgical treatment, in addition to promoting functional rehabilitation, must consider aesthetic and emotional aspects, especially in complex fractures, where the re-establishment of facial symmetry and the preservation of basic functions are crucial.

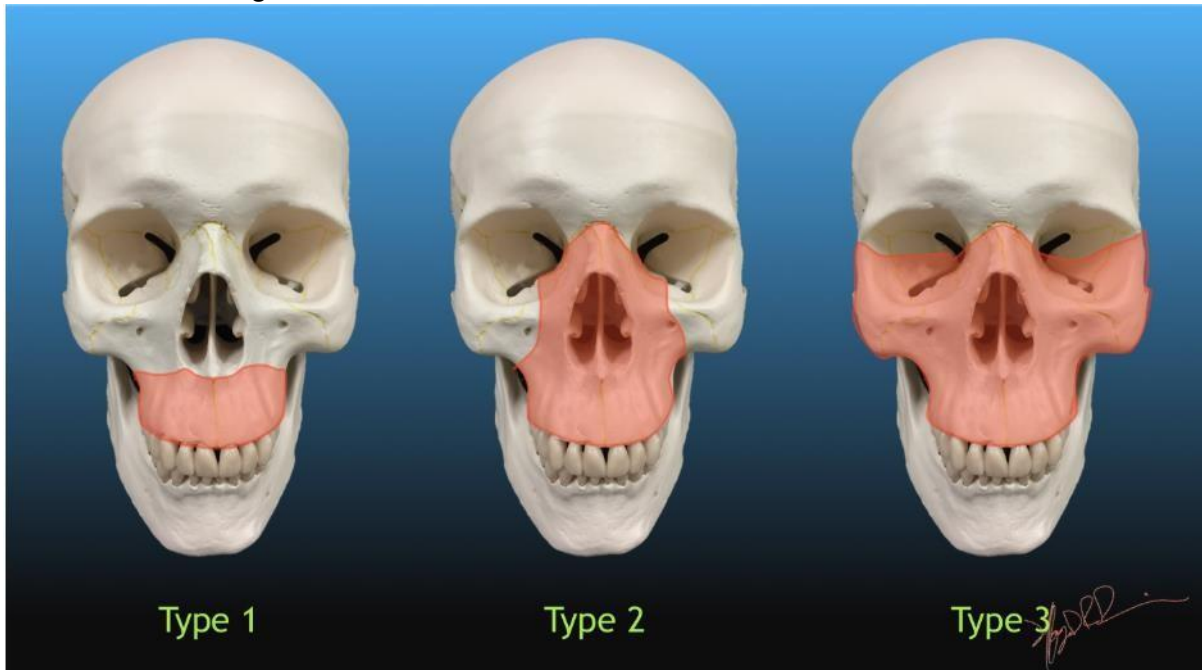
The implications of Le Fort's classifications on the clinical management of these fractures are vast. The choice of the type of intervention depends on the severity of the fracture and the involvement of adjacent structures, such as the eye socket, nose, and skull base. In addition, the surgical approach is not limited to maxillary repair but should include the evaluation of other associated injuries, which may complicate the patient's clinical picture, such as mandibular fractures, brain injuries, or vascular impairment (Mendonça et al., 2011). In this sense, collaboration between different specialties, such as craniofacial surgery, neurosurgery, and otorhinolaryngology, may be necessary for comprehensive and effective treatment.

Recent studies also highlight the importance of technology in the management of maxillary fractures, with the use of three-dimensional imaging and computed tomography for preoperative planning (Reiter et al., 2017). These technologies allow for a more accurate visualization of fractures and the anatomical structures involved, which facilitates decision-making and the execution of less invasive and more effective surgical interventions. The use of 3D models for surgery simulation and personalized planning has also been an increasingly employed strategy, providing greater control over postoperative aesthetic and functional results.

Therefore, this article aims not only to review the most effective surgical approaches for the treatment of maxillary fractures but also to discuss the clinical implications of Le Fort classifications in the planning and execution of surgeries. In addition, the evolution of surgical techniques will be addressed, with an emphasis on minimally invasive interventions and new technologies, to offer a comprehensive and updated view of the management of maxillary fractures. Integrating clinical evidence

and innovative therapeutic approaches is expected to contribute to the improvement of outcomes in the treatment of these complex fractures, promoting a faster and less traumatic recovery for patients (Sastry et al., 1995; Tugaineyo et al., 2010).

**Image 1:** Illustration of the Le Fort Classification of facial fractures.



**Source:** University of Washington. LeFort Classification of Facial Fractures. UW Emergency Radiology. Available at: <https://faculty.washington.edu/jeff8rob/trauma-radiology-reference-resource/2-hn/lefort-classification-of-facial-fractures/>.

## METHODOLOGY

Given what was presented, this research follows the classification of Gil (2008), characterized as basic, exploratory research, with a qualitative approach and bibliographic nature. This is an integrative literature review that aims to consolidate and critically analyze the available evidence on the surgical treatment of maxillary fractures, with emphasis on approaches based on Le Fort's classifications and their clinical implications.

The search for the material was carried out through books and the following electronic sources: Portal de Periódicos da Coordenação de Aperfeiçoamento de Pessoal de Nível Superior (CAPES), Brazilian Digital Library of Theses and Dissertations (BDTD), PubMed, Scientific Electronic Library Online (SCIELO).

For this purpose, the following search strategy was used with specific terms: "Maxillary fractures", "Le Fort classification", "Surgical treatment", "Surgical approaches" and "Clinical implications".



The strategy allowed the identification and selection of studies that address the various surgical techniques applied in the management of maxillary fractures, as well as the clinical outcomes and therapeutic implications associated with the application of the Le Fort classifications (Bagheri et al., 2013; Erdmann et al., 2008; Haug et al., 1992, 1995; Le Fort, 1901).

The analysis of the selected studies made it possible to identify trends, advances, and gaps in the literature, contributing to the theoretical foundation and the improvement of clinical practices in the treatment of these fractures.

## RESULTS

The search and selection strategy of the studies resulted in the initial identification of 200 publications related to the surgical treatment of maxillary fractures, focusing on approaches based on the Le Fort classification and its clinical implications. After the removal of 40 duplicates, 160 titles and abstracts were evaluated. Of these, 120 articles were excluded because they did not meet the established inclusion criteria, leaving 40 studies for full reading. Based on the detailed evaluation of the content, 12 studies were selected to compose the final analysis of this integrative review.

The selected studies encompass a variety of methodological designs, including retrospective analyses, comparative studies, and case reports, which range from the anatomical and clinical aspects of maxillary fractures (Le Fort, 1901) to modern techniques of rigid fixation and surgical rehabilitation (Bagheri et al., 2013; Haug et al., 1995). In general, the results indicate that surgical approaches that use open reduction associated with rigid fixation have provided better clinical outcomes, presenting lower morbidity and significant improvement in aesthetic and functional outcomes. In addition, the use of advanced imaging technologies, such as computed tomography and 3D modeling, has contributed to more accurate preoperative planning, increasing the safety and effectiveness of surgical procedures.

The following is a summary of the main studies included in the review:

**Table 1 – Characteristics of the Selected Studies**

Reference s CIA	Type of Study	Objective/Approach	Key Findings
Bagheri et al. (2013)	Book/Monograph	Review of therapies in oral and maxillofacial surgery	Describes modern fixation and rehabilitation techniques that enhance functional recovery and aesthetics.
Erdman N et al. (2008)	Analysis Retrospectiva	Analyze etiologies and facial fracture patterns	It highlights the mechanisms of trauma and its clinical implications in the surgical approach.
Haug et al. (1995)	Comparative study	Compare maxillomandibular fixation with rigid fixation Internal	It demonstrates that rigid fixation results in lower morbidity and better post-fixation outcomes. Operative.
Haug et al. (1992)	Retrospect study Ivo	Evaluate closed reduction in fractures Jaws	Associates the closed technique with greater complications and morbidity.
Le Fort (1901)	Experimental study such	The proposition of the classification of maxillary fractures	It lays the groundwork for classification into three types Fundamental.
Manson et al. (1985)	Clinical study	Evaluate immediate surgical intervention with bone grafting	Evidence that immediate open reduction improves outcomes aesthetic and functional.
Markowitz C Manson (1989)	Review/Clinical Argument	Organization of treatment in pan facial fractures	It emphasizes the importance of an integrated approach to therapeutic success.
Reiter et al. (2017)	Post-image review Operative	Evaluate postoperative complications using tomography	It highlights the usefulness of tomography for early identification of complications.
Mendonça et al. (2011)	Case report	To describe the management of complex fractures of the middle third of the face	It presents favorable results with personalized approaches in complex cases.



## DISCUSSION

The surgical treatment of maxillary fractures, especially those classified according to the Le Fort system, continues to be one of the most complex challenges in the practice of oral and maxillofacial surgery. The classification proposed by Le Fort (1901) remains fundamental, allowing a systematization of the different fracture patterns and helping to define specific therapeutic approaches. This approach is especially relevant in high-energy trauma, in which the accuracy of the diagnosis and the preoperative planning determine the success of the treatment.

In the case of Le Fort I fractures, which involve horizontal separation of the maxilla, the literature shows that open reduction associated with rigid fixation is the preferred approach. Studies by Haug et al. (1992) demonstrate that this technique facilitates the anatomical replacement of bone fragments, promoting the restoration of occlusion and facial symmetry, in addition to reducing postoperative morbidity compared to closed reduction methods. This effectiveness is due to the ability of rigid fixation to provide stability during the healing process, minimizing the risk of dislocations and future complications.

Fractures classified as Le Fort II and III, which involve additional facial structures such as the orbit and skull base, require a multidisciplinary and more comprehensive approach. In such cases, immediate surgical intervention, often combined with bone grafts, has demonstrated superior results in aesthetic and functional rehabilitation. Studies by Manson et al. (1985) and Markowitz & Manson (1989) emphasize that early open reduction is crucial to prevent deformities and ensure the integrity of facial contours, in addition to reducing secondary complications resulting from the complexity of trauma.

The integration of advanced technologies, such as computed tomography and three-dimensional modeling, has transformed the planning and execution of surgical procedures. These tools allow for a detailed assessment of the patient's anatomy and fracture patterns, offering an accurate visualization that facilitates surgical strategy. Reiter et al. (2017) highlight the importance of these technologies in the early identification of postoperative complications, enabling immediate corrective interventions. Thus, the combined use of traditional techniques with digital innovations enhances the effectiveness of treatments, contributing to the safety and personalization of procedures.



However, the analysis of the studies reveals methodological limitations that make it difficult to directly compare surgical approaches. Most of the studies reviewed are retrospective or based on case reports, which restricts the robustness of the data and the generalizability of the results. This gap highlights the need for prospective studies and randomized controlled trials that can provide more consistent and standardized evidence on fixation techniques and clinical outcomes associated with maxillary fractures.

In summary, the findings of this integrative review reinforce the relevance of the Le Fort classification as an indispensable guide for the management of maxillary fractures. Evidence suggests that the approach based on open reduction, rigid fixation, and support of advanced technologies not only improves clinical outcomes but also minimizes complications, promoting a more efficient and satisfactory recovery for patients. To consolidate these advances, future research must adopt more robust methodologies, contributing to the continuous evolution of surgical protocols and the improvement of the quality of life of individuals affected by such traumas.

## **CONCLUSION**

The treatment of maxillary fractures, especially those classified by the Le Fort system, requires a careful and personalized approach, considering the anatomical complexity of the region and the particularities of each patient. The Le Fort classification remains an essential tool for diagnosis and therapeutic planning, allowing the precise identification of the fracture pattern and the choice of the most appropriate surgical technique.

The available evidence indicates that open reduction associated with rigid fixation provides superior results in terms of bone stability, restoration of occlusion, and minimization of postoperative complications. In addition, the integration of advanced technologies, such as CT scans and three-dimensional modeling, has improved surgical planning, allowing for a more precise and personalized approach.

However, it is essential to recognize the methodological limitations of existing studies, which are often retrospective or are based on isolated case reports. Prospective studies and randomized clinical trials are essential to consolidate the best practices in the treatment of maxillary fractures and for the continuous evolution of therapeutic protocols.



In summary, the combination of a detailed clinical evaluation, the judicious use of Le Fort's classifications, the application of appropriate surgical techniques, and the support of advanced technologies are fundamental for success in the treatment of maxillary fractures, always aiming at the patient's functional and aesthetic recovery.



## REFERENCES

1. BAGHERI, S. C.; BELL, R. B.; KHAN, H. A. Current therapies in oral and maxillofacial surgery. Rio de Janeiro: Elsevier, 2013.
2. ERDMANN, D.; FOLLMAR, K. E.; DEBRUIJN, M., et al. A retrospective analysis of facial fracture etiologies. *Ann Plast Surg.* 2008, 60(4):398-403.
3. HAUG, R. H.; ADAMS, J. M.; JORDAN, R. B. Comparison of the morbidity associated with maxillary fractures treated by maxillomandibular and rigid internal fixation. *Oral Surg Oral Med Oral Pathol Oral Radiol Endod.* 1995, 80(6):629-37.
4. HAUG, R. H.; PRATHER, J.; BRADRICK, J. P.; INDRESANO, A. T. The morbidity associated with fifty maxillary fractures treated by closed reduction. *Oral Surg Oral Med Oral Pathol.* 1992, 73(6):659-63.
5. KÜHNEL, T. S.; REICHERT, T. E. Trauma of the midface. *GMS Current Topics in Otorhinolaryngology-Head and Neck Surgery* 2015, 14:1-45.
6. LE FORT, R. Etude expérimentale sur les fractures de la mâchoire inférieure. I, II, III. *Rev Chir Paris.* 1901, 23:208.
7. MANSON, P. N.; CRAWLEY, W. A.; YAREMCHUK, M.; RICHMAN, G. M.; HOOPEES, J. E.; FRENCH, J. H. Jr. Midface fractures: advantages of immediate extended open reduction and bone grafting. *Plast Reconstr Surg.* 1985, 76(1):1-12.
8. MARKOWITZ, B. L.; MANSON, P. N. Panfacial fractures: organization of treatment. *Clin Plast Surg.* 1989, 16(1):105-14.
9. MILORO, M.; GHALI, G. E.; LARSEN, P. E.; WAITE, P. D. Peterson's Principles of Oral and Maxillofacial Surgery. 2nd ed. BC Decker Inc, New York, 2004.
10. O'DONOVAN, D. A.; ANTONYSHYN, O. M. Maxillary fractures. In: THALLER, S. R.; McDONALD, W. S., eds. *Facial trauma.* New York: Marcel Decker; 2004. p. 331-60.
11. PETERSON, J. L.; ELLIS, III, E.; HUPP, J. R.; TUCKER, M. R. Contemporary Oral and Maxillofacial Surgery. 3rd ed. Guanabara Koogan, Rio de Janeiro, 2000.
12. PHILLIPS, J. H.; GRUSS, J. S.; WELLS, M. D.; CHOLLET, A. Periosteal suspension of the lower eyelid and cheek following subsidiary exposure of facial fractures. *Plast Reconstr Surg.* 1991, 88(1):145-8.
13. SASTRY, S. M.; SASTRY, C. M.; PAUL, B. K.; BAIN, L.; CHAMPION, H. R. Leading causes of facial trauma in the major trauma outcome study. *Plast Reconstr Surg.* 1995, 95(1):196-7.
14. TUGAINEYO, E. I.; ODHIAMBO, W. A.; AKAMA, M. K.; GUTHUA, S. W.; DIMBA, E. A. O. The etiology, pattern, and management of oral and maxillofacial injuries at Mulago National Referral Hospital. *East African Medical Journal* 2010, 89(11):351-



358.

15. REITER, M. J.; SCHWOPE, R. B.; THELER, J. M. Postoperative CT of the midfacial skeleton after trauma: review of normal appearances and common complications. *AJR* 2017, 209: W1–W11.
16. MENDONÇA, J. C. G.; FREITAS, G. P.; LEE; NASCIMENTO, V. S. Treatment of complex fractures of the middle third of the face: case report. *Rev Bras Cir Craniomaxillofac.* 2011, 14(4):221-4.