

Pulp revascularization: A systematized literature review

Heloisa Guimarães Resende¹
Bianca Vieira Ramos²
Daniel De Melo D'Oliveira³
Martinelle Ferreira da Rocha Taranto⁴
Raquel Auxiliadora Borges⁵
Isabel Cristina Ribeiro Madalena⁶
César Penazzo Lepri⁷
Jader Pinto⁸
Profa. Dra. Isabela Ribeiro Madalena⁹



10.56238/rcsv14n2-011

¹ Dental Surgeon, Specialist in Endodontics, Master's student in Dentistry

Orcid id: <https://orcid.org/0009-0007-0397-597X>

Email: heloisag.resende@gmail.com

² Dental Surgeon

School of Dentistry, Presidente Tancredo de Almeida Neves University Center, São João del Rei, Minas Gerais, Brazil.

Orcid id: <https://orcid.org/0009-0008-5786-6100>

Email: vrbianca@hotmail.com

³ Dental surgeon

School of Dentistry, Presidente Tancredo de Almeida Neves University Center, São João del Rei, Minas Gerais, Brazil.

Orcid id: <https://orcid.org/0009-0003-0681-1859>

Email: dolnepessoal@gmail.com

⁴ Biologist and Master in Biotechnology

School of Dentistry, Presidente Tancredo de Almeida Neves University Center, São João del Rei, Minas Gerais, Brazil.

Orcid id: <https://orcid.org/0000-0001-5556-4506>

Email: martinelle.taranto@uniptan.edu.br

⁵ Pedagogue and Master in Education

School of Dentistry, Presidente Tancredo de Almeida Neves University Center, São João del Rei, Minas Gerais, Brazil.

Orcid id: <https://orcid.org/0009-0006-1486-2164>

Email: raquel.borges@uniptan.edu.br

⁶ Dental Surgeon, Specialist in Endodontics

Dental surgeon in private practice

Orcid id: <https://orcid.org/0009-0002-4345-4726>

Email: isabelmadalena@icloud.com

⁷ Dental Surgeon, Master and Doctor of Science

Department of Biomaterials, University of Uberaba, Uberaba, MG, Brazil.

Orcid id: <https://orcid.org/0000-0003-4372-9718>

Email: cesarlepri@yahoo.com.br

⁸ Dental Surgeon, Master and Doctor in Dentistry

School of Dentistry, Presidente Tancredo de Almeida Neves University Center, São João del Rei, Minas Gerais, Brazil.

Orcid id: <https://orcid.org/0000-0003-2023-1589>

Email: jader.pinto@uniptan.edu.br

⁹ Dental Surgeon, Master and Doctor of Science

Department of Biomaterials, University of Uberaba, Uberaba, MG, Brazil.

Faculty of Dentistry, Presidente Tancredo de Almeida Neves University Center,

Orcid id: <https://orcid.org/0000-0002-4486-1318>

Email: isabelarmadalena@hotmail.com

ABSTRACT

Pulp revascularization has the advantage, in addition to the induction of rhizogenesis, of a vital tooth at the end of the treatment. Thus, the objective of the present study was to perform a systematic review of the literature on pulp revascularization therapy in non-vital permanent teeth. The present review used the recommendations of the PRISMA statement and PICOS parameters. Only experimental studies from the last 10 years in English were included, with an abstract available. Manuscripts that were not in accordance with the objectives proposed for this research were excluded. The focus question was: Does pulp revascularization therapy in permanent teeth present promising results? The search was performed in the PubMed database. MeSH (Medical Subject Headings) and free terms were included in the following provision: (dental pulp necrosis[MeSH Terms]) OR (Tooth nonvital[MeSH Terms]) OR (Dentition, Permanent[MeSH Terms]) OR ("dental pulp necrosis") OR ("Tooth nonvital") OR ("Dentition, Permanent") OR ("immature permanent teeth") OR ("immature Teeth") AND (("Pulp revascularization") OR ("pulp Vascularization")). The included studies were compiled and organized according to their characteristics. The results demonstrate that pulp revascularization in permanent teeth is mainly dependent on the rhizogenesis stage, chemical-mechanical operative management, and the use of biocompatible materials. In conclusion, pulp revascularization, although little evidenced in the correlated and specific literature, demonstrates promising clinical and radiographic results in relation to endodontic rehabilitation.

Keywords: Dental Pulp Necrosis, Non-Vital Tooth, Dentition, Permanent.

1 INTRODUCTION

Dental caries and dental trauma are very common injuries to the oral cavity (Petti et al., 2018; Kazeminia et al., 2020). In the child and adolescent population in particular, a systematic review with meta-analysis was able to state that the prevalence of dental caries in permanent teeth, with a global sample of 1,454,871 children, was 53.8% (95% CI: 50-57.5%) (Kazeminia et al., 2020). Regarding dental trauma, it is estimated that the global prevalence results in more than 15% of the young population and 22% of the child population (Petti et al., 2018). It is worth noting that in both situations, dental caries disease and dental trauma, irreversible injuries to pulp and periapical tissues may be imminent (Ricucci et al., 2017; Bratteberg et al., 2020). In these cases, endodontic therapy of the root canal system is cited as the gold standard therapy (AAE, 2013; Arslan et al., 2019); However, as a disadvantage of the technique, it can be mentioned that the therapy is not able to restore the vitality of the damaged pulp.

The dental pulp, in turn, consists primarily of loose connective tissue with a variety of specialized cells, such as odontoblasts, fibroblasts, endothelial cells, nerve cells, immune cells, and stem/progenitor cells (Yu; Abbott, 2007; Piva et al., 2017; Xie et al., 2021). This complex of cells makes the dental pulp a unique organ, responsible for performing several local functions in addition to contributing to the harmonious development of the stomatognathic system (Yu; Abbott, 2007). The loss of pulp vitality and consequent endodontic treatment significantly reduce dentin resistance (Soares et al., 2018; Rodrigues et al., 2020; Mannocci et al., 2022). In cases of immature teeth – incomplete

rhizogenesis – in addition to reduced resistance, interruption of odontogenesis and imbalance in the harmonic development of the stomatognathic system, fragile root walls, due to the thin thickness of the dentin of the root canal and amplitude of the open apex, make endodontic therapy even more complex (Gupta et al., 2020).

For many years, the protocol for limiting damage to non-vital and immature teeth in relation to odontogenesis and development of the stomatognathic system described by the endodontic treatment technique associated with strategies that induce appicification - root formation has been highlighted for many years (AAE, 2013). However, in view of contemporary knowledge of the rich pulp, apical papilla, and periodontal ligament composition of teeth with incomplete rhizogenesis, pulp revascularization therapy has been proposed (Ding et al., 2009; Nagata et al., 2014; Aly et al., 2019; Arslan et al., 2019). Pulp revascularization has the advantage, in addition to inducing rhizogenesis, of a vital tooth at the end of treatment (Ding et al., 2009; Aly et al., 2019; Arslan et al., 2019). However, to date, other scientific evidence is still needed for the concrete establishment of protocols (Galler et al., 2016; Silva et al., 2023). Thus, the objective of the present study was to perform a systematic review of the literature on pulp revascularization therapy in non-vital permanent teeth.

2 MATERIALS AND METHODS

Protocol, eligibility criteria, and focused question

The inclusion criteria followed the recommendations of the PRISMA statement (Page et al., 2021), following the PICO parameters, as follows:

P - Population: non-vital permanent teeth with incomplete rhizogenesis;

I – Intervention: pulp revascularization therapy;

C - Comparison: endodontic therapy associated with strategies that induce apicification; O -

Result: superiority of pulp revascularization therapy in relation to endodontic therapy associated with strategies that induce apicification.

Only experimental studies from the last 10 years in English were included, with an abstract available. Manuscripts that were not in accordance with the objectives proposed for this research were excluded.

The focus question was: Does pulp revascularization therapy in non-vital permanent teeth present promising results?

2.1 SOURCES OF INFORMATION

An extensive search was carried out until October 7, 2023, in the following databases: MEDLINE (PubMed).

2.2 SEARCH STRATEGY

Foram incluídos termos MeSH (Medical Subject Headings) (<https://www.ncbi.nlm.nih.gov/pubmed>) e termos livres na seguinte disposição: (dental pulp necrosis[MeSH Terms]) OR (Tooth nonvital[MeSH Terms]) OR (Dentition, Permanent[MeSH Terms]) OR ("dental pulp necrosis") OR ("Tooth nonvital") OR ("Dentition, Permanent") OR ("immature permanent teeth") OR ("immature Teeth") AND (("Pulp revascularization") OR ("pulp Vascularization")).

2.3 SOURCES OF EVIDENCE, DATA MAPPING PROCESS, DATA ITEMS

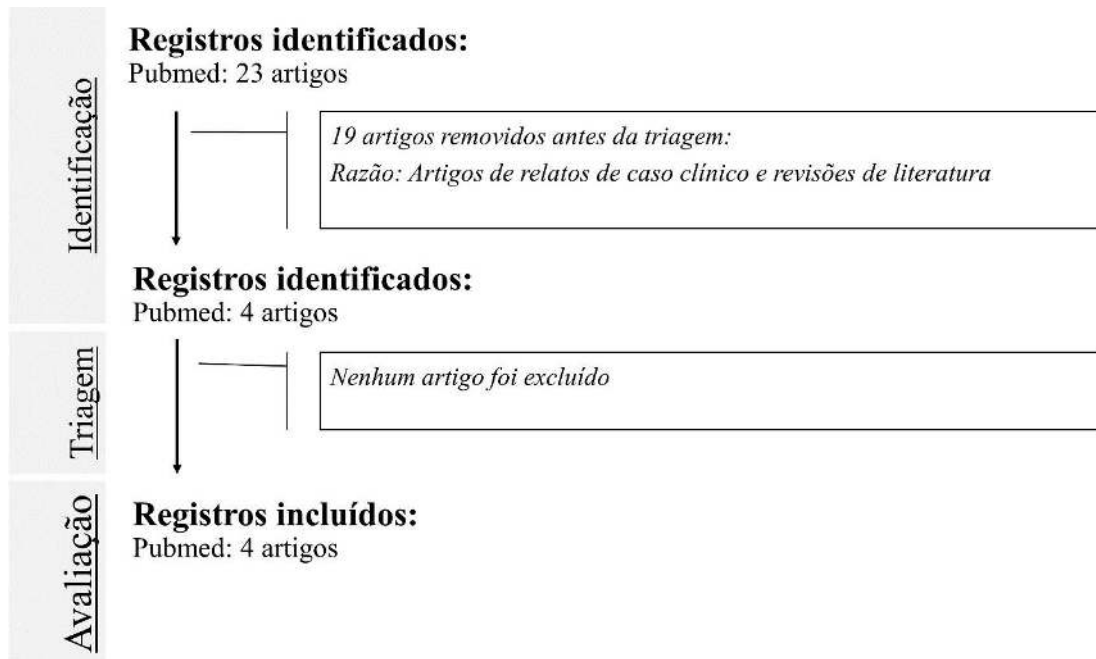
Before starting screening for this review, a data mapping form was developed together to determine which variables to extract. The reviewer mapped the data, discussed the results, and continuously updated the data mapping form in an interactive process. All of these processes were subsequently reviewed by an experienced examiner.

The data from the included studies were compiled and organized according to the characteristics of the study.

3 RESULTS

The initial search strategy retrieved a total of 4 experimental papers over 10 years. The flowchart of recovered, included, and excluded articles is summarized in Figure 1. Table 1 shows the characteristics of the articles included. The results demonstrate that pulp revascularization in non-vital permanent teeth is mainly dependent on the rhizogenesis stage, chemical-mechanical operative management, and the use of biocompatible materials.

Figure 1. Flowchart proposed for this systematized revision.



Source: The authors.

Table 1. Features of the items included.

Author/year	Objective	Sample	Materials used	Key results/follow-up	Conclusion
Ding <i>et al.</i> (2009)	To examine the effect of a pulp revascularization procedure on immature necrotic teeth with apical periodontitis	12 patients	<ul style="list-style-type: none"> • Irrigation with sodium hypochlorite 5.25% • EDTA 5% • Indwelling dressing: Triple antibiotic paste (minocycline, metronidazole, and ciprofloxacin) in 1/3 medium and apical – 1 week • Sealing: Added ash mineral trioxide (MTA) 	Three teeth showed complete root development and positive response to the pulp test	Revascularization can be effective in the management of immature permanent teeth with apical periodontitis with appropriate case selection.
Nagata <i>et al.</i> (2014)	To evaluate traumatized immature teeth treated with two pulp revascularization protocols.	<ul style="list-style-type: none"> • 23 teeth • Patients 7 to 17 years old 	<ul style="list-style-type: none"> • Irrigation with sodium hypochlorite 6% • EDTA 17% • Delay curative: Triple antibiotic paste (minocycline, metronidazole and ciprofloxacin) or calcium hydroxide com chlorhexidine gel 2% – 3 weeks • Sealing: Added ash mineral trioxide (MTA) 	<ul style="list-style-type: none"> • The group submitted to medication with triple paste showed a significant reduction in spontaneous pain, pain on horizontal percussion and palpation, while the group submitted to calcium hydroxide and chlorhexidine demonstrated a significant reduction in pain on vertical percussion; • No tooth has regained pulp vitality; • Discoloration was significantly higher in the calcium hydroxide and chlorhexidine group; • Significant repair of the periapical lesion was observed in the group undergoing triple paste • Follow-up: 9 to 19 months 	The results of revascularization of trauma patients treated with the tested protocols presented similar clinical and radiographic data. However, the triple paste caused an aesthetic problem leading to discoloration of the teeth.
Aly <i>et al.</i> (2019)	To clinically and radiographically evaluate the effect of using two types of coronal plug materials on the revascularization of non-vital immature teeth.	<ul style="list-style-type: none"> • 26 teeth; • Patients aged 8 -15 years 	<ul style="list-style-type: none"> • Irrigation with sodium hypochlorite 1.5% • EDTA 5% • Indwelling dressing: Double antibiotic paste (metronidazole and ciprofloxacin) in 1/3 medium and apical – 4 weeks Sealing: White Mineral Trioxide Aggregate (MTA) or Biodentine® 	<ul style="list-style-type: none"> • There was no statistically significant difference between groups; • Group I (Biodentine®) achieved clinical and radiographic success of 100% and group II (MTA) achieved success of 91.66% at the end of the follow-up period • Follow-up: Up to 12 months 	Both Biodentine® and Mineral Trioxide Aggregate had clinical success in resolving the signs and symptoms associated with necrotic teeth.
	To compare clinical and radiographic success of regenerative endodontic	<ul style="list-style-type: none"> • 56 teeth • Patients between 18-30 years old 	<ul style="list-style-type: none"> • Irrigation with 1% sodium hypochlorite • EDTA 5% 	<ul style="list-style-type: none"> • There was no statistical difference between groups; 	Regenerative endodontic procedures have the potential to be used as a

<p>Arslan <i>et al.</i> (2019)</p>	<p>procedures and conventional endodontic treatment in mature necrotic teeth with periapical radiolucencies</p>	<p>without systemic changes</p>	<ul style="list-style-type: none"> ● Delay curative: Triple antibiotic paste ● (doxycycline, metronidazole and ciprofloxacin) in 1/3 medium and apical – 3 weeks ● Sealing: White Mineral Trioxide Aggregate (MTA) 	<ul style="list-style-type: none"> ● 92.3% and 80% in the regenerative treatment and conventional endodontic treatment groups, respectively, ● Half of the teeth treated with regenerative treatment responded to the electrical pulp test ● Follow-up: up to 12 months 	<p>treatment option for mature teeth with large periapical radiolucencies.</p>
------------------------------------	---	---------------------------------	---	--	--

Source: The authors.

4 DISCUSSION

Pulp revascularization has significant advantages for the harmonious development of the stomatognathic system (Ding et al., 2009; Soares et al., 2018; Aly et al., 2019; Arslan et al., 2019; Gupta et al., 2020; Rodrigues et al., 2020; Mannocci et al., 2022). However, other scientific evidence is encouraged in relation to the protocols and situations indicated. Thus, a systematic review of the literature on pulp revascularization therapy in non-vital permanent teeth was performed. Our results demonstrate that pulp revascularization therapy has a satisfactory prognosis, but few clinical studies have been carried out over the years to delimit protocols (Ding et al., 2009; Nagata et al., 2014; Aly et al., 2019; Arslan et al., 2019).

Several factors can be cited as influential in the success of pulp revascularization, such as: age of dental tissues and pulp, infection management, operative steps, use of biocompatible materials, among others (Arslan et al., 2019). Regarding the age of pulp and periradicular tissues, it is estimated that mesenchymal cells from the apical papilla of the young tooth can migrate to the root canal, stimulating the neoformation of pulp and dentin tissue, favoring rhizogenesis (Yu; Abbott, 2007; Piva et al., 2017; Xie et al., 2021). In our study, most of the articles were carried out on young patients and on teeth with incomplete rhizogenesis (Ding et al., 2009; Nagata et al., 2014; Aly et al., 2019). However, the promising results in relation to the reduction of clinical/radiographic signs and symptoms that indicate pulp necrosis, performed in young patients and teeth with complete rhizogenesis (Arslan et al., 2019), stand out. Such results encourage further studies that optimize the steps of instrumentation and disinfection of necrotic contents in the root canal system. Instrumentation performed with 5 or 6 sizes larger than the first working instrument (Saini et al., 2012), together with chemical disinfection, indicates the superiority of the pulp revascularization technique over conventional endodontic therapy (Arslan et al., 2019).

In the pulp revascularization protocol, irrigation of the root canal system with sodium hypochlorite was mentioned with various concentrations. Generally, lower concentrations are preferred to avoid toxicity to mesenchymal tissues (Aly et al., 2019; Arslan et al., 2019). However, it is noteworthy that the irrigation with 6% sodium hypochlorite described was used limited to the working length minus 3 mm to avoid toxicity to the periapical tissues. It is also evident that the indwelling dressing was performed with 2% chlorhexidine gel due to its extensive residual antimicrobial properties, diffusion in dentin tubules and low toxicity (Nagata et al., 2014); which is contrary to most studies that use intracanal medication of indwelling dressing based on antibiotic pastes (Ding et al., 2009; Aly et al., 2019; Arslan et al., 2019).

Antibiotic pastes use two or three antibiotics in their composition in order to disinfect and stimulate the complete development of the root canal system. Antibiotic pastes with the combination

of doxycycline, metronidazole and ciprofloxacin have been described (Ding et al., 2009; Arslan et al., 2019); metronidazole and ciprofloxacin (Aly et al., 2019). The use of antibiotic pastes demonstrates promising results and superior to the use of chlorhexidine and calcium hydroxide. However, widely cited disadvantages of antibiotic paste are coronary discoloration (Nagata et al., 2014) and the potential to cause bacterial resistance (Shin, 2009; Soares et al., 2013). Evidence suggests that other clinical studies are also carried out due to the lack of information on the amount of antibiotic paste administered and the time of use required, which can vary from 3 to 4 weeks (Ding et al., 2009; Nagata et al., 2014; Aly et al., 2019; Arslan et al., 2019). The excessive amount can lead to treatment failure since toxicity to mesenchymal cells (Chuensombat et al., 2013).

After the period of disinfection and clot formation inside the canal, another important step is cervical sealing with biocompatible material. The mineral trioxide aggregate (MTA) was considered the most recommended material for regenerative procedures to be placed on the blood clot, as it provides an excellent seal (Ding et al., 2004; Nagata et al., 2014; Arslan et al., 2019). Technically, the application of MTA on a blood clot is challenging since the condensation process can result in a displacement of the material apically (Aly et al., 2019). In addition, evidence also describes prolonged setting time and coronary discoloration even though it is white MTA (Arslan et al., 2019). Biodentine® is a material that has the same mechanical properties as human dentin, very low cytotoxicity and overcomes the clinical disadvantages of MTA in relation to discoloration (Aly et al., 2019). Biodentine® is a tooth-colored material that causes less discoloration when compared to other calcium silicate materials (Nagy et al., 2014; Yoldas et al., 2016) due to the presence of the material at the level of the orifice. Biodentine® has better consistency and allows condensation without any apical displacement. Setting time of 12 minutes is cited, allowing placement of the composite restoration in the same consultation (Aly et al. 2019). However, further studies are needed since only the study by Aly et al. (2019) brings the use of Biodentine® in pulp revascularization.

Finally, it is hoped that the present systematic review can contribute with scientific evidence and delimitation of protocols for pulp revascularization in young patients.

5 CONCLUSION

Pulp revascularization, although little evidenced in the correlated and specific literature, demonstrates promising clinical and radiographic results in relation to endodontic rehabilitation.

CONFLICT OF INTEREST STATEMENT

The authors declare no conflict of interest.

ACKNOWLEDGMENT

The Coordination for the Improvement of Higher Education Personnel – CAPES - Brazil.

FINANCING

The research was carried out with financial support from the Coordination for the Improvement of Higher Education Personnel (CAPES-Brasil) – PDPG-POSDOC/Scholarship - nº 88887.755620/2022-00.

REFERENCES

AAE - American Association of Endodontists. regenerative endodontics. Regenerative Endodontics. 2022. Disponível em: <https://www.aae.org/specialty/clinical-resources/regenerative-endodontics/>. Acesso em: 20 agosto 2023.

ALY, M. M.; TAHA, S. E. E. D.; EL SAYED, M. A.; YOUSSEF, R.; OMAR, H. M. Clinical and radiographic evaluation of Biodentine and Mineral Trioxide Aggregate in revascularization of non-vital immature permanent anterior teeth (randomized clinical study). *International Journal of Paediatric Dentistry*, v. 29, n. 4, p. 464-473, 2019. Disponível em: <https://onlinelibrary.wiley.com/doi/abs/10.1111/ipd.12474>. Acesso em: 22 de novembro 2023.

ARSLAN, H.; AHMED, H. M. A.; ŞAHIN, Y.; YILDIZ, E. D.; GÜNDOĞDU, E. C.; GÜVEN, Y.; KHALILOV, R. Regenerative endodontic procedures in necrotic mature teeth with periapical radiolucencies: a preliminary randomized clinical study. *Journal of Endodontics*, v. 45, n. 7, p. 863-872, 2019. Disponível em: <https://www.sciencedirect.com/science/article/pii/S0099239919302948>. Acesso em: 11 de novembro 2023.

BRATTEBERG, M.; THELEN, D. S.; KLOCK, K. S.; BÅRDSSEN, A. Traumatic dental injuries and pulp sequelae in an adolescent population. *Dental Traumatology*, v. 37, n. 2, p. 294-301, 2021. Disponível em: <https://onlinelibrary.wiley.com/doi/abs/10.1111/edt.12635>. Acesso em: 21 de outubro 2023.

CHUENSOMBAT, S.; KHEMMALEELAKUL, S.; CHATTIPAKORN, S.; SRISUWAN, T. Cytotoxic effects and antibacterial efficacy of a 3-antibiotic combination: an in vitro study. *Journal of Endodontics*, v. 39, n. 6, p. 813-819, 2013. Disponível em: <https://www.sciencedirect.com/science/article/abs/pii/S0099239912011181>. Acesso em: 01 de dezembro 2023.

DING, R. Y.; CHEUNG, G. S. P.; CHEN, J.; YIN, X. Z.; WANG, Q. Q.; ZHANG, C. F. Pulp revascularization of immature teeth with apical periodontitis: a clinical study. *Journal of Endodontics*, v. 35, n. 5, p. 745-749, 2009. Disponível em: <https://www.sciencedirect.com/science/article/abs/pii/S009923990900137X>. Acesso em: 27 de novembro 2023.

GALLER, KM; KRASTL, G.; SIMON, S.; VAN GORP, G.; MESCHI, N.; VAHEDI, B.; LAMBRECHTS, P. European Society of Endodontology position statement: Revitalization procedures. *International Endodontic Journal*, v. 49, n. 8, p. 717-723, 2016. Disponível em: <https://onlinelibrary.wiley.com/doi/abs/10.1111/iej.12629>. Acesso em: 11 de setembro 2023.

GUPTA, S.; SODHI, S. P.; BRAR, G. K.; BANSAL, R. N. Endodontic treatment of immature tooth-a challenge. *Journal of Pre-Clinical and Clinical Research*, v. 14, n. 3, p. 73-79, 2020. Disponível em: <https://www.jpccr.eu/Endodontic-treatment-of-immature-tooth-a-challenge,126280,0,2.html>. Acesso em: 15 de novembro 2023.

KAZEMINIA, M.; ABDI, A.; SHOHAIMI, S.; JALALI, R.; VAISI-RAYGANI, A.; SALARI, N.; MOHAMMADI, M. Dental caries in primary and permanent teeth in children's worldwide, 1995 to 2019: a systematic review and meta-analysis. *Head & Face Medicine*, v. 16, n. 1, p. 1-21, 2020. Disponível em: <https://head-face-med.biomedcentral.com/articles/10.1186/s13005-020-00237-z>. Acesso em: 30 de setembro 2023.

- MANNOCCI, F.; BITTER, K.; SAURO, S.; FERRARI, P.; AUSTIN, R.; BHUVA, B. Present status and future directions: The restoration of root filled teeth. *International Endodontic Journal*, v. 55, p. 1059-1084, 2022. Disponível em: <https://onlinelibrary.wiley.com/doi/full/10.1111/iej.13796>. Acesso em: 04 de outubro 2023.
- NAGATA, J. Y.; DE ALMEIDA GOMES, B. P. F.; LIMA, T. F. R.; MURAKAMI, L. S.; DE FARIA, D. E.; CAMPOS, G. R.; DE SOUZA-FILHO, F. J.; DE JESUS SOARES, A. Traumatized immature teeth treated with 2 protocols of pulp revascularization. *Journal of Endodontics*, v. 40, n. 5, p. 606-612, 2014. Disponível em: <https://www.sciencedirect.com/science/article/abs/pii/S0099239914000934>. Acesso em: 18 de novembro 2023.
- NAGY, M. M.; TAWFIK, H. E.; HASHEM, A. A. R.; ABU-SEIDA, A. M. Regenerative potential of immature permanent teeth with necrotic pulps after different regenerative protocols. *Journal of Endodontics*, v. 40, n. 2, p. 192-198, 2014. Disponível em: <https://www.sciencedirect.com/science/article/abs/pii/S0099239913009734>. Acesso em: 02 de dezembro 2023.
- PAGE, M. J.; MCKENZIE, J. E.; BOSSUYT, P. M.; BOUTRON, I.; HOFFMANN, T. C. MULROW, C. D.; SHAMSEER, L.; TETZLAFF, J. M.; AKL, E. A.; BRENNAN, S. E.; CHOU, R.; GLANVILLE, J.; GRIMSHAW, J. M.; HRÓBJARTSSON, A.; LALU, M. M.; LI, T.; LODER, E. W.; MAYO-WILSON, E.; MCDONALD, S.; MCGUINNESS, L. A.; STEWART, L. A.; THOMAS, J.; TRICCO, A. C.; WELCH, V. A.; WHITING, P.; MOHER, D. The PRISMA 2020 statement: an updated guideline for reporting systematic reviews. *BMJ*, v. 29, n. 372, p. 71, 2021. Disponível em: <https://pubmed.ncbi.nlm.nih.gov/33782057/> Acesso em: 10 de novembro de 2023.
- PETTI, S.; GLENDOR, U.; ANDERSSON, L. World traumatic dental injury prevalence and incidence, a meta-analysis—One billion living people have had traumatic dental injuries. *Dental Traumatology*, v. 34, n. 2, p. 71-86, 2018. Disponível em: <https://onlinelibrary.wiley.com/doi/full/10.1111/edt.12389>. Acesso em: 08 de outubro 2023.
- PIVA, E.; TARLÉ, S. A.; NÖR, J. E.; ZOU, D.; HATFIELD, E.; GUINN, T.; EUBANKS, E. J.; KAIGLER, D. Dental pulp tissue regeneration using dental pulp stem cells isolated and expanded in human serum. *Journal of Endodontics*, v. 43, n. 4, p. 568-574, 2017. Disponível em <https://www.sciencedirect.com/science/article/abs/pii/S0099239916309682>. Acesso em: 08 de setembro 2023.
- RICUCCI, D., SIQUEIRA JR, J. F., LOGHIN, S., LIN, L. M. Pulp and apical tissue response to deep caries in immature teeth: a histologic and histobacteriologic study. *Journal of Dentistry*, v. 56, p. 19-32, 2017. Disponível em: <https://www.sciencedirect.com/science/article/abs/pii/S0300571216302056>. Acesso em: 18 de outubro 2023.
- RODRIGUES, M. D. P.; SOARES, P. B. F.; GOMES, M. A. B.; PEREIRA, R. A.; TANTBIROJN, D.; VERSLUIS, A.; SOARES, C. J. Direct resin composite restoration of endodontically-treated permanent molars in adolescents: bite force and patient-specific finite element analysis. *Journal of Applied Oral Science*, v. 28, 2020. Disponível em: <https://www.scielo.br/j/jaos/a/bZRqn6NzqL4YYZnBnhYvyVG/?format=html&lang=e>. Acesso em: 29 de outubro 2023.
- SAINI, H. R.; TEWARI, S.; SANGWAN, P.; DUHAN, J.; GUPTA, A. Effect of diferente apical preparation sizes on outcome of primary endodontic treatment: a randomized controlled trial. *Journal of Endodontics*, v. 38, n. 10, p. 1309-1315, 2012. Disponível em:

<https://www.sciencedirect.com/science/article/abs/pii/S0099239912006061>. Acesso em: 01 de dezembro 2023.

SHIN, S. Y.; ALBERT, J. S.; MORTMAN, R. E. One step pulp revascularization treatment of an immature permanent tooth with chronic apical abscess: a case report. *International Endodontic Journal*, v. 42, n. 12, p. 1118-1126, 2009. Disponível em: <https://onlinelibrary.wiley.com/doi/abs/10.1111/j.1365-2591.2009.01633.x>. Acesso em: 05 de novembro 2023.

SILVA, M. L. C., DE VASCONCELOS, E. M. G. M., DE PASQUALI LEONARDI, M. F., RAMALHO, C. L. G. Regeneração Pulpar: Uma nova opção terapêutica em dentes definitivos imaturos. ID on line. *Revista de Psicologia*, v. 17, n. 65, p. 1-17, 2023. Disponível em: <https://idonline.emnuvens.com.br/id/article/view/3685>. Acesso em: 06 de outubro 2023.

SOARES, C. J.; RODRIGUES, M. D. P.; FARIA-E-SILVA, A. L.; SANTOS-FILHO, P. C. F.; VERÍSSIMO, C.; KIM, H. C.; VERSLUIS, A. How biomechanics can affect the endodontic treated teeth and their restorative procedures? *Brazilian Oral Research*, v. 32, 2018. Disponível em: <https://www.scielo.br/j/bor/a/TcSFzSrsWRdR7GG9Ckx8Rz/?lang=en>. Acesso em: 10 de outubro 2023.

XIE, Z.; SHEN, Z.; ZHAN, P.; YANG, J.; HUANG, Q.; HUANG, S.; CHEN, L.; LIN, Z. Functional dental pulp regeneration: basic research and clinical translation. *International Journal of Molecular Sciences*, v. 22, n. 16, p. 8991, 2021. Disponível em: <https://www.mdpi.com/1422-0067/22/16/8991>. Acesso em: 07 de setembro 2023.

YOLDAS, S. E.; BANI, M.; ATABEK, D.; BODUR, H. Comparison of the potential discoloration effect of bioaggregate, biodentine, and white mineral trioxide aggregate on bovine teeth: in vitro research. *Journal of Endodontics*, v. 42, n. 12, p. 1815-1818, 2016. Disponível em: <https://www.sciencedirect.com/science/article/abs/pii/S0099239916305738>. Acesso em: 03 de dezembro 2023.

YU, C., ABBOTT, P. V. An overview of the dental pulp: its functions and responses to injury. *Australian Dental Journal*, v. 52, p. S4-S6, 2007. Disponível em: <https://onlinelibrary.wiley.com/doi/abs/10.1111/j.1834-7819.2007.tb00525.x>. Acesso em: 22 de setembro 2023.