

## PALATAL MEMORY PLATE IN TRISSOMY 21: BENEFITS OF EARLY INTERVENTION IN OROFACIAL DEVELOPMENT

### PLACA PALATINA DE MEMÓRIA NA TRISSOMIA 21: BENEFÍCIOS DA INTERVENÇÃO PRECOCE NO DESENVOLVIMENTO OROFACIAL

### PLACA DE MEMORIA PALATINA EN LA TRISOMÍA 21: BENEFICIOS DE LA INTERVENCIÓN TEMPRANA EN EL DESARROLLO OROFACIAL



<https://doi.org/10.56238/sevned2026.019-040>

Kely Dalapicola<sup>1</sup>, Ana Lúcia Vendel<sup>2</sup>

#### ABSTRACT

The Palatal Memory Plate (PMP) is a transdisciplinary therapeutic resource aimed at early intervention in infants with Trisomy 21 (T21) and in cases of marked orofacial hypotonia. Indicated from two months of age, the PMP promotes the balance of the stomatognathic system, favoring vital functions such as nasal breathing, sucking, swallowing, chewing, and phonation, positively impacting the individual's overall development. Children with T21 frequently present orofacial characteristics such as hypoplasia of the midface, relative pseudomacroglossia, delayed tooth eruption, malocclusions, and labial and lingual hypotonia, which can compromise breastfeeding, swallowing, breathing, and sleep. Early intervention with PPM (Positive Myofunctional Therapy), combined with myofunctional therapy, acts on the postural reorganization of the tongue and lips, stimulates lip seal, automates nasal breathing, and strengthens the orofacial musculature, promoting harmonious development of the face and stomatognathic functions. Ten infants with Down syndrome (T21) were evaluated, and this study demonstrates that the application of PPM, accompanied by speech therapy and pediatric dentistry guidance, resulted in significant improvement in the habitual posture of the tongue and lips, muscle adaptation, and feeding functions. The effectiveness of PPM depends on adequate supervision and multidisciplinary integration, representing an effective therapy when the intervention is early, contributing to the reorganization of the orofacial musculature, prevention of future alterations and malocclusions, and improvement in the quality of life of people with T21.

**Keywords:** Down Syndrome. Orofacial Hypotonia. Myofunctional Therapy. Stomatognathic System.

#### RESUMO

A Placa Palatina de Memória (PPM) constitui um recurso terapêutico transdisciplinar voltado à intervenção precoce em bebês com Trissomia do Cromossomo 21 (T21) e em casos de hipotonicidade orofacial acentuada. Indicada a partir de dois meses de idade, a PPM promove o equilíbrio do sistema estomatoglossognático, favorecendo funções vitais como respiração nasal, sucção, deglutição, mastigação e fonação, impactando positivamente no

<sup>1</sup> Specialist in Functional Orthopedics. E-mail: drakelydalapicola@gmail.com

<sup>2</sup> Dr. in Zoology. Universidade Estadual da Paraíba. E-mail: analuciavendel@servidor.uepb.edu.br

desenvolvimento global do indivíduo. Crianças com T21 frequentemente apresentam características orofaciais como hipoplasia do terço médio da face, pseudomacroglossia relativa, atraso na erupção dentária, maloclusões e hipotonia labial e lingual, que podem comprometer a sucção do leite materno, a deglutição, a respiração e o sono. A intervenção precoce com PPM, aliada à terapia miofuncional, atua na reorganização postural da língua e dos lábios, estimula o selamento labial, automatiza a respiração nasal e fortalece a musculatura orofacial, promovendo desenvolvimento harmônico da face e das funções estomatoglossognáticas. Foram avaliados dez bebês com T21 e demonstra-se aqui que a aplicação da PPM, acompanhada de orientação fonoaudiológica e odontopediátrica, resultou em melhora expressiva na postura habitual da língua e dos lábios, adaptação muscular e funções alimentares. A eficácia da PPM depende de supervisão adequada e integração multidisciplinar, representando uma terapia eficaz quando a intervenção é precoce, contribuindo para a reorganização da musculatura orofacial, prevenção de alterações e maloclusões futuras e melhoria da qualidade de vida de pessoas com T21.

**Palavras-chave:** Síndrome de Down. Hipotonia Orofacial. Terapia Miofuncional. Sistema Estomatoglossognático.

## RESUMEN

La Placa de Memoria Palatina (PMP) es un recurso terapéutico transdisciplinario dirigido a la intervención temprana en lactantes con trisomía 21 (T21) y en casos de hipotonía orofacial marcada. Indicada a partir de los dos meses de edad, la PMP promueve el equilibrio del sistema estomatognático, favoreciendo funciones vitales como la respiración nasal, la succión, la deglución, la masticación y la fonación, impactando positivamente en el desarrollo general del individuo. Los niños con T21 frecuentemente presentan características orofaciales como hipoplasia del tercio medio facial, pseudomacroglosia relativa, erupción dental tardía, maloclusiones e hipotonía labial y lingual, que pueden comprometer la lactancia materna, la deglución, la respiración y el sueño. La intervención temprana con PPM (Terapia Miofuncional Positiva), combinada con terapia miofuncional, actúa sobre la reorganización postural de la lengua y los labios, estimula el sellado labial, automatiza la respiración nasal y fortalece la musculatura orofacial, promoviendo un desarrollo armónico de la cara y las funciones estomatognáticas. Se evaluaron diez lactantes con síndrome de Down (T21), y este estudio demuestra que la aplicación de la terapia miofuncional orofacial (TMO), acompañada de terapia del habla y orientación odontológica pediátrica, resultó en una mejora significativa de la postura habitual de la lengua y los labios, la adaptación muscular y las funciones de alimentación. La eficacia de la TMO depende de una supervisión adecuada y una integración multidisciplinaria, lo que la convierte en una terapia eficaz cuando la intervención es temprana, contribuyendo a la reorganización de la musculatura orofacial, la prevención de futuras alteraciones y maloclusiones, y la mejora de la calidad de vida de las personas con T21.

**Palabras clave:** Síndrome de Down. Hipotonía Orofacial. Terapia Miofuncional. Sistema Estomatognático.

## 1 INTRODUCTION

The memory palatal plate (MPP) represents a transdisciplinary therapeutic resource of early intervention for use in infants with Trisomy 21 (T21), formerly known as Down Syndrome, as well as in cases of marked hypotonocity of the orofacial muscles, many of which are idiopathic. Such an opportunity for intervention, very early, occurs from two months of life, takes the focus off the teeth and mouth and broadens the vision of the professionals involved, namely pediatric dentist and speech therapist, in the search for the balance of basic and vital functions, rebalancing the entire stomatoglossognathic system. As such, the focus should be on the potentialities and interventions made to contribute to the child's development and not on the limitations that Trisomy 21 and other disabilities often represent in an initial contact.

Trisomy 21 is not a disease, but a genetic condition, with its nomenclature associated with the presence of 1 more chromosome in pair 21. It is currently referred to as T21, a term used here.

The gold standard for the diagnosis of Trisomy 21 is to perform the karyotype with an extra copy of the long arm of chromosome 21 (Lejeune et al., 1959), naturally it is the most common human aneuploidy among live births. However, it can be diagnosed clinically based on the characteristic appearance (facial gestalt) and behavior of affected individuals Radhakrishnan et al. (2018). The facial gestalt characteristic of Trisomy 21 is an important clinical tool for syndromic recognition, especially in the first moments of neonatal and pediatric evaluation. This concept refers to the global set of observable phenotypic characteristics, especially craniofacial, which, when analyzed together, allow for a strong diagnostic suspicion. Among the most frequently described findings are a flat face, flattened nasal bridge, superior oblique palpebral fissures, small ears, and relative protrusion of the tongue. As described by Radhakrishnan et al. (2018), facial gestalt represents an essential resource in the clinical identification of Trisomy 21, aiding diagnosis and early indication for cytogenetic confirmation, whose blood collection must occur even before leaving the maternity hospital, as ensured by law (Municipal Law 13.548/2017), in force in João Pessoa, Paraíba, Northeast Brazil.

Among the typical characteristics in neonates with Trisomy 21 are hypotonia and hyperextension, associated with a smaller maxilla, due to hypoplasia of the middle third of the face (Ferreira et al., 2023) and this affects breathing, speech, dental arch, and auditory processing (Abbeduto et al., 2015). This often causes difficulty in sucking and swallowing breast milk and the consequent search for adequate guidance to prioritize breastfeeding (Dantas et al., 2022).

There is also a compromise in the quality of sleep of people with T21, hence the need for early intervention in the baby (Guilleminaut; Eldridge; 1976; Gonçalves et al., 2011; Jayaratne et al., 2017). Sleep disturbances in individuals with Trisomy 21 have been associated with differences in facial morphology assessed in 3D and specific changes reported include adenotonsillar hyperplasia, mesofacial and mandibular hypoplasia, hypotonia, macroglossia, choanal atresia, an acute angle of the cranial base, and small upper airways (Jayaratne et al., 2017). Fernandez et al. (2017) describe that overall sleep quality was poor and efficiency scores were lower in infants with Trisomy 21 than in children with neurotypical development. Infants with Trisomy 21 exhibited greater sleep fragmentation, although sleep efficiency and consolidation increased with age, the authors highlight a high prevalence of sleep apnea, up to 50% in preschool-aged children with T21 (Fernandez et al., 2017). Thus, the importance of balance and muscle tone for the quality of life of individuals with T21 is clear and evident. This ensures them a better development and execution of basic functions such as breathing, sucking, swallowing and, subsequently, chewing and articulating a comprehensive oral expression.

In T21, some oral characteristics are found and can be observed very early (Table 1). They are:

Late tooth eruption, which favors the use of the memory palatal plate, as the late and asynchronous dentition will be complete around 4 to 5 years.

Babies have midface hypoplasia, that is, a smaller maxilla due to the middle third of the face being reduced. The skull is slightly microcephalic and brachycephalic with a flat occipital. The fontanelles tend to be large, a third fontanelle may be palpable, and close late. The face is round in the newborn and in the nursing mother. Usually the nostrils are small, the mouth is facing downwards and a small oral cavity generates a tendency to protrude the tongue and breathe through the mouth. The growth of the jaw tends to overtake the palate leading to prognathism.

Tooth wear is twice as common in T21 when compared to the neurotypical population, which is supported by a high rate of bruxism and has repercussions on the increase in cases of gastric reflux. Pseudomacroglossia refers to the condition in which the tongue is normal in size, but appears to be enlarged due to anatomical or functional factors of the oral environment, such as reduction of the intraoral space, resulting from narrow dental arches, mandibular retrognathism, or hypertrophy of adjacent structures (Proffit; Fields; Sarver, 2013). It is a relative macroglossia and a greater hypotonicity of the muscles of the oropharynx, which, as well as

excessive salivation and a shortened and thick lingual frenulum, represent factors that contribute to the difficulties in feeding, breathing, swallowing and speaking.

**Table 1**

*Oral characteristics found in T21*

Delay in tooth eruption
High susceptibility to periodontal disease
Excessive salivation
Conoid teeth
Aresic jaw
Dental Agenesis
Malocclusions
Mouth breathing
Shortened and thick lingual frenulum
Impaired sleep quality

Source: Authors.

The memory palatal plate is a great ally in this initial development process of people with Trisomy 21, because through this therapeutic resource, an early intervention correctly organizes and stimulates stomatoglossognathic functions. As demonstrated, the partnership between speech therapist and pediatric dentist is essential.

All these characteristics are common in T21, but we also notice them in typical children, not making it impossible for them to be treated in the same way.

Within the scientific community there is a consensus that we cannot assign degrees to Trisomy 21 (Down Syndrome), that is, there are no degrees, although each child expresses the genes in a specific way. Some with more pronounced hypotonia on the face, others not, so the attentive and personalized look must exist.

The etiology of the characteristic appearance and associated specific features of Trisomy 21 are presumed to be related to the effects of dosing chromosome 21 genes, but epigenetic effects may also contribute.

The guiding principle when it comes to development is called stimulus. Early and correct stimulation during the first year of life, a period of greater development of the central nervous system and the baby's oral cavity, makes all the difference for a good global development of the individual, whether with T21 or a typical person. Therefore, the Memory Palatal Plate is an option that allows for early stimuli.

From birth, nasal breathing is a vital situation for human beings. This is physiological respiration, which favors the growth and good anatomical and functional development of the

most diverse structures of the body. It directly influences the maintenance of skeletal, dental and muscular organization of the stomatoglossognathic system, orofacial functions, as well as physical and intellectual development. When this breathing starts to occur orally, it forces the stomatoglossognathic system to promote structural changes in its functionality. This endangers the existing balance between masticatory functions, the position of the tongue at rest, swallowing, breathing and phonation, conditions that contribute to good development and orofacial growth. The muscles of the face must work in a balanced way so that the growth and development of the bones of the face happen in a correct and symmetrical way (Carvalho, 2010).

The child, when breathing through the mouth, needs to adapt the posture of the head to be able to breathe better, forwarding it so that the air reaches the lungs more quickly, flexing the neck forward, rectifying the path of the airways. This movement causes changes in the posture of the mandible, the hyoid bone and the tongue, bringing consequences for facial growth and occlusion, interfering with eating functions (sucking, chewing and swallowing). Therefore, some interventions can start in babies as young as 2 months old.

## **2 PRESENTATION OF CLINICAL CASES**

The research participants consisted of ten children diagnosed with T21, aged between 02 and 24 months. None of them had other associated syndromes, craniofacial malformations, cardiac or respiratory disorders. These participants were recruited from among those treated at the clinic where the study was conducted. Because the children were diagnosed with T21, they were evaluated by a pediatric dentist and a speech therapist at the first meeting. The myofunctional and orofacial evaluation included the verification of tone, habitual posture of lips and tongue, lingual frenulum, as well as anamnesis to investigate the food provided by the caregiver and the presence of oral habits.

All of them had decreased lips and tongue tone and altered habitual posture, with increased salivation and unaltered frenulum of the tongue. Then, after explaining to the family about the proposed therapy, the speech therapist proceeded with the desensitization to the mold and subsequent use of the PPM, with the number of sessions appropriate to each case, and the pediatric dentist made the mold of the upper arch of each participant to make the PPM, which was delivered the following week. to those responsible for the child. The PPMs used can be seen in Figure 1. From then on, the participants received the PPM and the parents were instructed to insert it into the child's oral cavity at least four times a day, with a minimum period of 30 supervised minutes. They were also instructed to increase the use according to the

evolution of the child's adaptation and comfort. Those responsible were also instructed on the hygiene of the plate and not to use it during feeding, nor during sleep or away from an adult's observation.

### 3 RESULTS AND DISCUSSION

The memory palatal plate (Figure 1) is defined as a removable intraoral device, made of acrylic, initially designed by Castillo-Morales (1991), with the objective of assisting the correct positioning of the tongue and stimulating lip sealing, encouraging nasal breathing. It is indicated for babies with lip hypotonia, absence of lip sealing, and tongue protrusion, contributing to myofunctional balance, nasal breathing, and the harmonious growth and development of facial bones and muscles (Furlan et al., 2022; Carvalho et al., 2025).

The memory palate plate is a great ally in this initial development process of people with Trisomy 21, because through this therapeutic resource, it is possible to correctly organize and stimulate the stomatoglossognathic functions in the baby at an early age. As demonstrated, the partnership between speech therapist and pediatric dentist is essential.

#### Figure 1

*Palatal memory plates with expander screw used in the study*



Source: Dalapicola, K.

The alterations mentioned above (Table 1) favor the malfunction of the stomatoglossognathic system, because for the functions of this system to be carried out effectively, it is necessary that the responsible structures work in harmony, which will favor its development, using a minimum expenditure of energy by the child (Medeiros, 2016). However, when any constituent of this system operates inadequately, imbalances may occur that have

repercussions on the other stomatognathic functions, compromising the functional harmony of the system (Marchesan; Krakauer, 2011).

In clinical practice, there is a prevalence of teeth with morphological anomalies, the most common being the conoid shape, characterized by being narrow and tapered. Dental crowns are smaller and shorter, and this can contribute to the instability and susceptibility to tooth loss associated with periodontal disease. In addition, there is atresia in the maxilla and deep palate, which require attention in the exercises instructed by the speech therapist. The occurrence of agenesis or supernumerary dentition also shows a higher than expected record in the population with T21 when compared to neurotypical children.

Among the consequences, mouth breathing, snoring, and respiratory apneas during sleep stand out. In turn, the high incidence of periodontal disease may be due to hypotonia, laxity of the dentoalveolar joint, poor dental hygiene, and immune system deficiencies.

Regarding malocclusions, the most common in this study was anterior crossbite, due to the tongue resting on the oral floor. Occlusal problems, most often in the central, lateral, and canine incisors, are common and result from mouth breathing, chewing difficulty, dental agenesis, shortening and asymmetry of the upper arch, and temporomandibular problems.

After a combination of techniques, Dr. Fabiane Bittar (CFO, 2023) innovated by adding the expander screw, used in functional jaw orthopedics appliances and developed the memory palate plate used here, whose mold is made with dental molding material, addition silicone, heavy paste and catalyst in personalized acrylic trays

A first and important step in conducting the process of using PPM is the desensitization of the baby's oral cavity for molding and use of the plate itself. In this process, the speech therapist and the pediatric dentist work together (Figure 2a-c). After the initial intervention, periodic follow-up is followed so that the determined objectives are achieved and the plate is adjusted and even discontinued when the goal defined in that baby is met (Figure 3a-c).

**Figure 2**

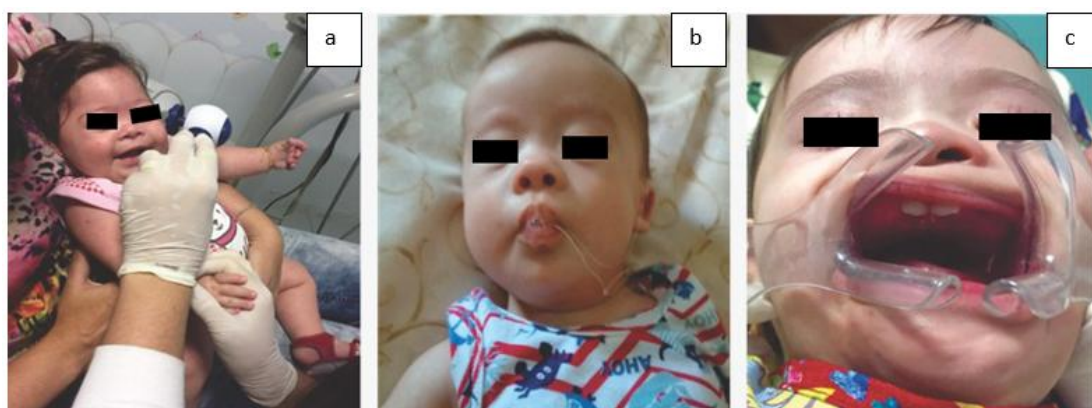
*Interventions with speech therapy to desensitize the oral cavity of the infant with T21, to receive the memory palatal plate*



Source: Dalapicola, K.

**Figure 3**

*a) Speech therapy with extraoral stimuli; b) Baby with T21 with the plate in the mouth showing adaptation and acceptance; c) Palatal plaque being relieved in the region of 51 and 61 so as not to prevent the eruption of the teeth*



Source: Dalapicola, K.

The sooner the treatment begins, the greater the baby's acceptance, the better the muscle memory and its conditioning to use; therefore, PPM is indicated from 2 months of age.

The use of the plate seeks to minimize the existing orofacial changes, correcting the tongue posture from an early age, working on lip sealing with the objective of returning nasal breathing, training the muscles of the face, developing swallowing, chewing and later speech. This was evidenced as soon as the children with T21 used the plate for the first time (Figure 4).

Technological advances in the health area have enabled the development of increasingly aesthetic and minimally invasive therapeutic approaches. In this context, the importance of integrating functionality and aesthetics is emphasized, as long as such association does not imply risks or discomfort to the patient. Thus, the elaboration of the therapeutic plan should consider the particularities of the family routine, including aspects such as the responsible caregiver, adherence to the use of the device, time of use and availability for clinical follow-up. Such factors are determinant for the effectiveness of treatment, especially in interventions that require continuous use of intraoral devices, such as PPM (CFO, 2023 p. 28).

#### Figure 4

*Before and after: evidence of immediate lip sealing after use of the memory palate plate in children with T21*



Source: Dalapicola, K.

It has been confirmed that hypotonia of the orofacial muscles is evident in Trisomy 21, since there is a global hypotonia (Mustacchi; Rozoni, 1990), which can limit basic and vital functions such as breathing, sucking and swallowing. Later, it can compromise chewing and speech. Dentistry can be a great ally, enabling early intervention through these therapeutic resources. Evaluating the applicability of PPM as early as possible was also recorded by Ferreira et al. (2023) in babies with Trisomy 21, the authors concluded that the Memory Palatal Plaque associated with myofunctional therapy was more effective when started early, between 1 and 2 months of age, with records of advances in the usual posture of the tongue and lips, especially in patients who had more altered postural conditions in the initial evaluation.

Decreased tone in the perioral muscles, lips, and masticatory muscles, as well as decreased tongue movements, can lead to sucking difficulties in infants with Trisomy 21. They tend to breastfeed for less time, have more respiratory infections, and develop non-nutritive sucking habits, such as increased dependence on bottle-feeding, finger sucking, and pacifier use (Abbeduto et al., 2015). Understanding the specificities in the development of Trisomy 21 represents a look at the most diverse fronts of action and should encompass all children, not only those with T21.

#### **4 CONCLUSION**

In view of the above, it is concluded that the use of PPM brings clear benefits to babies with T21, such as stimulating the tongue to be in the correct position, that is, on the palate, adequate stimulation for better lip sealing, automating nasal breathing, improving maxillary development and avoiding mandibular protrusion. Emphasizing that PPM is an auxiliary means of treatment, its use alone, in isolation, does not imply satisfactory results in the face of the challenges of global hypotonia, innate at T21.

Treatment with the memory palatal plate ideally begins with the baby at two months of age and monthly follow-up in general for a period of one year to a year and a half, depending on the tooth eruption and evaluating the improvement in the functions of the orofacial muscles.

The control of the plate must be done by competent and properly trained professionals. The use of the splint without the respective orofacial treatment with a multidisciplinary team is considered, totally meaningless. Performed early, treatment can avoid more invasive interventions and severe malocclusions in the future.

Early intervention and finely tuned partnership between pediatric dentist and speech therapist achieve very satisfactory results in the orofacial development of children with T21, as they allow significant improvement in hypotonia, re-educating and strengthening the oral

muscles, correcting tongue protrusion, normalizing and returning nasal breathing, factors that reflect an improvement in the quality of life of these patients.

## REFERENCES

- Abbeduto, L., Warren, S. F., & Conners, F. A. (2007). Language development in Down syndrome: From the prelinguistic period to the acquisition of literacy. *Mental Retardation and Developmental Disabilities Research Reviews*, 13(3), 247–261. <https://doi.org/10.1002/mrdd.20158>
- Bartesaghi, R., et al. (2015). New perspectives for the rescue of cognitive disability in Down syndrome. *Journal of Neuroscience*, 35(41), 13843–13852. <https://doi.org/10.1523/JNEUROSCI.2775-15.2015>
- Carvalho, G. D. S. O. S. (2010). *Respirador bucal: Uma visão funcional e dinâmica da amamentação* (2nd ed.). Lovise.
- Carvalho, T. M., et al. (2025). Interdisciplinaridade entre odontologia e fonoaudiologia: Placa palatina de memória em bebê com síndrome de Down. *Revista Ciências e Odontologia*, 9(2).
- Castillo-Morales, R. (1991). *Orofacial regulation therapy*. Springer.
- Conselho Federal de Odontologia. (2023). *Sorrisos brasileiros: A revista da nova odontologia* (Ano 3, No. 8). <https://website.cfo.org.br/wp-content/uploads/2023/10/Sorriso-Brasileiros-ed.8-baixa.pdf>
- Dantas, D. O., Silva, H. L. da, & Santos, W. L. dos. (2022). Aleitamento materno: Condições especiais e contraindicações. *Revista JRG de Estudos Acadêmicos*, 5(10), 395–408. <https://doi.org/10.5281/zenodo.6952852>
- Fernandez, F., et al. (2017). Young children with Down syndrome show normal development of circadian rhythms, but poor sleep efficiency: A cross-sectional study across the first 60 months of life. *Sleep Medicine*, 33, 134–144. <https://doi.org/10.1016/j.sleep.2016.12.026>
- Ferreira, J. E. A., et al. (2023). Terapia miofuncional orofacial associada ao uso da placa palatina de memória em crianças com trissomia do 21: Estudo de casos. *CoDAS*, 35(5), e20210231. <https://doi.org/10.1590/2317-1782/20232021231pt>
- Furlan, R. M. M. M., Almeida, T. D. D., & Pretti, H. (2022). Efeitos da placa palatina de memória associada à estimulação orofacial na postura habitual de língua e de lábios de crianças com trissomia do 21: Revisão integrativa da literatura. *Revista CEFAC*, 24(2). <https://doi.org/10.1590/1982-0216/20222427021s>
- Gonçalves, H. A., Pureza, J. R., & Prando, M. L. (2011). Transtorno de déficit de atenção e hiperatividade: Breve revisão teórica no contexto da neuropsicologia infantil. *Neuropsicologia Latinoamericana*, 3(3), 20–24. <http://dx.doi.org/10.5579/rnl.2011.0076>
- Guilleminault, C., et al. (1976). Sleep apnea in eight children. *Pediatrics*, 58(1), 23–30.

Jayaratne, Y. S. N., Elsharkawi, I., Macklin, E. A., Voelz, L., Weintraub, G., Rosen, D., & Skotko, B. G. (2017). The facial morphology in Down syndrome: A 3D comparison of patients with and without obstructive sleep apnea. *American Journal of Medical Genetics Part A*, 173(11), 3013–3021. <https://doi.org/10.1002/ajmg.a.38399>

Lei Municipal nº 13.548, de 29 de dezembro de 2017. (2017). Diário Oficial do Município de João Pessoa.

Lejeune, J., Gautier, M., & Turpin, R. (1959). Études des chromosomes somatiques de neuf enfants mongoliens. *Comptes Rendus de l'Académie des Sciences*, 248, 1721–1722.

Marchesan, I. Q., & Krakauer, L. H. (2011). A postura corporal e as funções estomatognáticas em crianças respiradoras orais: Uma revisão de literatura. *Revista CEFAC*, 13(3).

Mustacchi, Z., & Rozone, G. (1990). Síndrome de Down: Aspectos clínicos e odontológicos. CID Editora.

Proffit, W. R., Fields, H. W., & Sarver, D. M. (2013). *Ortodontia contemporânea* (5th ed.). Elsevier.