



Chapter 279

The implementation of clinical quality control in mammography exams: Challenges for professionals and managers

  <https://doi.org/10.56238/devopinterscie-279>

Izabel C D Piva

Student of the Professional Master's Degree in Radiological Protection of the Federal Institute of Education, Science and Technology of Santa Catarina (IFSC)
E-mail: izacrf@gmail.com

Geórgia Gonçalves

Student of the Professional Master's Degree in Radiological Protection of the Federal Institute of Education, Science and Technology of Santa Catarina (IFSC)
E-mail: trgeorgiagoncalves@gmail.com

Juliana de Almeida Coelho de Melo

Professor of the Professional Master's Degree in Radiological Protection of the Federal Institute of Education, Science and Technology of Santa Catarina (IFSC)
E-mail: julianac@ifsc.edu.br

Andrea Huhn

Professor of the Professional Master's Degree in Radiological Protection of the Federal Institute of Education, Science and Technology of Santa Catarina (IFSC)
E-mail: andreahuhn@ifsc.edu.br

ABSTRACT

Introduction: Mammography is the gold standard for diagnosis of breast cancer, a good positioning guarantees a more accurate diagnosis, being in most cases a great challenge for the professionals of the radiological techniques. The implementation of a clinical quality control program helps to create strategies to minimize nonconformities caused by positioning errors. **Objective:** To analyze how the implantation of clinical quality control in

mammography occurred and what were the results referring to the positioning in the period from 2014 to 2016. **Methodology:** This was a mixed approach of an applied nature. The data were collected from February to April 2019, in the database of the radiodiagnosis service and through an interview with the coordinator of the service and the radiologist. **Results:** Since the implantation of the clinical quality control program were found several challenges among them to change the positioning culture, self-evaluation criteria, the main challenge of professionals and managers is to maintain the quality standard of mammographic images. In the period from 2014 to 2016, 8,500 mammography examinations were evaluated and 13,827 nonconformities were found, distributed between the following incidences: caudal skull and lateral oblique lateral. The most evident nonconformities are related to the absence of the pectoralis major in the caudal cranial incidence with the greatest number of errors, being present in 65.6% of the mammographic images. Then the pectoral muscle at the nipple height with 32.7% and pectoral muscle contracted with 21.7% at the oblique mediolateral incidence. **Conclusion:** The clinical quality control program is an excellent strategy to identify routine errors for a more accurate diagnosis. With continuous training of radiology professionals, the program can be even more effective.

Keywords: Mammography, Quality control, Positioning, Diagnostic imaging

1 INTRODUCTION

Mammography is the most effective diagnostic imaging test for the diagnosis of breast cancer, aiming to produce images with an optimal standard of quality for more reliable diagnoses (CALDAS *et al.*, 2004). Currently, many protocols and tests are updated as to the practical technique applied. Several studies

correlate the final quality of the exam with the practice performed by the professional, considering the importance of the quality of the mammography image.

Breast cancer screening and early detection implementation programs are increasingly improving to implement quality standards in mammography.

Maintaining the quality standard of mammographic images is one of the most important goals for a radio diagnostic service. Learning to recognize the specific nonconformities of the breasts and their probable causes in the images is of great importance for the professionals of radiological techniques and the radiologist. The clinical evaluation of the final mammography image involves clinical quality criteria on: noise, contrast, artifact, positioning, identification, exposure and compression (SABINO, 2014).

The quality of the image in mammography is something that is in constant improvement and directly related to the chance of finding some anatomical alteration, each step of the process of examinations is important for the diagnosis, to reduce the chances of occurring tests with false positives or false negatives it is necessary to perform controls of effective quality. A broad concept of quality control in mammography means observing whether the performance of the equipment, the radiographic techniques for the positioning, and the exposure of the breast are about the established criteria (ARAÚJO *et al.*, 2017).

Mammography requires high image quality to enable the visualization of all breast tissue, thus facilitating a correct and adequate diagnosis, for this needs to be performed the quality control of the device, is a legal obligation. It is important to point out that there are current laws that define strict standards and pre-established, in which the personnel involved in the image acquisition process are effectively prepared and the material and equipment used are adequate (CALDAS *et al.*, 2005).

The legislation in force in Brazil, Resolution RDC No. 611, of March 9, 2022 has in parallel the Normative Instruction No. 92/2021, have the objective of maintaining the quality in mammography, determining for all types of mammography equipment the technical quality control tests that must be performed for the evaluation of the quality of mammographic images, daily, monthly, acceptance tests and after repairs.

Thus, Kopans (2000) states that the problems in the quality of mammography are not only related to inadequate equipment, but also to the incorrect imaging technique and the lack of specialized training for professionals of radiological techniques and radiologists.

Clinical quality control in mammography is still very subjective, at the national level there is Ordinance 2,898 of November 28, 2013 that determines quality criteria of mammographic positioning, but for accrediting quality assurance the Brazilian College of Radiology and Diagnostic Imaging (CBR) uses the criteria determined by the *European Guidelines*.

The National Cancer Institute (INCA) in partnership with CBR and the National Health Surveillance Agency (ANVISA) developed a pilot project, Mammography Quality Program to ensure the quality control of mammograms in 2006 and 2007, which identified the need for continuous quality control throughout the national territory, this project was used to develop the National Mammography Quality Program (PNQM)

in 2012.

The PNQM reflects the need for standardization and monitoring of these exams at the national level and indicates the path to be followed in the coming years to improve the image quality of breast exams offered to the population, a path in which sanitary surveillance has a primary role, alongside other organisms, and which is located in the scope of health care (VILLAR, 2015). To maintain a high standard of images and report, some requirements for clinical imaging are defined, such as, for example, in the caudal skull image, symmetrical breasts, muscle

pectoral, retromammary fat, papilla parallel to the film; and in the oblique mediolateral view the breasts should be symmetrical, inframammary fold, retromammary fat, breast papilla parallel to the film. It is observed that the criteria are related to positioning, with this, Taplin *et al.* (2002) state that the issue of noise quality, contrast and sharpness has been improved over time and that the importance of image quality is now emphasized in positioning. Majid *et al.* (2003) emphasize that positioning can improve the accuracy of image interpretation.

It is known that the topic of clinical quality control in mammography is still very subjective. Therefore, it is of paramount importance to analyze how the implementation of clinical quality control in mammography occurred and what were the results regarding the positioning in the period from 2014 to 2016.

2 METHODOLOGY

This is mixed-approach research of an applied nature, aimed at analyzing how the implementation of clinical quality control in mammography, referring to positioning, occurred in a radio diagnostic service.

Data collection was carried out from February to April 2019, through interviews with the coordinator of the sector and a radiologist, as well as data collection through mammographic examinations.

The information regarding the settlements related to mammography exams was in the database, arranged in spreadsheets related to the 32 months, with data based on clinical quality control, which contained the requirements used for endorsement of the checklist method, lateral portion, medial portion, profiled nipple, pectoral muscle, relaxed pectoral muscle, the pectoral muscle at nipple height, folds in the skin, folds in the skin of the armpit, symmetry, visualization of all tissue, pectoris minor muscle, inframammary fold; they also contained the incidence performed, month and year of the examination.

After data collection, the interviews were transcribed and analyzed. On the other hand, the settlement data related to mammography exams were organized in the IBM SPSS software and transformed into graphs for better visualization.

The research was approved by the Ethics Committee on Research with Human Beings under the opinion 3.065.845.

3 FINDINGS

The idea of implementing clinical quality control in the service arose after the coordinator of the mammography sector conducted a training course in mammography at the Hospital do Amor in Barretos/SP in 2014. In the service, there were many complaints from the physicians, arguments, and a high rate of recall related to mammography exams. Given the situation, the need arose for the implementation of the clinical quality control program, which was monitored by a multidisciplinary team, consisting of a radiologist and the coordinator of the mammography sector, which is part of the group of radiology techniques of the sector, responsible for the evaluation of the items of clinical quality control and training of the professionals submitted to the program.

According to Sabino, Watanabe and Vieira are the responsibility of the radiologist:

To adapt and enable mechanisms associated with a high standard of imaging, assisting in the improvement of the process related to this outcome, refusing the acceptance of mammograms with an inappropriate standard of quality and suggesting the repetition of the examination. (SABINO; WATANABE; VIEIRA, 2013, p. 33-34).

Enhancement is a developed skill and tends to be reinforced through continued knowledge and self-improvement (HUPPE *et al.*, 2017). The implementation of clinical quality control in the radio-agnostic service began in May 2014, to improve positioning techniques and reduce non-conformities in mammographic images. Pires, Medeiros and Schiabel (2003) report the main importance of a correct positioning, which allows all breast tissue to be radiographed, to ensure the detectability of minute structures and identify structures suspected of malignancy. Thus, unnecessary radiation exposures and discomfort of performing the test, as well as the probability of false positive and false negative tests were monitored.

5 radiology techniques participated in the quality control program, with an average of twelve years of experience in the mammography area. The screening mammography exams performed at the radiodiagnostic service by these professionals were followed from 2014 to 2016.

The selected exams were performed in digital equipment (RD and CR), randomly chosen, among those that were performed in the current month. For this control, breast examinations with breast prostheses, mammoplasty, conservative surgeries and mastectomy were excluded.

To evaluate the images, spreadsheets prepared in Microsoft Excel software were used with the clinical evaluation criteria that were proposed in the mammography training course, the *checklist* method, as shown in Chart 1; to assist in the counts of nonconformities, each item found erroneously in the image was marked.

The checklist method proposed by the mammography training course was based on the criteria of the *American College of Radiology (ACR)* and *European Guidelines* of 2006. The service chose not to account for the nonconformities bucky low and breast pendulum, these items cause other nonconformities to happen, staying only as a criterion of observation of the process.

Table 1- Checklist method

INCIDÊNCIA	NÃO CONFORMIDADE
Crânio caudal	Papila mamária perfilada
	Visualização da porção lateral
	Visualização da porção medial
	Presença do músculo peitoral
	Ausência de dobras na pele
	Simetria
<u>Mediolateral oblíqua</u>	Papila mamária perfilada
	Visualização de todo tecido mamário
	Músculo peitoral na altura da papila mamária
	Músculo peitoral relaxado
	Ausência do músculo peitoral menor
	Ausência de dobras na pele
	Ausência de dobras na pele axilar
	Visualização da prega inframamário
	Simetria

Source: Adapted from Sabino (2014)

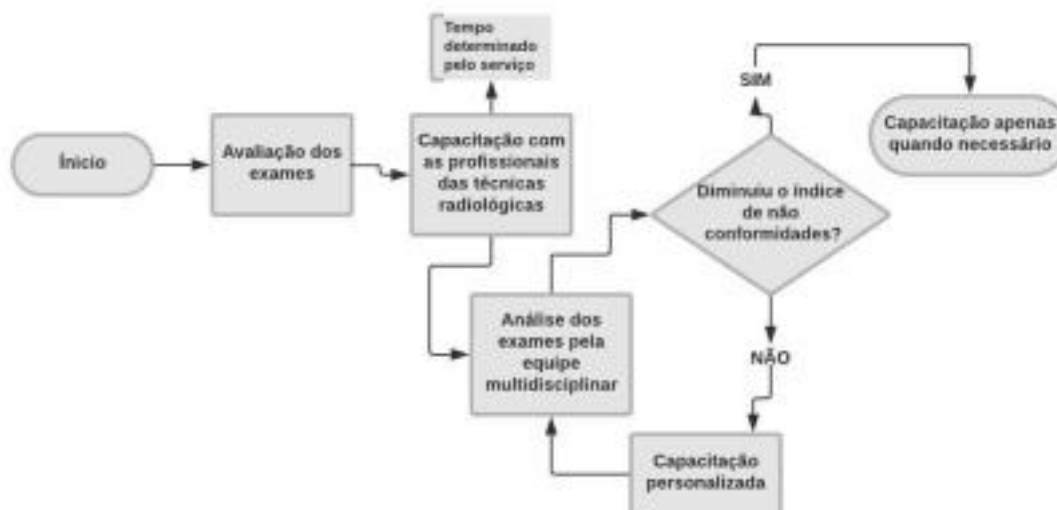
The only study found in the virtual research databases that refers to the implementation of the clinical quality control program was by Sabino (2014), who taught the mammography training course at the Hospital do Amor in Barretos/SP, using the same criteria for evaluating positioning.

The first stage of this implementation began with the evaluation of some mammographic exams performed in the sector, in May 2014, which preceded the training of the professionals of the radiological techniques of the service to evaluate the strengths of each one and where they should improve. After this first evaluation, the second stage of the process took place, where the coordinator of the mammography sector conducted previous training with all the professionals of the radiological techniques that worked in the sector to better adjust the positioning in the mammographic exams.

In the third stage, already with the improvement of the techniques, the training was occurring more sporadically according to the needs of each professional observed in the monthly evaluations. From there, personalized corrective actions were proposed to observe improvements in the next evaluations. The evaluations of the mammographic examinations performed at the radiodiagnostic service occurred monthly until December 2016. After this period, the evaluations of the exams were at the discretion of the of the radiologists of the service.

The flowchart (Figure 1) was produced and followed as the base method for the production of its methodology and development of the implementation of clinical quality control.

Figure 1- Flowchart for the implementation of clinical quality control



Source: From the author (2019)

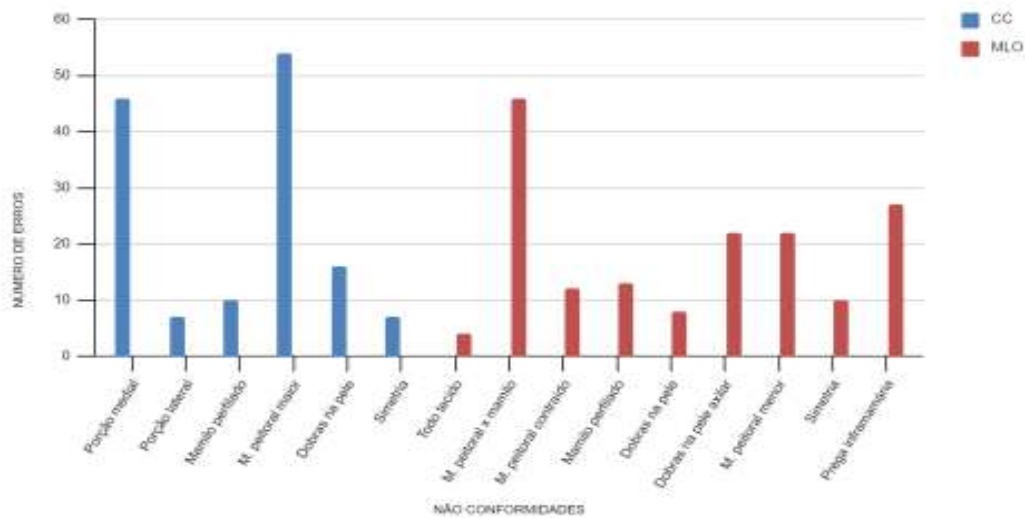
The evolution of nonconformities in the process of implementation of clinical quality control in mammography

During the implementation of clinical quality control in the radiodiagnosis service, 8,500 mammographic exams were evaluated, analyzing the nonconformities caused by the patient's poor positioning. In the evaluated exams, 13.827 nonconformities were found, distributed among the incidences: caudal skull and oblique lateral middle. Non-conformities in craniocaudal view correspond to 48.2% and in oblique mediolateral view 51.7%.

In the pre-training evaluation, in May 2014, 100 examinations of each professional participating in the research were evaluated, in which the oblique mediolateral incidence presented the highest number of non-conformities. In the craniocaudal incidence,

Nonconformities were scored the medial portion (32.8%) and the absence of the pectoralis major muscle (38.5%). In the oblique mediolateral, the pectoral muscle at nipple level (28.0%) and inframammary fold (16.4%) presented a higher rate of presence, obtaining the same number of nonconformities in folds in the skin of the armpit and pectoralis minor muscle (13.4%), as shown in Figure 2.

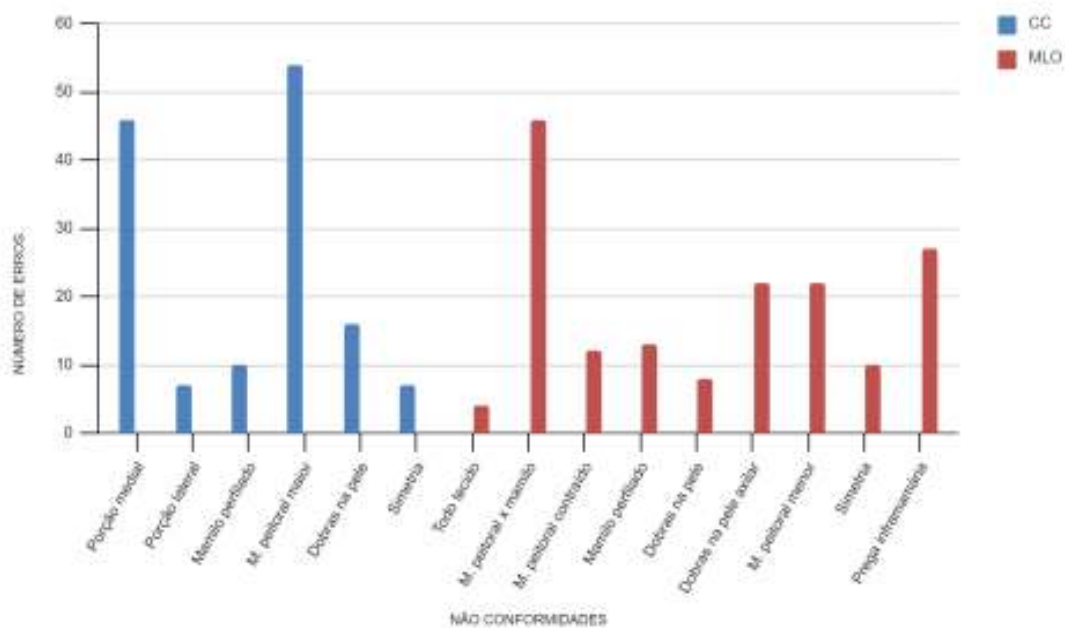
Figure 2 - Distribution of the number of nonconformities before the implementation of clinical quality control - May/2014



Fonte: Database (2019)

In the 900 examinations evaluated during the training period, between June and August 2014, the highest number of nonconformities occurred in the craniocaudal incidence 1,002 (77%) and in the oblique mediolateral view 858 (66%). In this phase, the pectoralis major muscle was also highlighted with 53.4% and then the medial portion with 18.5% of the nonconformities. On the other hand, in the oblique mediolateral view, there was a decrease in the number of nonconformities, pectoral muscle at nipple height with 28.7% and inframamarian fold with 15.7%. Only the contracted pectoral muscle presented an increase, representing 25.4% of the numbers of nonconformities, as shown in Figure 3.

Figure 3 - Distribution of nonconformities during training – June-August/2014



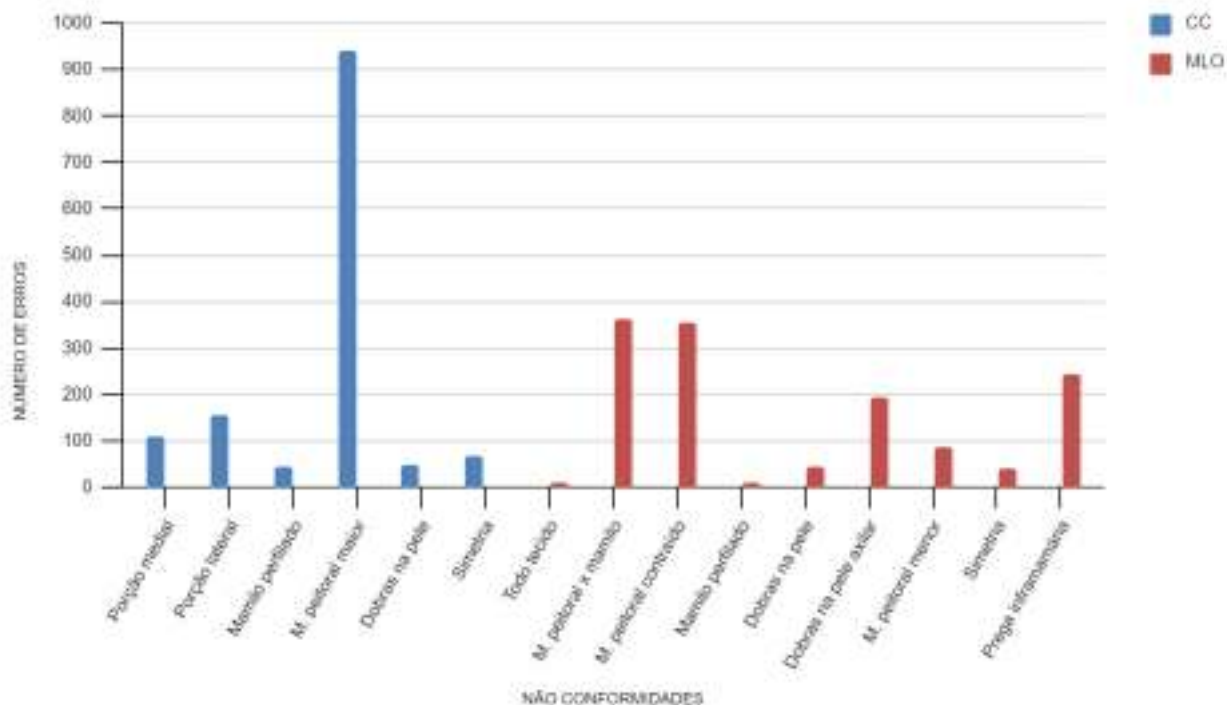
Source: Database (2019)

The positioning criteria can be improved despite the challenges encountered. A standardized positioning of techniques in mammography exams improves image quality. The professionals were trained according to the standardized positioning techniques and also received personalized training for the challenges encountered. In this way, the results of mammographic examinations are more consistent, reproducible and more often meet the clinical imaging evaluation criteria (HUPPE et al., 2017).

After the training phase, the non-conformities in the mammographic exams were carefully evaluated and the professionals of the radiological techniques received personalized training with the coordinator according to the need for. Over 28 months, an additional 7,500 tests were evaluated to analyze the evolution of nonconformities over time.

In the last four months (September to December) of the year 2014, in the 1,850 mammographic exams evaluated, 2,781 nonconformities were found in the images. In the images of the craniocaudal view, the pectoralis major muscle remained with a high rate of number of errors (68.9%), and the lateral portion presented with 11.4%. The oblique mediolateral incidence presented higher indices in the nipple height pectoral muscle (30.4%); contracted pectoral muscle (25%); inframammary fold (17.2%) and folds in the axillary skin (13.6%), that is, there was a significant increase in nonconformities, according to Figure 4.

Figure 4-Distribution of the number of nonconformities after training – September to December/2014

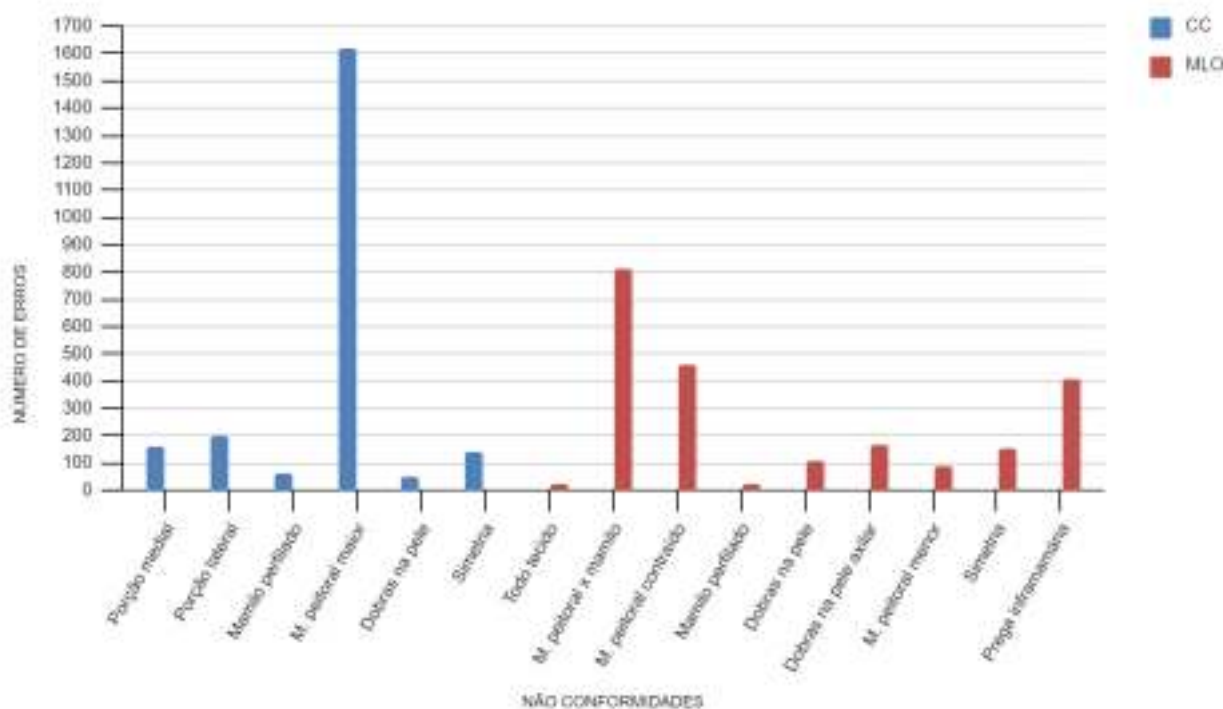


Source: Database (2019)

In 2015, more than 3,000 tests performed in the sector were evaluated, scoring 4,461 nonconformities, with a higher incidence of errors in the oblique mediolateral images prevailing with a difference of 15 (0.33%) nonconformities. In this year, the non-conformity of the pectoralis major muscle presented itself with 72.8%, the

pectoral muscle at nipple height with 36.8%; pectoral muscle contracted with 20.4% and inframammary fold with 18.2%. The other nonconformities remained with a low number of occurrences (Figure 5).

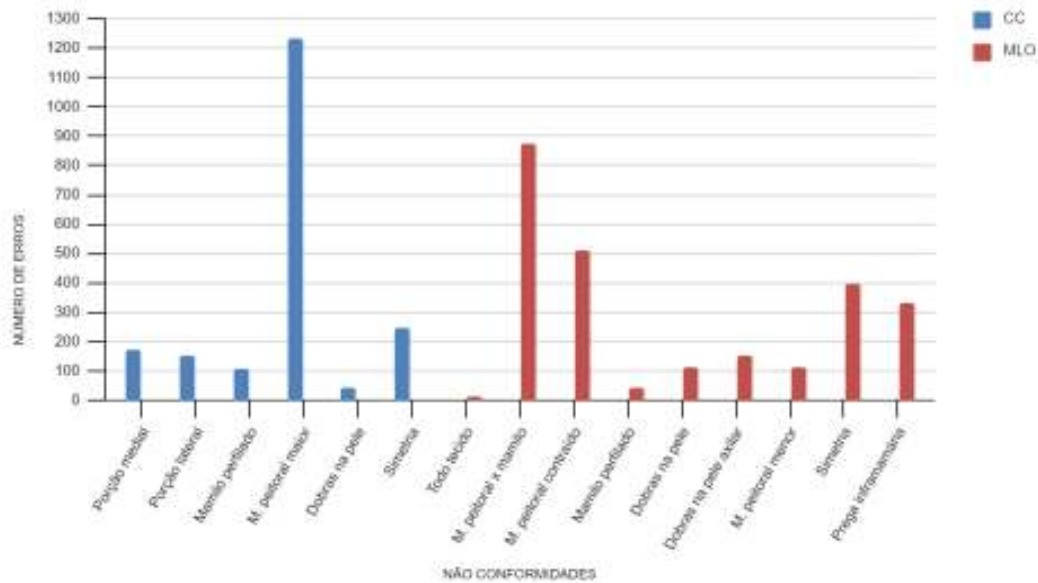
Figure 5- Distribution of nonconformities in 2015



Source: Database (2019)

In 2016, 2,650 mammographic exams were evaluated, finding 4492 numbers of errors, with the majority scoring on the oblique mediolateral incidence with 56.6% of the non-conformities found. It can be observed that the pectoralis major muscle presented again with a higher number of nonconformities (63.1%) in the craniocaudal view. And in the oblique mediolateral view, the pectoral muscle at nipple height presented 34.3%, contracted pectoral muscle was 20.1%. This time, non-compliance appears with a slightly higher index, of 15.4% (Figure 6).

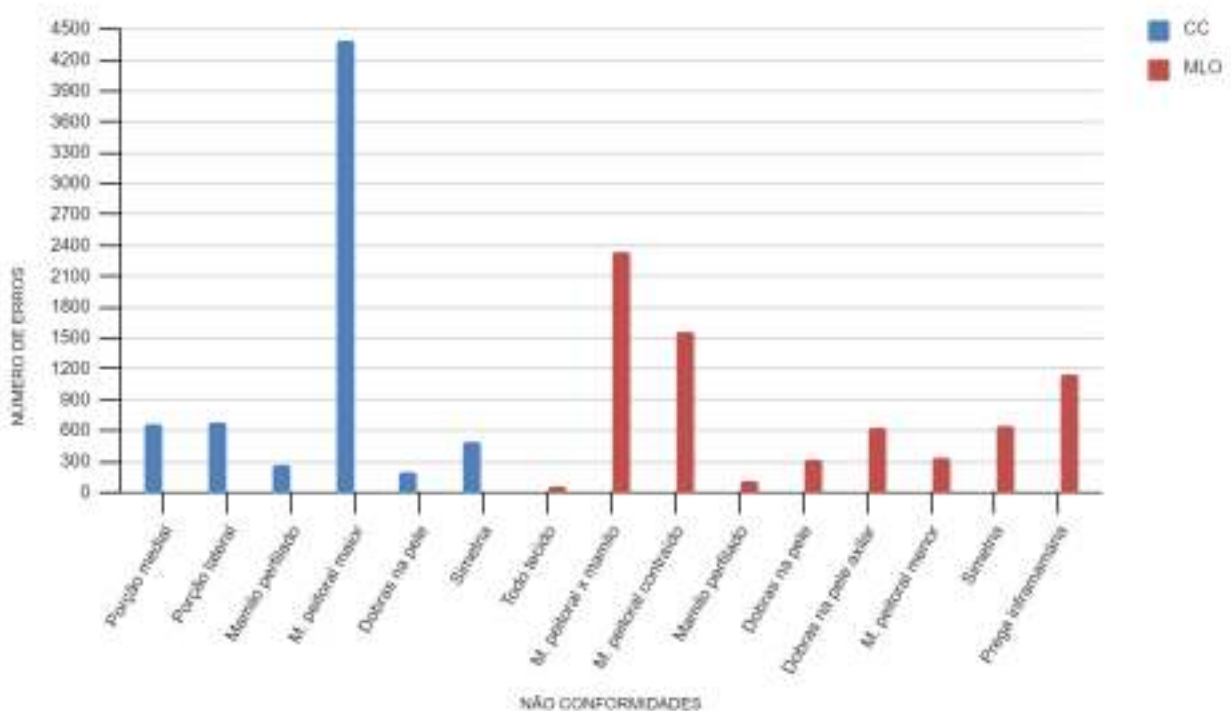
Figure 6- Distribution of the number of nonconformities in 2016



Source: Database (2019)

According to Figure 7, within the scope of the entire process of implementation of the program, it was noted that the absence of the pectoralis major muscle in the craniocaudal view was the non-conformity with the highest number of nonconformities, being present in 65.6% of the mammographic images. Then the pectoral muscle at nipple height with 32.7% and the contracted pectoral muscle at 21.7% in the oblique mediolateral view.

Figure 7-Distribution of the total number of nonconformities collected between 2014 and 2016



Source: Database(2019)

In the study by Sabino (2014), the absence of the pectoralis major musculature in the craniocaudal incidence was the most incident failure, with a total of 33% of the scores. The second most commonly observed non-conformity was the absence of adequate opening of the inframammary angle, which was marked 24% of the time. Inadequate positioning of the pectoral above the line of the mammary papilla was identified in 14.2% of the examinations, being the third most frequent nonconformity.

In general, it was observed that during the entire period of implementation of the clinical quality program and evaluation of the images, all nonconformities had a variation in the number of errors throughout the implementation process, some obtaining significant improvement and others presenting few improvements (Table 2).

Table 2 – Evolution of nonconformities in the process of implementing clinical quality control in mammography between 2014 and 2016

INCIDÊNCIA	NÃO CONFORMIDADES	PERÍODO				
		PRÉ CAPACITAÇÃO	DURANTE CAPACITAÇÃO	PÓS CAPACITAÇÃO		
				2014	2015	2016
Crânio caudal	Dobras na pele	11,4%	4,1%	3,4%	2,1%	2%
	Mamilo perfilado	7,1%	4,1%	3,1%	2,6%	5,5%
	M. peitoral maior	38,5%	53,4%	68,9%	72,8%	63,1%
	Porção medial	32,8%	18,5%	7,9	11,4%	8,7%
	Porção lateral	5%	16,8%	11,4%	8,9%	7,7%
	Simetria	5%	2,6%	5%	6,1%	12,6%
Mediolateral oblíqua	Dobras na pele	4,8%	4,5%	3,2%	4,9%	4,4%
	Dobras na pele axilar	13,4%	10,7%	14,3%	7,4%	5,9%
	Mamilo perfilado	7,9%	2,4%	0,1%	0,9%	1,6%
	M. peitoral contraído	7,3%	25,4%	26,2%	20,4%	20,1%
	M. peitoral menor	13,4%	3,4%	6,5%	3,9%	4,4%
	M. peitoral x mamilo	28%	28,7%	26,8%	36,2%	34,3%
	Simetria	6%	6,5%	3,1%	6,8%	15,4%
	Todo tecido	2,4%	2,3%	0,6%	0,9%	0,5%
Prega inframamária	16,4%	15,7%	18,1%	18,2%	12,9%	

Fonte: Banco de dados (2019)

Ordinance 2,898 of 2013 of the Ministry of Health states that in the craniocaudal incidence, "the pectoral muscle should be seen in about 30% (thirty percent) of the examinations", on the other hand, the *European Guidelines* (2006) informs that this requirement must be observed in 52% of mammographic examinations. The absence of the pectoralis major muscle in the incidence indicates poor positioning (INCA, 2018); with variable patients and equipment, it is not surprising that positioning continues to be seen as a challenge to quality and mammographic practice (SWEENEY et al., 2017).

The positioning aims to demonstrate the pectoral muscle in the craniocaudal view to provide a key image quality criterion to confirm the

inclusion of posterior breast tissue (SWEENEY et al., 2017). Failure to obtain adequate mammographic positioning can result in tissue exclusion and, consequently, loss of lesions (HUPPE et al., 2017).

In the mediolateral view, the inframammary fold should be included in every image, pulled up and out, to open the fold and ensure that the base of the breast and the upper abdomen are not overlapped (KOCK et al. 2004).

Kopan (2000, p. 3) indicates that the oblique mediolateral projection is positioned so that the compression plane is parallel to the oblique fibers of the free margin of the muscle. This allows maximum traction on the breast so that it can be positioned over the detector and comfortably compressed.

The author also states that: "It is important that the patient is instructed to relax the shoulders as much as possible, to avoid tension in the pectoral muscles, because this reduces the amount of tissue that can be included in the image" (KOPAN, 2000 p. 176)

Generally, the most lateral and upper portions of the breast should be reproduced through the pectoralis major muscle, so it should be included in the MLO image to ensure correct positioning.

Challenges encountered during the implementation of clinical quality control by professionals and managers

Through interviews, the coordinator of the sector and the radiologist responsible for the implementation of clinical quality control reported that during the implementation of quality control of clinicians, several challenges were encountered by professionals and managers.

One of the first challenges encountered was the development of training for the sector since there was no standard protocol for training the professionals or the step-by-step for this implementation. The coordinator of the sector and the radiologist had to adapt the methods presented in the training course. Thus, they developed tools for the evaluation of the professionals and adapted schedules for training, so that it did not interfere with the schedule of the radiodiagnosis service.

In the interview, the professionals reported that:

"One of the challenges was to change the conception of image quality of the techniques, we had a standard, and changing this vision was a great challenge, you learn to visualize the images again, evaluate what is more important, make understand the need for training because we had techniques with more than 15 years of the profession [...], To teach them to self-assess, to have that critical power to be able to self-assess, to learn how to do the checklist on every exam that you take." (E1)
"The biggest challenge was about the technical staff was to make them understand that with quality control we will do better tests and with this will improve our diagnosis." (E2)

Other challenges were also emphasized by the professionals interviewed, such as: showing the importance of the implementation of clinical quality control and the training of professionals. Emphasize self-assessment and change in the way of evaluating the quality of mammographic images; adaptation of the schedules for the training of the professionals; understanding that the rhythm of the exams would be modified until the professionals adapted to the changes in positioning and the performance of the checklist in each exam.

Regarding the large number of nonconformities related to the pectoral muscle, it was reported in the interview that:

"At the time they are not present there is no certainty that every breast has been included in the examination. And also when the pectoral muscle is not relaxed, it means that the patient was also not relaxed and this causes the thickness of the breast to be larger, [...] and with this, you have greater difficulty in diagnosing small lesions." (E2)

4 FINAL CONSIDERATIONS

Maintaining the quality standard of mammographic images is one of the most important goals for a radio diagnostic service. Learning to recognize the specific nonconformities of the breasts and their probable causes in the images is of great importance to the professionals of radiological techniques and radiologists.

The implementation of clinical quality control in the diagnostic imaging service began in May 2014, intending to improve the techniques of

positioning and reduce nonconformities in mammographic images. Thus, the necessary exposure o radiation and the discomfort of the examination, as well as the probability of false positive and false negative tests were monitored.

The screening mammography exams performed at the clinic by these professionals were followed from 2014 to 2016. Throughout the process of implementation of the quality control program in the radio diagnostic service, it was evident in the images evaluated that the absence of the pectoralis major muscle in the craniocaudal view was the non-compliance with the highest number of nonconformities, being present in 65.6% of the mammographic images evaluated. Following the pectoral muscle at nipple height with 32.7% and the contracted pectoral muscle with 21.7% in the oblique mediolateral view.

The radiodiagnosis service has the necessary infrastructure and qualified workforce to adhere to the changes implemented in the clinical quality control of mammography, and it is necessary to carry out specialized training more frequently to further guarantee a decrease in the number of nonconformities. The main nonconformities that occurred were the absence of the pectoralis major muscle, the pectoral muscle at nipple height, and the contracted pectoral muscle. contributing to a lower rate of test repetitions, the psychological distress of patients, and the economy of inputs.

The results showed that since the implementation of the clinical quality control program in the radiodiagnosis service, several challenges have been present, such as: developing training for the sector and evaluation tools for professionals; showing the importance of implementing clinical quality control and training of professionals; emphasizing self-assessment and the change in the way of assessing the quality of mammographic images; adaptation of schedules for professional training; understanding that the rhythm of the exams would be modified until the professionals adapted to the changes in positioning and the performance of the checklist in each exam.

The main challenge of professionals and managers is to maintain the quality standard of mammographic images. In this case, improving the technique of performing the

mammographic exams and maintaining a good positioning technique favors the reduction of false positive and false negative tests. Adaptations and improvements are always necessary, through more rigorous clinical quality control and training of professionals in radiological techniques.

It is suggested for future studies perform new evaluations of mammographic examinations to perform the analysis of the effectiveness of the program and; Development of a standard protocol for the evaluation of mammographic images. And conducting clinical quality control studies for breasts with breast prostheses.

REFERENCES

- ARAÚJO, Anna Maria Campos de et al. O Controle de Qualidade em Mamografia e o INCA: Aspectos Históricos e Resultados. **Revista Brasileira de Cancerologia**, [s.l.], v. 63, n. 3, p.165-175, 18 set. 2017. Disponível em: <http://www.inca.gov.br/rbc/n_63/v03/pdf/02-artigo-o-controle-de-qualidade-em-mamografi-a-e-o-INCA-aspectos-historicos-e-resultados.pdf> Acesso em: 01 de junho de 2019
- BRASIL.(2021) Instrução Normativa - **In N° 92, de 27 de Maio de 2021**. Disponível em: <https://www.in.gov.br/en/web/dou/-/instrucao-normativa-in-n-92-de-27-de-maio-de-2021-322985226>. Acesso em: 05 set. 2022.
- BRASIL. Constituição (2012). **Portaria nº 2.898, de 28 de novembro de 2013**. Atualiza o Programa Nacional de Qualidade em Mamografia (PNQM).Portaria N° 2.898, de 28 de Novembro de 2013. Brasil: Ministério da Saúde
- BRASIL. Constituição (2022). Resolução nº 611, de 09 de março de 2022. **Resolução Rdc N° 611, de 9 de Março de 2022**. [S,I],
- CALDAS, Flávio Augusto Ataliba et al. **Controle de qualidade e artefatos em mamografia. Radiologia Brasileira**, [s.l.], v. 38, n. 4, p.295-300, ago. 2005. FapUNIFESP (SciELO). <http://dx.doi.org/10.1590/s0100-39842005000400012>. Disponível em: <http://www.scielo.br/scielo.php?pid=S0100-39842005000400012&script=sci_abstract&tln g=pt>. Acesso em: 01 de junho de 2019
- HUPPE, Ashley I. et al. Mammography Positioning Standards in the Digital Era: Is the Status Quo Acceptable?. **American Journal Of Roentgenology**, [s.l.], v. 209, n. 6, p.1419-1425, dez. 2017. American Roentgen Ray Society.
- INCA. Instituto Nacional do Câncer José Alencar Gomes da Silva. Ministério da Saúde (Ed) **Atualização em mamografia: Para técnicos em radiologia**. Rio de Janeiro (RJ): Serviço de Educação e Informação Técnico-científica Área de Edição e Produção de Materiais Técnico-científicos, 2018. 181 p.
- INCA. Instituto Nacional do Câncer José Alencar Gomes da Silva. Ministério da Saúde (Ed.). Controle do câncer de mama: Qualidade em mamografia.,2014 Disponível em: <http://www2.inca.gov.br/wps/wcm/connect/acoes_programas/site/home/nobrasil/programa_controle_cancer_mama/qualidade_mamografia> Acesso em: 01 de junho de 2019
- KOCK, Hilton Augusto et al (Ed.).**Programa para treinamento em mamografia**. São Paulo: Colégio Brasileiro de Radiologia e Diagnóstico Por Imagem, 2004
- KOPANS, Daniel B.. **Imagem da mama**.2. ed. Rio de Janeiro: Médica Científica Ltda, 2000. 851 p.
- MAJID, Aneesa S. et al. **Missed Breast Carcinoma: Pitfalls and Pearls. Radiographics**, EUA, v. 4, n. 23, p.881-895, 2003
- SABINO, Silvia Maria Prioli de Souza; WATANABE, Ana Paula Hidemi Uema; VIEIRA, René Aloisio da Costa. Qualidade do exame de mamografia em rastreamento mamográfico. **Revista Brasileira de Mastologia**, Rio de Janeiro, v. 2, n. 23, p.31-35, nov. 2013
- SABINO, Silvia Maria Prioli de Souza. Implantação de um programa de controle de qualidade clínico da mamografia: análise da efetividade em um programa de rastreamento mamográfico. 2014. 54 f. Dissertação (Mestrado) - Curso de Oncologia, Programa de Pós – Graduação da Fundação Pio XII – Hospital de Câncer de Barretos, Barretos/ SP, 2014. Disponível em: <<https://www.hcancerbarretos.com.br/upload/doc/dissertacao.silvia.pdf>>. Acesso em: 10 de maio de 2019.

SABINO, Silvia M. Prioli de Souza. **Programa de Controle de Qualidade Clínico da Imagem Mamográfica**. Barretos: Núcleo de Mamografia Aperfeiçoamento, 2014. Color.

SWEENEY, Rhonda-joy I et al. A review of mammographic positioning image quality criteria for the craniocaudal projection. **The British Journal Of Radiology**, [s.l.], p.1-9, 5 dez. 2017. British Institute of Radiology.

TAPLIN, Stephen H. et al. Screening Mammography: Clinical Image Quality and the Risk of Interval Breast Cancer. **American Journal Of Roentgenology**. Estados Unidos, p. 797-803. abril/ 2002

PIRES, Silvio Ricardo; MEDEIROS, Regina Bitelli; SCHIABEL, Homero. Banco de imagens mamográficas para treinamento na interpretação de imagens digitais. **Radiologia Brasileira**, [s.l.], v. 37, n. 4, p.239-244, ago. 2004.

VILLAR, Vanessa Cristina Felipe Lopes et al. Evolution of mammographic image quality in the state of Rio de Janeiro. **Radiologia Brasileira**, [s.l.], v. 48, n. 2, p.86-92, abr. 2015. FapUNIFESP (SciELO). <http://dx.doi.org/10.1590/0100-3984.2014.0047> Acesso em: 01 de junho de 2019.