 <https://doi.org/10.56238/alookdevelopv1-007>

Carolina Bandeira Domiciano

ORCID: <https://orcid.org/0000-0001-6653-9795>
Carolina Bandeira Institute of Minimally Invasive Surgery, Brazil
E-mail: bandeiracarolina@hotmail.com

Aníbal Costa Filho

ORCID: <https://orcid.org/0000-0001-7388-9638>
Unineves College, Brazil
E-mail: costafilhomd@yahoo.com.br

Geraldo Camilo Neto

ORCID: <https://orcid.org/0000-0003-2336-2285>
Carolina Bandeira Institute of Minimally Invasive Surgery, Brazil
E-mail: geraldocamiloneto@hotmail.com

Daniel Hortiz de Carvalho Nobre Felipe

ORCID: <https://orcid.org/0000-0002-2227-8244>
Carolina Bandeira Institute of Minimally Invasive Surgery, Brazil
E-mail: danielhortiz@gmail.com

Ana Cecília Maia

ORCID: <https://orcid.org/0000-0003-2869-3534>
Carolina Bandeira Institute of Minimally Invasive Surgery, Brazil
E-mail: ceciliamaia85@gmail.com

Deborah Cristina Nascimento de Oliveira

ORCID: <https://orcid.org/0000-0002-0285-8890> Nova Esperança Medical School, Brazil
E-mail: debmedfamene@outlook.com

Bianca Vasconcelos Braga Cavalcante

ORCID: <https://orcid.org/0000-0001-9324-8301>
Nova Esperança Medical School, Brazil
E-mail: biancavbraga@gmail.com

Ana Júlia de Lima Medeiros Pereira

ORCID: <https://orcid.org/0000-0003-0763-2505> Nova Esperança Medical School, Brazil
E-mail: anajulialmpereira@gmail.com

Marina Crispim Sarmento

ORCID: <https://orcid.org/0000-0003-3230-5880>
Nova Esperança Medical School, Brazil
E-mail: sarmentomc2001@gmail.com

ABSTRACT

Introduction: Thoracic involvement accounts for the most prevalent extrapelvic presentation of endometriosis, with the diaphragm being the region most affected by the disease. A variety of symptoms are cited in the literature, with the catamenial factor being the main differential finding of these manifestations. **Objective:** The purpose of this article is to describe the social impact of diaphragmatic endometriosis on the lives of patients and to discuss the description of endometriosis surgery. **Methodology:** The present study is based on a literature review based on articles selected by the criteria of relevance and up-to-dateness inserted in a scientific database. **Results:** The first report of endometriosis involving the lung parenchyma was described in 1938 by Schwarz, while in 1958 there was the first report of catamenial pneumothorax by Maurer et al. Pelvic and transvaginal ultrasound with bowel preparation and magnetic resonance imaging (MRI) with specialized protocols are the main imaging methods for detecting and staging endometriosis. **Conclusion:** Surgical treatment is the only curative method, and the minimally invasive route should be the choice given the lower risks of contamination, better healing, and complete rehabilitation of the patient in a shorter period if laparotomy were performed. It is worth noting that the patient needs a multidisciplinary approach aiming at a complete recovery and the return to daily activities as soon as possible.

Keywords: Pleural effusion, diaphragm, Endometriosis, Hemothorax, Pneumothorax.

1 INTRODUCTION

Endometriosis is a benign pathology defined by the presence of ectopic endometrial cells (glands and stroma) outside the uterine cavity and affects up to 12% of female patients (Soares et al,

2021); (Rousset et al, 2014), although other studies indicate that the incidence is even higher (Nezhat et al., 2019).

The most frequently involved site is the pelvis. However, although rare, it can also affect extrapelvic sites, with the thoracic cavity being the most common extrapelvic location. (Soares et al, 2021). The forms of thoracic involvement usually attack the parietal and visceral pleura, lung, and diaphragm, the latter being responsible for 1.5% of the causes of endometriosis (Vitti et al, 2019); (Soniro, et al., 2020); (Gil & Tulandi, 2020).

Collectively, the involvement of all these regions is called Thoracic Endometriosis Syndrome, producing a series of clinical and radiological manifestations, which include: catamenial pneumothorax, catamenial hemothorax, catamenial hemoptysis and pulmonary nodules (Nezhat et al., 2019).

This article aims to describe the social impact of diaphragmatic endometriosis on patients' lives and discuss the description of endometriosis surgery.

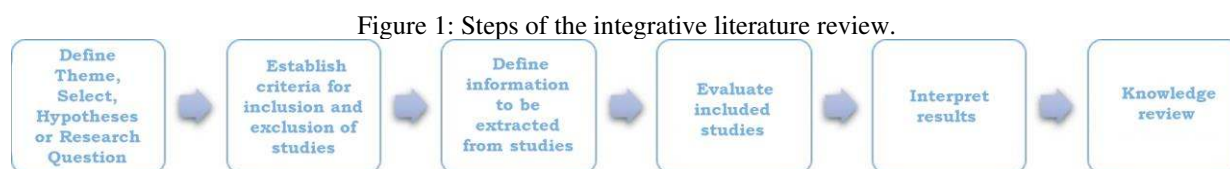
2 METHODOLOGY

The present study is based on an integrative review (IR) with a qualitative method approach, which aims to direct the development of studies for a better understanding of the facts (Proetti, 2018). The integrative review is a broader methodological approach, which incorporates several purposes, such as the definition of concepts, review of theories, and analysis of methodological problems of a particular topic (Souza, Silva & Carvalho, 2010).

The research was carried out through searches in the following databases: PubMed; Virtual Health Library (VHL); Scientific Electronic Library Online (SciELO) and Google Scholar, published in the last 10 years, based on the use of Health Descriptors (DeSC) in Portuguese "Pleural effusion"; "Diaphragm"; "Endometriosis"; "Hemothorax"; "Spontaneous pneumothorax" and in the English language "Diaphragm"; "Endometriosis"; "Hemothorax"; "Pneumothorax."; "Pleural Effusion" in a single or combined form. In addition, selection criteria, namely: articles in Portuguese and English; full texts available free of charge; were adopted to aggregate and delimit only those articles that fall within the scope of Diaphragmatic Endometriosis.

Based on the aforementioned descriptors, we found (2) in Pubmed, (3) in VHL, (5) in ScieELO, and (29) in Google Academic. Systematic literature reviews and meta-analyses were added to literature reviews and case reports that covered the theme addressed for the research. Exclusion criteria included books, monographs, theses and abstracts of annals. Through these criteria, 25 articles were included in the sample and after the complete reading, 23 articles were included in the literature review.

Casarin et al. (2020) state that IR aims to unify the findings of empirical and theoretical works, allowing the elaboration of results for the deepening and understanding of a singular phenomenon concerning the epidemiological affiliation of the covered works. To carry out the IR, it is necessary to go through the following steps, as exemplified in Figure 1.



Source: Adapted from Casarin et al. (2020).

3 RESULTS AND DISCUSSION

The first report of endometriosis involving the lung parenchyma was described in 1938 by Schwarz (Marjański, 2016), while in 1958 there was the first report of catamenial pneumothorax made by Maurer (Soares, et al, 2021); (Furuta, et al., 2018).

Since then, one of the main theories for the occurrence of extrapelvic endometriosis is retrograde menstruation, where the menstrual flow would follow the path of the right parietocolic trough and falciform ligament, where it would accumulate in the right subdiaphragmatic space (Vitti, et al, 2019).

The adhesive capacity of endometrial cells would eventually infiltrate the diaphragm, resulting in single or grouped lesions in the form of small nodules. As the disease develops, these nodules may dissolve, creating micro perforations during each cycle and consequent formation of pneumothorax, diaphragmatic rupture, and herniation of the abdominal contents (Vitti, et al, 2019); (Niwloh, 2011). According to Kolos, et al., (2015), a second hypothesis would be birth defects, such as holes and preexisting fenestrations in the diaphragm through which the disease could permeate (Kolos, et al., 2015).

Kaveh, et al., (2018) state that the average age with which extrapelvic endometriosis has been reported is around 35-40 years, approximately 10 years later than the pelvic form (Kaveh, et al., 2018).

Among symptomatic patients, the main manifestation is shoulder pain or its worsening during the menstrual period. However, the absence of symptoms or their presence outside the menstrual period does not exclude the diagnosis (Soares, et al., 2021). According to the literature, up to 70% of patients will be asymptomatic. When present, such symptoms result mainly from nerve stimulation of the C3-C5 roots, with greater severity depending on the depth at which these structures are affected. Other possible manifestations would be dyspnea, cough, arm pain, neck pain, right upper quadrant pain, pleuritic pain, hemothorax, hemoptysis, and thoracic endometriosis syndrome (Sorino, et al.,

2020).

The so-called catamenial symptoms are defined as those that occur from 24 hours before to 72 hours after the onset of menstruation. The main complications include thoracic endometriosis syndrome, causing catamenial hemothorax, catamenial pneumothorax, and hemoptysis. Recently, 3 more forms of the syndrome were included, including diaphragmatic hernia related to endometriosis, catamenial and pleural chest pain related to endometriosis (Sorino, et al., 2020); (Elia, et al, 2015).

According to Silva, et al (2018), the main and most frequent complication is pneumothorax. Haga, et al (2013) reported that 20-30% of women with spontaneous pneumothorax were recently diagnosed with catamenial pneumothorax (Silva, et al, 2018); (Haga, et al, 2013).

The diagnosis itself is quite obscure since professionals lack clinical suspicion associated with asymptomatic patients for the disease (Sorino, et al., 2020).

Pelvic and transvaginal ultrasound with bowel preparation and magnetic resonance imaging (MRI) with specialized protocols are the main imaging methods for detecting and staging endometriosis. Such tests can increase their sensitivity when performed during the woman's menstrual period (Sorino, et al., 2020).

MRI images capture hyperintense nodules, best seen on fat-suppressed T1-W sequences, with sensitivity between 78% and 83% (Sorino, et al., 2020). Taking this percentage into account, it is possible to state that, although effective, the test has a certain sensitivity limitation for screening, where the results may be false negatives and, therefore, not reveal small lesions. Therefore, the gold standard for the diagnosis of chest endometriosis is video-assisted thoracic surgery (Hirata, et al., 2018).

According to Machairiotis, et al. (2013), the search for biomarkers that help the diagnosis of endometriosis could contribute to cases of diagnostic doubt. Currently, the only one used in clinical practice is CA-125, however, it is not very specific for diagnosis and, in case of a negative result, it does not rule out the disease (Machairiotis, et al., 2013).

Treatment options will depend on the degree of organic dysfunction that the disease may bring (Machairiotis, et al., 2013). Laparoscopic management is the gold standard method for diagnosis and treatment is the gold standard method. The technique consists of leaving the patient in a steep reverse Trendelenburg position, pushing the liver caudally for better visualization and removal of the lesions (Nezhat, et al., 2019). The moment of diagnosis occurs when viewing the endometrial stroma or during immunohistochemistry (Wetzel, et al., 2021).

During the removal of endometriotic foci, hydro section followed by excision or CO2 laser has been identified as being more accurate compared to electrocautery. As for perforating diaphragmatic injuries, the technique used will depend on the size of these holes, with resection with

an endoscopic stapler being the most appropriate approach for small injuries and the use of synthetic mesh for larger injuries. Endometriotic implants in the diaphragm usually have a black, blue, or reddish-purple appearance and their morphology varies between vesicular appearance, fibrotic white lesion, and underlying hepatic adhesions (Nezhat, et al., 2019).

Diagnosis during the surgical procedure can be challenging, as the lesions are sometimes small and may not be identified. In addition, it is sometimes difficult to distinguish the endometrium from stroma and inflammatory cells by staining with hematoxylin and eosin (Hirata, et al., 2018); (Bricelj et al., 2017). However, Nezhat, et al. (2019) reported that thoracic endometriosis was found in the diaphragm (100%), chest wall (64%), and parenchyma (64%) using the video laparoscopy procedure (Nezhat, et al., 2019).

4 SURGICAL DESCRIPTION:

Patient in Horizontal Dorsal Decubitus Under General and Epidural Anesthesia, an umbilical incision is made with dissection by planes until access to the cavity by direct vision. After the dissection, a 10 mm Trocar is passed and the pneumoperitoneum is inflated to a pressure of 12 mmHg. Subsequently, there is the passage of the other trocars by direct vision, namely: 5 mm in the left flank and left iliac fossa. 12 mm in the right iliac fossa. 5mm in the right hypochondrium.

Then the endometriotic plaque lesions on the abdominal surface of the diaphragm are identified. There is a marginal delimitation of diaphragmatic lesions with electrocautery. The diaphragmatic musculature is incised with monopolar energy until a macroscopically free margin is obtained. At points where the disease affects the entire muscle layer, the parietal pleura is excised en bloc next to the surgical specimen.

The part is removed through the 12 mm portal. Hemostasis is performed with advanced bipolar energy forceps. If the parietal pleura is opened, herniorrhaphy is performed with continuous stitches of absorbable POLYGLACTIN 0 thread. Finally, thoracic drainage is not routinely performed, reserved for cases in which the patient presents respiratory distress in the postoperative period.

5 CONCLUSION

Taking these aspects into account, for the correct identification and treatment of diaphragmatic endometriosis and its relationship with possible complications, a detailed and differential clinical evaluation is essential, through a good anamnesis, physical examination, and imaging tests. Thus, patients with refractory, cyclical chest pain of undetermined cause should always be suspected of this disease.

Surgical treatment is the only curative method and the minimally invasive route should be chosen because of the lower risks of contamination, better healing, and complete rehabilitation of the patient in a shorter period if laparotomy were performed. If there is suspicion of involvement of the thoracic cavity, video laparoscopy surgery should be implemented for complete resection of the foci. It is worth noting that the patient needs a multidisciplinary approach aimed at a complete recovery and return to daily activities as soon as possible.

Given the observed aspects, I call for the expansion of research and studies in the field of diaphragmatic endometriosis in the health area, to support the absence of knowledge and studies of extra pelvic endometriosis, on diaphragmatic endometriosis. In this regard, for future research, it is suggested that the relationship between catamenial symptoms, such as spontaneous pneumothorax and diaphragmatic endometriosis, be evaluated, its diagnosis, signs, and symptoms presented, as well as the search for new treatments.

REFERENCES

- Bricelj, K., et al. Catamenial pneumothorax since introduction of video-assisted thoracoscopic surgery. *Wiener Klinische Wochenschrift*, 129(19), 717-726, 2017.
- Casarin, S. T., Porto, A. R., Gabatz, R. I. B., Bonow, C. A., Ribeiro, J. P., & Mota, M. S. (2020). Tipos de revisão de literatura: considerações das editoras do Journal of Nursing and Health/Types of literature review: considerations of the editors of the Journal of Nursing and Health. *Journal of Nursing and Health*, 10(5).
- Furuta, C., Yano, M., Numanami, H., Yamaji, M., Taguchi, R., & Haniuda, M. (2018). Nine cases of catamenial pneumothorax: a report of a single-center experience. *Journal of Thoracic Disease*, 10(8), 4801.
- Gil, Y., & Tulandi, T. (2020). Diagnosis and treatment of catamenial pneumothorax: a systematic review. *Journal of Minimally Invasive Gynecology*, 27(1), 48-53.
- Haga, T., Kumasaka, T., Kurihara, M., Kataoka, H., & Miura, M. (2013). Immunohistochemical analysis of thoracic endometriosis. *Pathology International*, 63(9), 429-434.
- Hirata, T., Koga, K., & Osuga, Y. (2020). Extra-pelvic endometriosis: a review. *Reproductive Medicine and Biology*, 19(4), 323-333.
- Kaveh, M., Tahermanesh, K., Kashi, A. M., Tajbakhsh, B., Mansouri, G., & Sadegi, K. (2018). Endometriosis of diaphragm: a case report. *International Journal of Fertility & Sterility*, 12(3), 263.
- Kolos, A., Dzheshev, Z., Dikolaev, V., & Amangaliev, A. (2015). Catamenial Pneumothorax. *Experimental and Clinical Transplantation: Official Journal of the Middle East Society for Organ Transplantation*, 13, 144-145.
- Machairiotis, N., Stylianaki, A., Dryllis, G., Zarogoulidis, P., Kouroutou, P., Tsiamis, N., & Machairiotis, C. (2013). Extrapelvic endometriosis: a rare entity or an under diagnosed condition?. *Diagnostic pathology*, 8(1), 1-12.
- Marjański, T. (2016). Sowa K1, Czapla A1, Rzyman W. *Catamenial pneumothorax: A review of the literature. Kardiochir Torakochirurgia Pol*, 13, 117-21.
- Nezhat, C., Lindheim, S. R., Backhus, L., Vu, M., Vang, N., Nezhat, A., & Nezhat, C. (2019). Thoracic endometriosis syndrome: a review of diagnosis and management. *JSLs: Journal of the Society of Laparoendoscopic Surgeons*, 23(3).
- Nezhat, C., Lindheim, S. R., Backhus, L., Vu, M., Vang, N., Nezhat, A., & Nezhat, C. (2019). Thoracic endometriosis syndrome: a review of diagnosis and management. *JSLs: Journal of the Society of Laparoendoscopic Surgeons*, 23(3).
- Nwiloh, J. (2011). Diaphragmatic patch: a useful adjunct in surgical treatment of recurrent catamenial hemothorax. *Revista Portuguesa de Pneumologia (English Edition)*, 17(6), 278-280.
- Proetti, S. (2018). As pesquisas qualitativa e quantitativa como métodos de investigação científica: Um estudo comparativo e objetivo. *Revista Lumen-ISSN: 2447-8717*, 2(4).

Rousset, P., Rousset-Jablonski, C., Alifano, M., Mansuet-Lupo, A., Buy, J. N., & Revel, M. P. (2014). Thoracic endometriosis syndrome: CT and MRI features. *Clinical Radiology*, 69(3), 323-330.

Silva, L. A., Mattos, I. C., de Amorim, R. C., Neto, C. L. D. S., & Squeff, F. A. (2018). Pneumotórax catamenial: um relato de caso. *Revista Educação em Saúde, Anápolis*, 6(2), 138-142.

Souza, M. T. D., Silva, M. D. D., & Carvalho, R. D. (2010). Revisão integrativa: o que é e como fazer. *Einstein (São Paulo)*, 8, 102-106.

Soares, T., Oliveira, M. A., Panisset, K., Habib, N., Rahman, S., Klebanoff, J. S., & Moawad, G. N. (2021). Diaphragmatic endometriosis and thoracic endometriosis syndrome: a review on diagnosis and treatment. *Hormone Molecular Biology and Clinical Investigation*.

Sorino, C., Negri, S., Spanevello, A., & Feller-Kopman, D. (2020). The pleura and the endocrine system. *European Journal of Internal Medicine*, 72, 34-37.

Viti, A., Bertoglio, P., Roviglione, G., Clarizia, R., Ruffo, G., Ceccaroni, M., & Terzi, A. C. (2020). Endometriosis involving the diaphragm: a patient-tailored minimally invasive surgical treatment. *World Journal of Surgery*, 44(4), 1099-1104.

Vigueras Smith, A., Cabrera, R., Kondo, W., & Ferreira, H. (2021). Diaphragmatic endometriosis minimally invasive treatment: a feasible and effective approach. *Journal of Obstetrics and Gynaecology*, 41(2), 176-186.

Wetzel, A., Philip, C. A., Golfier, F., Bonnot, P. E., Cotte, E., Brichon, P. Y., & Dubernard, G. (2021). Surgical management of diaphragmatic and thoracic endometriosis: A French multicentric descriptive study. *Journal of Gynecology Obstetrics and Human Reproduction*, 50(8), 102147.

Zhou, B., & Li, W. (2015). A case of gastrocolic fistula secondary to adenocarcinoma of the colon. *International Journal of Surgery Case Reports*, 15, 46-49.