 <https://doi.org/10.56238/alookdevelopv1-020>

Fabiano da Silva Flores

Master's Degree in Surgery and Small Animal Clinic
Institution: Federal University of Santa Maria - UFSM
Address: Av. Roraima, N°1000, Camobi, Santa Maria,
Rio Grande do Sul, Zip Code: 97105-900
Email: 800fabiano@gmail.com

Guilherme Rech Cassanego

PhD student of the Graduate Program in Wild Animals
Institution: Universidade Estadual Paulista Júlio de
Mesquita Filho – UNESP Campus Botucatu
Address: Street: Prof. R. Dr. Valter Maurício Corrêa,
S/N, Botucatu- SP
Email: rechmv@gmail.com

Eliesse Pereira Costa

Master's Degree in Preventive Veterinary Medicine
Institution: Federal University of Santa Maria - UFSM
Address: Av. Roraima, N°1000, Camobi, Santa Maria,
Rio Grande do Sul
Email: eliesse.pcosta@hotmail.com

Carolina Cauduro da Rosa

Master's Degree in Surgery and Small Animal Clinic
Institution: Federal University of Santa Maria - UFSM
Address: Av. Roraima, N°1000, Camobi, Santa Maria,
Rio Grande do Sul
Email: carolinacdarosa@gmail.com

Anita Marchionatti Pigatto

PhD student of the Graduate Program in Wild Animals
Institution: Universidade Estadual Paulista Júlio de
Mesquita Filho – UNESP Campus Botucatu
Address: Street: Prof. R. Dr. Valter Maurício Corrêa,
S/N, Botucatu- SP
Email: anitamarchionatti@hotmail.com

Luís Felipe Dutra Corrêa

Ph.D. in Small Animal Surgical Clinic
Institution: Federal University of Santa Maria
Address: Av. Roraima, N°1000, Camobi, Santa Maria,
Rio Grande do Sul
Email: i.oftalmologioveterinaria@yahoo.com.br

ABSTRACT

In the clinical routine of small animals, the occurrence of foreign bodies (FB) in the digestive tract is routine, especially in dogs and cats with uncontrolled eating habits and puppies. In dogs, the main occurrence is bones, and in cats, linear materials. Surgical removal is usually the effective method in the treatment of esophageal FB, and endoscopy is the technique of choice, however, in some cases, it is recommended to perform thoracotomy with esophagotomy, as it presents the best results in surgical resolution. The objective of this study is to report the case of a two-year-old Labrador canine who was treated by the Ophthalmology and Surgery Sector of the University Veterinary Hospital of the Federal University of Santa Maria (HVU-UFSM) and who presented esophageal obstruction by the body and tranche. After the diagnosis and with the results of the complementary comb exams, the patient was submitted to thoracotomy with esophagotomy for the removal of the FB. In the intraoperative period, analgesic, anti-inflammatory, and antibiotic medications were used, as follows: dipyrone 25 mg/kg, TID, tramadol hydrochloride 4 mg/kg, TID, meloxicam 0.1 mg/kg SID and ceftaroline 30 mg/kg BID, all intravenous lines. On the third day after surgery, the patient was discharged without complications. The same medications were prescribed for home administration, replacing the route of administration for the oral route and the antibiotic for cefalexin 30mg/kg. The surgical approach chosen for the treatment was indicated by the size and location of the FB in the esophagus. Thus, it is concluded that the use of this technique provides the removal with the visualization of the viability of the layers and sofics and demonstrates excellent results with a return to routine activities.

Keywords: Canine, strange body, esophagotomy, thoracotomy.

1 INTRODUCTION

In the clinical routine of small animals, the occurrence of foreign bodies (FB) is routine, especially in dogs and cats with uncontrolled feeding habits and puppies. According to Radlinsky (2014), foreign bodies are inanimate objects that can cause total or partial obstruction of the esophageal lumen. The esophagus is divided into cervical and thoracic portions, and is first dorsal to the tracheal, and then deviates to the left, in the middle of the neck, and maintains the position at the thoracic entrance (DYCE, SACK & WENSING, 2010).

Obstructions in dogs and cats, in abnormal ingestion, can be at the base of the tongue, at the entrance of the larynx, in the esophagus, stomach, and intestine. According to Sturgess (2001), these obstacles in the esophagus are most often located at the base of the heart and in the diaphragmatic hiatus, sites that anatomically present narrowing.

Clinical signs include vomiting, regurgitation, depression, lethargy, pyrexia, cough, and dysphagia. Acute dyspnea can occur in cases of foreign bodies obstructing the airways or by pleural effusion or pneumothorax secondary to perforation of the esophagus (NELSON & COUTO, 2015). The diagnosis is made by the association of clinical examinations, anamnesis, and complementary exams such as radiography. Ultrasonography and endoscopy may be requested, and the latter but also diagnostic may be therapeutic (MARKS, 2004).

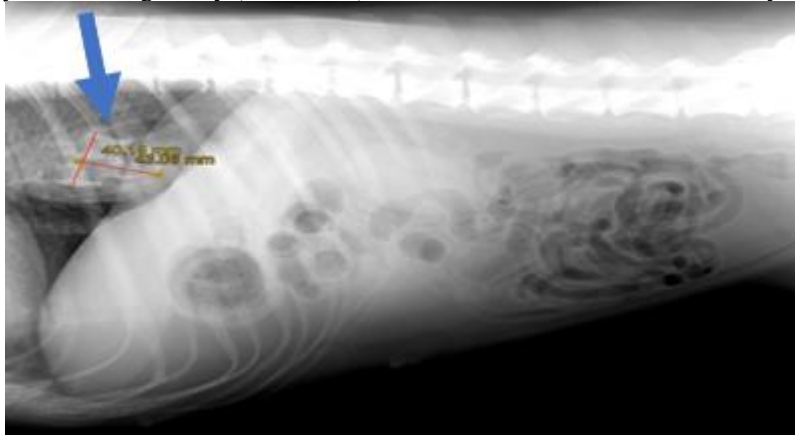
To choose the most appropriate surgical approach for the patient, the veterinarian needs to complete the anamnesis, complete physical examination, and complementary examinations. Being the evaluation of the veterinary clinician essential in cases of esophageal obstruction, the surgical treatment occurs through the removal of the foreign corp (TAMS and SPECTOR, 2011).

The objective of this study is to describe a case of esophageal foreign body removal by intercostal thoracotomy, in addition to clarifying the advantages and disadvantages of the technique.

A two-year-old female canine weighing 30 kg of the Labrador breed was treated at the Veterinary Hospital of the Federal University of Santa Maria, presenting with anorexia, vomiting, respiratory difficulty, and the risk of having ingested bones. The patient had ingested shredded chicken the day before the appointment and regurgitated all the contents. On physical examination, rectal temperature was measured at 39°C, 44 mpm RF, and 200 bpm HR, and pulmonary auscultation showed no significant changes. Blood samples were collected for biochemical tests and blood counts (complete blood count, alkaline phosphatase, urea, creatinine, aspartate aminotransferase, total proteins, and albumin), and the patient was referred for a complementary chest X-ray examination.

On radiography, it was observed in the topography of the caudal thoracic esophagus (adjacent to the diaphragm) esophageal dilation associated with a radiopaque structure larger than the esophageal lumen, suggesting the presence of esophageal FB (Figure 1).

Figure 1 – Radiography of the foreign body (blue arrow) caudal to the base of the heart and 2-year-old female Labrador.



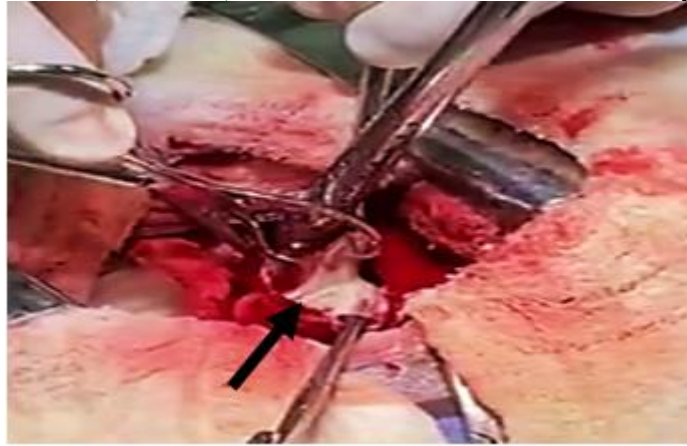
After the diagnosis, it was decided to perform the surgical intervention using the technique of intercostal thoracotomy with esophagotomy because it is an FB of dimensions of 4.01 cm thick and 4.3 cm long, besides being a sharp material that would not allow removal by endoscopy without damaging the organ.

In the surgical technique, the anesthetic protocol consisted of methadone 0.2 mg/kg, as pre-anesthetic medication, anesthetic induction with propofol 4 mg/kg, supportive therapy with cephalothin 30 mg/kg, dipyrone 25 mg/kg, meloxicam 0.2 mg/kg and anesthetic maintenance with isoflurane in partial inhalation (semi-closed). The patient was pre-oxygenated and ventilated for five minutes before anesthetic induction.

The patient, already trichotomized, was positioned in the right lateral decubitus position, and then antiseptics were performed from the second to the eighth dorsoventral intercostal space with 2% degerming chlorhexidine and 0.5% alcoholic chlorhexidine solution. A skin incision was made with a Bardparker 4 scalpel, division of the subcutaneous tissue in the sixth intercostal space in the dorsoventral direction, and myotomy of the great dorsal, serratus ventral, intercostal external, internal, and parietal pleura muscles. Before the opening of the chest wall, the anesthesiologist was notified, so that he could perform the appropriate ventilatory maneuvers. Two moistened compresses were positioned, with a heated saline solution on the edges of the incision, and Finochietto's self-static stator was used to remove the ribs and expose the operative field.

After inspection of the esophagus, it was isolated with the aid of compresses moistened with 0.9% NaCl solution, and esophagotomy was performed with a puncture of the scalpel and longitudinal expansion with Metzenbaum scissors. With two Allis forceps, the edges of the esophageal wall were pulled and with the opening sufficient for visualization, and with the aid of gauze, in order not to occur extravasation in the operative field, the FB of dimensions of 4.01 cm thick and 4.3 cm long was removed with the aid of a Backhaus forceps (Figure 2).

Figure 2 – Removal of the bone (black arrow) with the aid of Backhaus tweezers in a 2-year-old female Labrador.



After removal, esophagography was performed with a synthetic monofilament absorbable polydioxanone (PDX) n° 2-0 in an isolated Swift pattern. The synthesis of the chest wall was performed in five layers, the first being the approximation of the ribs with PDX n° 0 in a simple isolated pattern and before closing the last point was reestablished the negative pressure of the chest was by the chest drain, which was introduced into the eighth intercostal space. The second layer was myorrhaphy of the serratus ventral muscle with PDX n° 2-0 in a simple continuous pattern, myorrhaphy of the latissimus dorsi and subcutaneous muscle with PDX n° 3-0 in a simple continuous pattern, and skin with náilon n° 3-0, Wolff isolated pattern.

After the surgery, the dog was hospitalized in the UVH for three days to receive intravenous medications, which included: dipyrone 25mg/kg TID, cephalothin 30mg/kg BID, tramadol hydrochloride 4mg/kg TID and meloxicam 0.1 mg/kg SID. After this period, he was discharged with the same analgesic medications for home use for five days, and cefalexin 30mg/kg BID for another 7 days. After seven days, a new reassessment was performed, where it was possible to notice that the healing occurred in an expected way, without the presence of infection in the surgical wound of the costal wall, and that the patient was feeding habitually. Sendo thus, these skin spots were removed.

Foreign bodies are inanimate objects that can cause total or partial obstruction of the esophageal lumen (RADLINSKY, 2014). In the evaluation of the patient reported total obstruction of the esophagus occurred. This complication should be suspected in patients with acute signs of choking, vomiting, coughing, regurgitation, ptyalism, and dysphagia. Conso, in cases where partial obstructions occur, there may not be the presence of evident clinical signs as cited by Thompson *et al.*, (2012). All these clinical signs were present in the patient in this report.

According to Fingeroth (2007), the diagnosis of esophageal obstruction is based on clinical history, physical examination, and complementary tests. In this dog, the physical examination and complementary examination of plain radiography were performed, in which a caudal radiopaque structure at the base of the heart was found. The examinations should be performed in the right and

left lateral decubitus position because the movements of gastrointestinal gases can show the foreign body when moving to different positions (KEALY, MCALLISTER, and GRAHAM, 2012). In addition to the lateral decubitus positions, the ventrodorsal projection was performed. This position, however, may not adequately evidence the esophageal condition due to overlap with the spine.

The treatment chosen was the intercostal thoracotomy, because it was a bone of size considered large, which was larger than the esophageal lumen, so it would not be possible to remove it by endoscopy, according to Doran *et al.*, (2008). The benefits of surgical exploration include the removal of any foreign material, repair of esophageal tissue, and washing of traumatized tissues to reduce microbial contamination.

An important point that was taken into consideration to opt for surgical access was the characteristics of the esophagus, which lead to a higher risk of contamination, due to the absence of serosa and omentum. In addition, due to the tension of wall distension and the presence of swallowing movements, esophageal rupture may occur in the finaloscopic manipulation. As evidenced by Pinto, *et al.*, (2014), the size and composition of the FB, along with the duration of the obstruction are related to greater damage to the mucosa.

A long-term complication of EC obstruction is esophageal stenosis, due to the fibroblastic reaction that can occur in the area (JUVET *et al.*, 2010). In the present case, the presence of lesions on the wall during the intervention or changes in the postoperative period was not verified, even six months after the procedure, during which the patient was reassessed.

The surgical approach performed by the left side of the chest is a preference of the surgeon, because the presence of vena cava on the right side, underlying the esophagus, increases the risk of contamination or trauma of these vessels.

From the review and the case described, it is concluded that the technique of intercostal thoracotomy with esophagotomy should be used in some cases, especially when foreign bodies of sizes greater than the esophageal lumen or acute bridges are present. In the case reported, the rapid recovery of the canine is observed and no trans and postoperative complications are observed due to the precise diagnosis of the condition and effective control of the inflammatory process, in addition to the appropriate selection of the patient and technique and the extensive experience of the surgeon. Thus, an accurate and rapid diagnosis, with the use of the correct and early surgical technique, was crucial for the main thing, which is the return to the normal activity of the patient quickly and satisfactorily.

REFERENCES

- BARASH, N.R.; LASHNITS, E.; KERNZ, T.; TOLBERT, M.K.; LUNN, K.F. Outcomes of esophageal and gastric bone foreign bodies in dogs. **Journal Veterinary Internal Medicine**, v.36, n.2, p.500-507, 2022. DOI:10.1111/jvim.16383.
- BARCELLOS, R. R. **Corpos Estranhos Esofágicos em Cães**. 2012. 46f. Monografia- (Trabalho de conclusão de curso) – Universidade Federal do Rio Grande do Sul, Porto Alegre, RS, 2012. .
- DORAN, I. P; WRIGHT, C. A; MOORE, A. H. Acute oropharyngeal and esophageal stick injury in forty-one dogs. **Veterinary Surgery**, Bristol, v. 37, n. 8, p. 781-785, Dec. 2008.
- DYCE, K. M. A; SACK, W. O.; WENSING, C. J. G. Cabeça e a parte ventral do pescoço. In: **Tratado de anatomia veterinária**. 4. ed. Rio de Janeiro: Elsevier, 2010, cap. 11, p. 374-406.
- FINGEROTH, J.M. Esôfago. In: SLATTER, D. **Manual de Cirurgia de Pequenos Animais**. 3. Ed. São Paulo, Manole, 2007. Cap. 42. p. 646-681.
- HUCK, J.; KYLES, A.E. Surgery of the oesophagus. In: BROCKMAN, D.J; HOLT, D.E; HAAR, G. **BSAVA Manual of Canine and Feline Head, Neck and Thoracic Surgery**. Gloucester: BSAVA, 2018. p.116-122.
- JUVET, F; PINILLA, M; SHIEL, R.E; MOONEY, C.T. Oesophageal foreign bodies in dogs: factor affecting success of endoscopic retrieval. **Irish Veterinary Journal**, v. 63, n.3, p. 1-6, 2010. DOI: 10.1186/2046-0481-63-3-163. Disponível em <http://link.springer.com/article/10.1186/2046-0481-63-3-163>.
- KEALY, J. K; MCALLISTER, H; GRAHAM, J. P. **Esôfago Radiografia e Ultrassonografia do cão e do gato**. 5. ed. Rio de Janeiro: Elsevier, 2012. p. 136-140.
- MARKS, S. L. Doenças da Faringe e do Esôfago. In: **Tratado de medicina interna veterinária: Doenças do cão e do gato**. 5 ed. Rio de Janeiro: Guanabara Koogan, 2017. Cap. 273, p. 3552-3557.
- NELSON, R.W.; COUTO, C.G. Desordens da Cavidade Oral, Faringe e Esôfago. In: **Medicina Interna de Pequenos Animais**. 5. Ed. Rio de Janeiro: Elsevier, 2015. cap.31, p.1285-1323.
- PINTO, R.E; PEREIRA, P; MACEDO, G. Endoscopic management of a delayed diagnosed foreign body esophageal perforation. **GE Jornal Português de Gastrenterologia**. v.21, n.1, p.35-38, 2014. DOI:10.1016/j.jpg.2013.10.003. Disponível em: <http://www.sciencedirect.com/science/article/pii/S09728171300115X>.
- RADLINSKY, M.G. Cirurgia do Sistema Digestório. In: FOSSUM, T.W. **Cirurgia de Pequenos animais**. 4. ed. Rio de Janeiro: Elsevier, 2014. Cap. 20, p. 1221-1234.
- STURGESS, C. P. Doenças do Trato Alimentar. In: DUNN, J.K. **Tratado de medicina de pequenos animais**. São Paulo, Roca, 2001. p. 367-407.
- THOMPSON, H.C; CORTES, Y; GANNON, K; BAILEY, D; FREER, S. Corpos estranhos esofágicos em cães: 34 casos (2004-2009) . **Jounal Veterinary Emergency Crit Care**, v.22, p.253-261, 2012.