



## The effectiveness of microneedling in the treatment of post-COVID-19 hair disorders

  <https://doi.org/10.56238/emerrelcovid19-057>

### Alice Pires Cassimiro

Graduating in Aesthetics Bachelor's Degree. Universidade CEUMA, 65075-120 São Luís-MA, Brazil.

E-mail: [alicecsmr2@gmail.com](mailto:alicecsmr2@gmail.com)

### Mary Magdalene Costa Ferreira

Graduating in Aesthetics Bachelor's Degree. Universidade CEUMA, 65075-120 São Luís-MA, Brazil.

E-mail: [mm.ferreira@outlook.com](mailto:mm.ferreira@outlook.com)

### Thaina Lima Santos

Graduating in Aesthetics Bachelor's Degree. Universidade CEUMA, 65075-120 São Luís-MA, Brazil.

E-mail: [thainalima150@gmail.com](mailto:thainalima150@gmail.com)

### Maria Tereza Martins Mascarenhas

Specialist in Dermaesthetics, Aesthetic Teacher Bachelor's Degree. Universidade CEUMA, 65075-120 São Luís-MA, Brazil.

E-mail: [terezamartins.s@hotmail.com](mailto:terezamartins.s@hotmail.com)

### Solange Negreiros de Almeida Bacelar

Master in Maternal and Child Health, Professor Aesthetics Bachelor's Degree. Universidade CEUMA, 65075-120 São Luís-MA, Brazil.

E-mail: [solange.bacelar@ceuma.br](mailto:solange.bacelar@ceuma.br)

### Ana Eugenia Araujo Furtado

PhD in Collective Health, Professor of Aesthetics Bachelor's Degree. Universidade CEUMA, 65075-120 São Luís-MA, Brazil.

E-mail: [eugenia@hotmail.com](mailto:eugenia@hotmail.com)

### Karla Virginia Bezerra de Castro Soares

PhD in Dentistry, Professor Aesthetic Bachelor's Degree. Universidade CEUMA, 65075-120 São Luís-MA, Brazil.

E-mail: [karla1441@yahoo.com.br](mailto:karla1441@yahoo.com.br)

### Ludmilia Rodrigues Lima Neuenschwander Penha

Master in Management of Health Programs and Services, Professor Aesthetics Bachelor's Degree. Universidade CEUMA, 65075-120 São Luís-MA, Brazil.

E-mail: [ludpenha@gmail.com](mailto:ludpenha@gmail.com)

### Ríndhala Jadão Rocha Falcão

Master in Health and Environment, Professor Aesthetics Bachelor's Degree. Universidade CEUMA, 65075-120 São Luís-MA, Brazil.

E-mail: [ryndhalajad@hotmail.com](mailto:ryndhalajad@hotmail.com)

### Julia De Aguiar Baldez Sousa

Specialist in Dermaesthetics, Aesthetic Teacher Bachelor's Degree. Universidade CEUMA, 65075-120 São Luís-MA, Brazil.

E-mail: [juliabaldez@hotmail.com](mailto:juliabaldez@hotmail.com)

### ABSTRACT

Patients who were contaminated by SARS-CoV-2 developed an infectious picture of non-cicatricial alopecia of the type's alopecia areata - AA, androgenetic alopecia - AGA and increased cases of telogen effluvium - ET, and for alopecia areata and androgenetic alopecia was observed worsening of these diseases in cases of patients already being carriers of this pathology. This article is characterized as an integrative, descriptive and qualitative review. The work was composed of specialized bibliography, consisting mainly of articles and scientific journals published in English and Portuguese, consulted the Medline databases (Medical Literature Analysis and Retrieval System Online); Google Scholar and Virtual Library – CEUMA, using the descriptors "COVID-19" and "hair disorder", "COVID-19" and "alopecia", "microneedling" and "treatment" and "alopecia". Microneedling accelerates the inflammatory process, providing skin revascularization, tissue regeneration and hair follicle stimuli. It is a safe method with a low risk of side effects, showing effective results in androgenetic alopecia-AGA, alopecia areata-AA and telogen effluvium-ET.

**Keywords:** Hair therapy, alopecia, SARS-CoV-2.

## 1 INTRODUCTION

Hair and the overvaluation of personal image are directly linked. Hair loss is directly related to lack of confidence, impacting self-esteem and mental health. The treatment of this disorder is fundamental for the recovery of health and quality of life of people who are affected by this type of pathology (CRISTINO *et al.*, 2022). However, advances in science in the search for better techniques, which are able to control progression and/or reverse cases, have been advancing (TALEI *et al.*, 2021).

According to Basilio *et al.* (2022), microneedling therapy has been used to treat hair disorders, regenerate follicles and seek balance of the capillary cycle. Treatment with microneedling proved to be quite advantageous at this time of increased cases of capillary disorder caused by the SARS-CoV-2 virus, when compared to other therapies (OCAMPO-GARZA *et al.*, 2022).

SARS-CoV-2 virus infection is directly associated with exacerbation of the hair disorder, hair loss, and other diseases such as prostate cancer, benign prostatic hyperplasia, and polycystic ovary syndrome (WAMBIER *et al.*, 2022). Several cases of dermatological diseases such as erythematous rash, generalized urticarial, chickenpox-like vesicles, acroischemia, chilblain-like eruptions and petechiae eruptions mimicking dengue were also evidenced (CAPALBO *et al.*, 2021; BRANDÃO, 2022).

Researchers are unsure of the harmful effects related to the duration and extent of the disease. However, hair loss is one of the disorders that has been drawing the attention of scientists (NATÁRIO *et al.*, 2022).

It was observed that patients who were contaminated by SARS-CoV-2 developed an infectious picture of non-cicatricial alopecia of the type's alopecia areata - AA, androgenetic alopecia - AGA and increased cases of telogen effluvium - ET, and for alopecia areata and androgenetic alopecia worsening of these diseases was observed in cases of patients already being carriers of this pathology (OGBUEFI *et al.*, 2022).

SARS-CoV-2 is the virus that causes the COVID-19 pandemic, its spread and mutation occur in an accelerated way, that is, each new host that settles can undergo variations, and may be more pathological or more infectious. The most contagious mutant viruses become dominant in the population, giving rise to new viral strains (SANTOS *et al.*, 2021).

According to Capalbo *et al.* (2021), the failure in the tolerance mechanism activates the self-reactive cells – T and cause damage to the hair follicles, thereby activating and/or reactivating autoimmune diseases such as alopecia areata – AA. In addition to this factor, the environmental trigger was considered, which affects mental health and accentuates psychological stress, which seems to be another possible risk factor for this pathogenesis. The SARS-CoV-2 virus can act on different autoimmune pathways, stimulating an inflammatory environment that allows nonspecific activation of

the immune system or by a cross-reaction between its antigens and the host antigens. Studies are being deepened, investigated and one of them is on the transmembrane serine protease enzyme 2, better known as (TMPRSS2). Although this enzyme does not belong to SARS-CoV-2, it was found that it has a fundamental role in host infection and, for this reason, may be a potential pathway to combat and spread SARS-CoV-2 and its harmful effects (SANTOS *et al.*, 2021; GRESS *et al.*, 2022).

The researched literature already shows a strong trend in relation to hair loss and COVID-19 infection. Therefore, this work aims to demonstrate the effectiveness of microneedling techniques in the treatment of hair disorders. This treatment option is showing highly promising results in the face of exacerbation of capillary disorders caused by SARS-CoV-2 viral infection.

## 2 MATERIALS AND METHODS

The elaboration of this article was based on an integrative, descriptive and qualitative review. In addition, the work was composed of specialized bibliography, consisting mainly of articles and scientific journals published in English and Portuguese. The following post-COVID-19 hair loss research databases were used: Medline (*Medical Literature Analysis and Retrieval System Online*); Google Scholar (Google Scholar) and Virtual Library – CEUMA. The descriptors used were "covid-19" and "hair disorder", "COVID-19" and "alopecia", "*microneedling*" and "*treatment*" and "*alopecia*".

Data collection took place between February and March 2023, adopting the following inclusion criteria: articles published in the last five years and related to the proposed theme. On the other hand, as an exclusion method, the respective foundations were adopted: articles published on dates lower than 2019, articles that were repeated in the databases and articles whose objectives did not contemplate this research.

In total, 35 potential articles were analyzed for analysis, which belong to the *Medline* google scholar database and CEUMA Virtual Library. Thus, and considering the inclusion and exclusion criteria mentioned above, 26 studies were selected to compose this research.

## 3 RESULTS AND DISCUSSION

After conducting the searches, where the selected articles were read and interpreted, this article presents the main capillary disorders caused by the SARS-CoV-2 virus and also the treatment through microneedling techniques. It was observed, in this sense, that several articles indicated the need for further scientific investigations to prove the treatment.

In studies by Nguyen *et al.* (2022), when 41 articles were chosen for evaluation, considered the association between infection caused by the SARS-CoV-2 virus and the various types of alopecia. In

this first analysis, 1826 patients were selected, all of whom were affected by the virus and developed or had relapse of alopecia. As shown in **Table 1**.

Table 1 - Association between SARS-CoV-2 and types of alopecia.

Types of alopecia associated with SARS-CoV-2 contamination		
Types of alopecia	%	Quantity
Alopecia AGA	31%	561
Alopecia TE	20%	362
Alopecia AA	7,80%	143
Other types Alopecia	0,20%	4
Not classified	41,40%	756
Total	100%	1826

Source: Nguyen *et al.* (2022)

For Vieira *et al.* (2022), changes in the life cycle of the anagen to telogen phase in patients infected with the SARS-CoV-2 virus are caused by the release of specific neuropeptides, neurotransmitters, and hormones in the brain axis of the hair follicle. Carneiro *et al.* (2023), state that the increased release of cytokine can cause the alteration of the cycle or damage to the cells of the capillary matrix. Saki *et al.* (2022), on the other hand, emphasize that there is also a reduction in anticoagulant proteins, which can cause microthrombi and, consequently, there is a reduction in the amount of blood to the hair follicle. The consumption of drugs, especially blood thinners during the treatment of COVID-19, may also have its contribution.

In addition, **Table 2** shows the period that arose and the duration of hair loss after the individual was infected by the SARS-CoV-2 virus. An increase in the prevalence of cases during the pandemic period has been observed. During this observation, of the 80 patients evaluated, 43 of them, that is, 53.75% presented hair loss disorders.

Table 2 - Time after the onset of COVID-19 infection until the development of hair loss and the duration of hair loss

Period	Onset of hair loss after SARS-CoV-2 contamination		Duration of hair loss	
	Number of Patients	%	Number of Patients	%
1 week	3	6,98	0	
15 days	11	25,88	0	
1 month	13	30,23	2	4,65
2 months	4	9,3	7	16,28
3 months	10	23,25	8	18,60
4 months	0	0	8	18,60
5 months	0	0	1	2,33
6 months	0	0	5	11,63
another 6 months	2	4,65	7	16,28

They didn't know how to answer	0	0	5	11,63
TOTAL	43	100%	43	100%

Source: Perelli *et al.* (2022)

According to **Table 2**, most patients developed the hair disorders between 15 days and 3 months after being infected by the virus. For cases before the pandemic, the emergence of this pathology was observed between a period of 60 to 90 days after a stressful agent that triggers this condition. Regarding the duration of hair loss of the 43 patients, only 38 were able to inform, the others did not respond. The table also shows that recovery, in its majority, occurred in up to 6 months, cases over 6 months escape from traditional cases and can be considered acute telogen (PERELLI *et al.*, 2022). Emphasizing the fact of the early disease, in another study conducted the average onset of the disease was 57.1 days, taking into account a sample of 214 patients with telogen effluvium type disorder (ARAUJO *et al.*, 2022).

However, for Saki *et al.* (2022), the increase in the prevalence of telogen effluvium was 400%, considering the period since the beginning of the pandemic. Telogen effluvium is a self-limited pathology, is divided into acute, which lasts for 6 months or less and is chronic (presented in an intermittent diffuse form), lasting more than 6 months. For patients infected by the SARS-CoV-2 virus, it has already been observed that recovery can occur around 3 months, however, recovery may be hampered due to the strong stress they are subjected to (CRISTINO *et al.*, 2022).

Perelli *et al.* (2022), not only evaluated the increase in hair loss, but also other symptoms that occurred on the scalp and hair shaft after infection. The main symptoms are described in **Table 3**.

Table 3 - Main hair disorders reported by the interviewee

Main hair disorders reported by the interviewee			
Symptoms	Individuals who had symptoms	Individuals who did not have symptoms	Percentage (%)
Thinning of the wires	24	19	55,8
Itching of the scalp	13	30	29,5
Sensitivity in the scalp	11	32	25,5
Weakening at the root	11	32	25,5

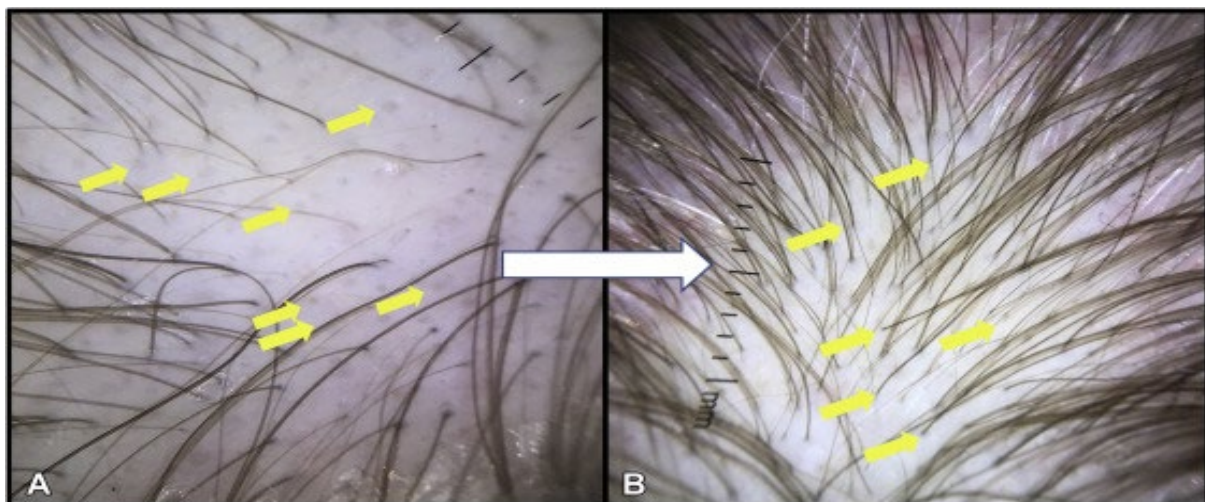
Source: Perelli *et al.* (2022)

The data shown in **Table 3** by Perelli *et al.* (2022), indicate the symptoms presented in the patients interviewed, in this sense it is important to highlight that the reports indicate that the scalp is more visible, the hair falls in several lengths and the density is reduced, that is, the fall is more diffuse. Being that these symptoms are very related to alopecia type telogen effluvium – ET. What's more, for

cases of alopecia areata – AA, the fall is more concentrated and usually oval in shape. Patients also reported scalp pain and/or tenderness.

Severe systemic infections can have interference in the functions of keratinocytes, leading even to the breakage of the hair shaft due to the contractions and expansions to which they are subjected, causing damage to the anagen matrix of the hair, this anomaly is known as Pohl-Pinkus's brand or bayonet hair. The hair breaks in the weakest part as a result of thinning or narrowing of the hair shaft (SAKI *et al.*, 2022).

Figure 1- post-COVID-19 Acute Telogen Effluvium – Female.



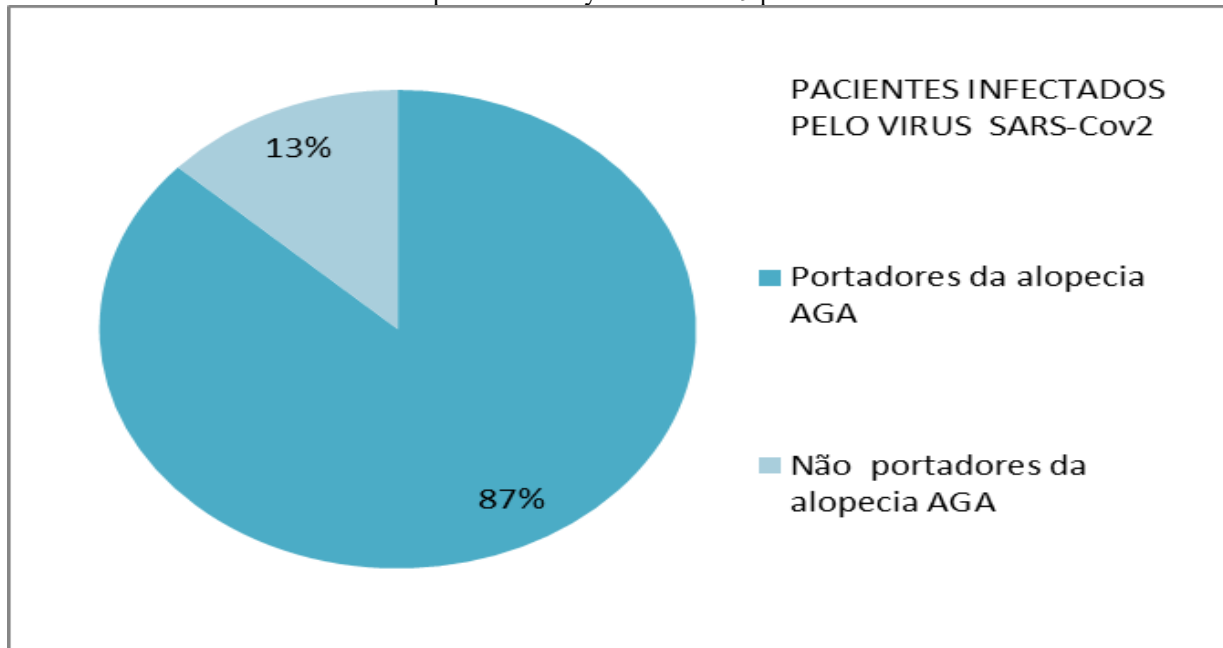
Source: Abrantes *et al.* (2021)

Photo A shows empty follicles and changes in the stems, as indicated in the yellow arrows and in photo B, after 4 months, the resolution of empty follicles and the presence of short hair strands, indicated in the yellow arrows (ABRANTES *et al.*, 2021).

Seyfi *et al.* (2022) compared the influenza pandemic in 1918 to COVID-19 in 2019. The study revealed that telogen effluvium - ET manifested itself in both pandemics, in influenza it was calamitous and the fall was on average 2 months and 15 days long, while in the case of COVID-19 it is estimated that it may be smaller. The study demonstrates that the cutaneous manifestations, that is, the occlusion of the microvasculature may have been caused by the greater release of cytokines (tumor necrosis factor, interleukin 1b, interleukin 6 and interferon types 1 and 2).

Wambier *et al.* (2020) report cases of high rates of androgenetic alopecia (AGA) in patients hospitalized with COVID-19 due to severe symptoms. Androgen sensitivity is a likely determinant of disease severity. In this sense, the evolution of the severity of the disease in patients with androgenetic alopecia is observed, as indicated in **Graph 1**.

Graph 1 - Severity of COVID-19 patients



Fonte: Ohyama. M; Matsudo, K. e Fujita, T. (2022)

According to the analysis of the graph above, among the patients who had androgenetic alopecia – AGA, 87% presented more severe picture when infected by the SARS-CoV-2 virus, while 13% did not have androgenetic alopecia – AGA. The research took into account a total of 98 patients, one of the justifications may have been the increase in serine protease 2 (TMPRSS2) or angiotensin-converting enzyme 2 (ACE-2), justified by the binding of dihydrotestosterone (DHT) to the androgen receptor, arising from the cleavage of the spike protein of the SARS-CoV-2 virus (OHYAMA; MATSUDO; FUJITA, 2022).

As reported by Natario *et al.* (2022), it is important to monitor this pathology associated with COVID-19, the way it presents itself and its evolution, because the earlier the diagnosis is detected, the easier it is to establish treatment procedures and stop the progression of the pathology, in addition to minimizing or eliminating possible sequelae.

There are several types of treatment for alopecia, but the choice of treatment should be made judiciously, taking into account each patient, the type of alopecia and the degree of evolution in order to choose the most appropriate therapy. It can be exemplified, in this sense, telogen effluvium pictures, which are most often self-limited and resolve without the need for some alternative therapy. In cases of chronic telogen effluvium, alopecia areata or other hair disorders, the analysis has to be thorough in order to choose the correct treatment and perform safely (PERELLI *et al.*, 2022).

Freitas, Vasconcelos and Oliveira Filho (2021) report that conventional therapies are presenting a low satisfaction rate, because their action is to prevent the spread of the pathology. These therapies have low efficacy in the areas already affected and do not act on regeneration, possibly due to the characteristics of the treatment and the need for prolonged use, in addition to causing several side

effects, such as the use of minoxidil and finasteride, which can cause hyperalgesia, sexual dysfunctions, breast and prostate cancer. Given this, there is a demand for new therapeutic treatments that can be more effective and meet expectations.

Treatments have emerged as an alternative to conventional methods, such as microneedling, laser therapy and platelet-rich plasma (PRP) and others. Ha *et al.* (2021) emphasize conventional treatments and the heredity of androgenetic alopecia, reinforce that they are limited treatments and added more examples of side effects such as Hypertrichosis, which is excessive hair growth. In addition, it was pointed out possible birth defects if administered in women of childbearing age, decreased libido and the possibility of prolonged impotence. The researchers noted that due to the limitations, many patients end up dropping out of treatment and 40 percent of these patients end up going bald. This is due to side effects and/or the need for continuity of conventional treatments.

The treatment with the microneedling technique emerges as a promising minimally invasive alternative to treat hair loss, as it has already shown its effectiveness and has its relatively low cost. Hair transplantation can be considered as a permanent treatment, however, due to its high cost, it ends up being unfeasible for most individuals affected by alopecia, low-level laser therapy is one of the treatments used, however, it has not proven its effectiveness when compared to other treatments (GUPTA *et al.*, 2022).

There is no standardized protocol to perform the microneedling technique, there are varied techniques, such as the form of application over the same place, intervals between sessions, duration of each session and the use or not of drug after or during the procedure. However, many articles share the same thinking with reference to esterization of the site, obtaining a hyperemia or punctual bleeding, that is, obtaining holes (and approximately 250 holes per square centimeter). No method during testing proved to be more effective than another. The length of the microneedles and the number of passes seem to have a satisfactory effect on hair growth (GUPTA *et al.*, 2022; SANTOS *et al.*, 2020; OAK; GOMEZ, 2022).

The first device of microneedles - roller was invented by Liebl and Fernandes, had approximately 200 microneedles, but in order to improve the form of application and with the aid of technology, the device was perfected. First came the microneedling pen and then they added a motor, which facilitates both the permeation of assets and the reduction of the sensation of pain. The advantages and limitations of roller and pen microneedling are described in **Table 4** (GUPTA *et al.*, 2022).

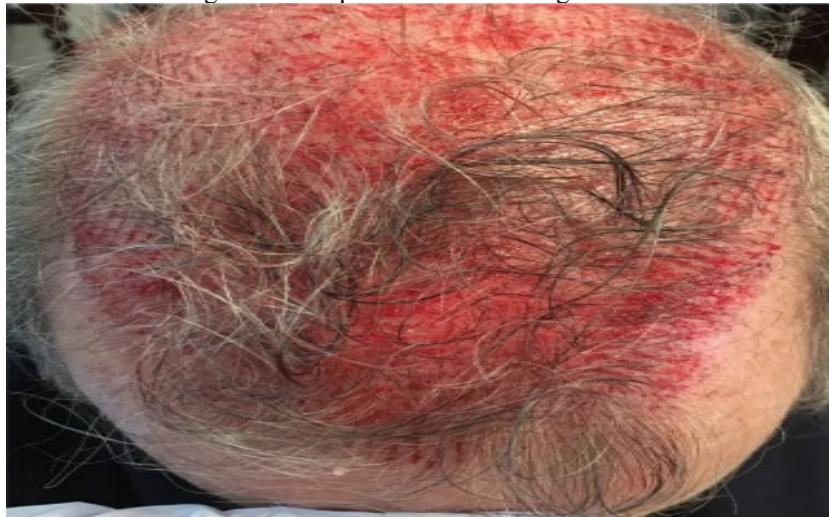Table 4 - Advantages and limitations of microneedling with Dermaroller and microneedling with pen

Dermaroller		Microneedling pen	
Limitations	Advantages	Limitations	Advantages
Puncture depth is according to the size of the roller needles – it can reach only one depth; Penetrate the skin at different angles, more painful, recovery time is longer; Treatment with less precision; It is a mechanical action	Product of easy access for purchase, being able to be applied in each at home and clinics	Purchase of more restricted product and requires professional assistance (Available only in professional environments and medical clinics)	Reaches the most difficult surfaces to reach the skin; Personalized treatment; The size of the needle can be adjusted reaching various depths for better penetration; Areas of difficult access, it is easier to treat; Penetrate the skin vertically causing less damage; Treatment with more precision and accuracy because it is an automated device

Cast iron: Gupta *et al.* (2022)

In one study, the microneedling technique was applied using the needle with a length of 1.5 mm on the areas affected by the pathogenesis, in addition to the asterisks technique (longitudinal, vertical and diagonal directions, eight times in each direction), or until erythema or bleeding was presented. The average duration was between 20 and 25 minutes. In this treatment minoxidil was not used and the scalp was not washed for a period of 24 hours (STARACE *et al.*, 2020). As Figure 2:

Figure 2 - Scalp after microneedling session



Data Source Provider: Starace *et al* (2020)

Starace *et al.* (2020) report that the study was done in the period of 6 months, when they evaluated the efficacy and tolerability, performed traction test, clinical iconography and trichoscopy, in each session the scalp was measured through digital images with varying magnifications 20x, 40x and 70x. The goal was to have all the information about the area under treatment.

Kang's point or "V" point was used as the primary reference. The "V" point is calculated by the intersection of the sagittal midline and the coronal line that connects both ends of the patient's tragus. At the end of the treatment in analysis, dermoscopy of the scalp revealed the typical aspect of AGA with the presence of diametric variability, peripillary signs and empty follicles in all patients. On the other hand, patients with TS presented short hair in regrowth at trichoscopy and positive traction test with telogen hair roots.

Starace *et al.* (2020) argue that in research carried out, that microneedling treatment has shown effective results in androgenetic non-cicatricial alopecias, telogen effluvium and Areata. For the case of AGA at the vertex in males and the frontal area in females, they are the ones that presented the highest percentage of improvement. The procedure induces a stop in hair loss as well as the density and thickening of the diameter of the capillary shaft. During the study period (6 months), no serious adverse side effects were reported. Through the analysis by clinical iconography and trichoscopy, the patients presented positive results, with stop of hair loss or decrease.

Zhou *et al.* (2020) argue that combination therapies for hair loss treatment have greater efficacy than monotherapy. In a sample when using microneedling together with minoxidil, the result presented was more effective when compared to other combinations. Microneedling through its microneedles causes micropunctures in the skin, causing non-inflammatory wounds, inducing neovascularization and the production of growth factors, thereby favoring the capillary restoration of the affected areas (OCAMPO-GARZA *et al.*, 2020). In addition, the author of the study adds that **microneedling** is proposed to increase hair growth; in particular, when needling-induced damage leads to the release of growth factors (TGF-alpha, TGF-beta, and platelet-derived growth factor [PDGF]) by platelets and neutrophils. Subsequently, fibroblasts provide collagen and elastin production in the papillary dermis.

The treatment with microneedling proved to be very advantageous at this time of increase in cases of alopecia, is more accessible and presents relatively fast results when compared to other therapies. It is a safe procedure, minimally invasive, does not interfere with the patient's routine. Microneedling involves thermal and/or physical injuries causing disruption in the skin barrier and can be combined with other therapies, in addition, it can be adopted in patients who do not respond to other therapies or patients who for some reason cannot use systemic treatment. Microneedling has already been shown to be effective even for more invasive or more time-consuming therapeutic regimens, and has no side effects (OCAMPO-GARZA *et al.*, 2022).

#### 4 CONCLUSIONS

The sensitivity of patients, especially women, cannot be ignored when it comes to hair loss, as it directly affects quality of life and personal self-esteem. It is known, therefore, that hair and appreciation of personal image are directly linked to this disorder. Therefore, the sooner you start treatment, the faster you can achieve satisfactory results.

Microneedling has plausibly shown its effectiveness in the treatment of hair disorders. Such a procedure accelerates the inflammatory process, providing skin revascularization, tissue regeneration and stimuli of the hair follicles. It is a safe method with a low risk of side effects, showing effective results in androgenetic alopecia-AGA, alopecia areata-AA and telogen effluvium-ET. In addition, microneedling therapy is associated with *the drug-delivery* technique.

Microneedling treatment has shown advantages, alone or combined with other therapies, it is a quick, easy and inexpensive procedure. Excellent strategy to promote hair growth post COVID-19.

## REFERENCES

Abrantes, tatiana f. *Et al.* Time of onset and duration of post-covid-19 acute telogen effluvium. *Journal of the american academy of dermatology*, v. 85, n. 4, p. 975-976. 2021. Disponível em: [https://www.jaad.org/article/s0190-9622\(21\)02149-6/fulltext](https://www.jaad.org/article/s0190-9622(21)02149-6/fulltext). Acesso em: 10 mar. 2023.

Araujo v. C *et al.* Eflúvio telógeno após a infecção por covid 19: uma revisão narrativa sobre o mecanismo fisiológico/telogen effluvium after sars-cov-2 infection: a narrative review of physiological mechanism. *Brazilian journal of health review*, v. 5, n. 3, p. 10157-10164. 2022. Disponível em: <https://ojs.brazilianjournals.com.br/index.php/bjhr/article/view/48494>. Acesso em: 15 abr. 2023.

Basilio, flávia machado alves; brenner, fabiane mulinari; werner, betina. Microagulhamento para tratamento de alopecia de padrão feminino: relato de caso e alterações histopatológicas. *Surgical & cosmetic dermatology*, v. 14, p. 1-4. 2022. Disponível em: <http://www.surgicalcosmetic.org.br/content/imagebank/pdf/v14/v14a74.pdf>. Acesso em: 7 mar. 2023.

Carneiro, g. M. S *et al.* Eflúvio telógeno em pacientes pós covid-19. *Rev.cient. Estét. Cosmetol*, v.3, n.1 e0732023, p. 1-6. 2023. Disponível em: <https://rcec.com.br/journal/index.php/rcec/article/view/73>. Acesso em: 15 abr. 2023.

Capalbo, a. *Et al.* Alopecia areata in a covid-19 patient: a case report. *Dermatologic therapy*, v. 34, n. 2, p. E14685. 2021. Disponível em: <https://pubmed.ncbi.nlm.nih.gov/33331017/>. Acesso em: 15 abr. 2023.

Carvalho, e.a., gomez,m.l.p. Tratamento da alopecia: comparação entre os resultados obtidos por aplicação das técnicas de microagulhamento e laser de baixa potência. *Revista uniitalo em pesquisa, são paulo sp*, v. 12, n. 3, p. 84-113, jul. 2022. Disponível em: <http://pesquisa.italo.com.br/index.php?journal=uniitalo&page=article&op=view&path%5b%5d=554>. Acesso em: 4 mar. 2023.

Cristino a.b. *Et al.* Impacto físico e emocional nas pessoas com eflúvio telógeno pós-infecção pelo covid-19. *Bws journal*, v. 5, 2022. Disponível em: <https://bwsjournal.emnuvens.com.br/bwsj/article/view/358>. Acesso em: 15 abr. 2023

Freitas, m. R.; vasconcelos, r. C. F.; oliveira filho, j. Resposta terapêutica da alopecia androgenética após drug delivery. *Revista ibero-americana de humanidades, ciências e educação*, v. 7, n. 11, p. 889–910. 2021. Disponível <https://periodicorease.pro.br/rease/article/view/3122>. Acesso em: 7 abr. 2023.

Gress, j. B. *Et al.* Eflúvio telógeno pós-infecção por covid-19: um revisão narrativa. *Brazilian journal of health review, curitiba*, v. 5, n. 2, p. 4692-4701, mar. /abr. 2022. Disponível em: <https://repositorio.uniceub.br/jspui/bitstream/prefix/16036/1/efl%3%bavio%20tel%3%b3geno%20ap%3%b3s%20a%20infec%3%a7%3%a3o%20por%20covid%2019%20uma%20revis%3%a3o%20narrativa%20sobre%20o%20mecanismo%20fisiol%3%b3gico.pdf>. Acesso em: 7 mar. 2023.

Gupta, a. K. *Et al.* Microneedling for hair loss. *Journal of cosmetic dermatology, [s. L.]*, v. 21, n. 1, p. 108–117, 2022. Disponível em: <https://search.ebscohost.com/login.aspx?direct=true&db=mdc&an=34714971&lang=pt-br&site=ehost-live>. Acesso em: 7 mar. 2023.

Ha, a. K. *Et al.* Original article: platelet-rich plasma with microneedling in androgenetic alopecia along with dermoscopic pre- and post-treatment evaluation. *Journal of cosmetic dermatology*, [s. L.], v. 17, n. 3, p. 313–318. 2018. Disponível em: <https://search.ebscohost.com/login.aspx?direct=true&db=mdc&an=28771982&lang=pt-br&site=ehost-live>. Acesso em: 7 mar. 2023

Lima, p. C. Q. M. C; brandão, b. J. F. Eflúvio telógeno agudo e alopecia areata associada a covid-19. *Bws journal*, v. 5, p. 1-9. 2022. Disponível em: [www.bwsjournal.emnuvens.com.br/bwsj/article/view/273/141](http://www.bwsjournal.emnuvens.com.br/bwsj/article/view/273/141). Acesso em: 15 abr. 2023.

Natário, juliana amorim alfaix *et al.* A queda capilar pode ser considerada uma das consequências da covid-19?. *Research, society and development*, v. 11, n. 1, p. E11911124935-e11911124935, 2022. Disponível em: <https://rsdjournal.org/index.php/rsd/article/download/24935/21731/292227>. Acesso em: 15 Abr. 2023.

Nguyen b.; tosti a. Alopecia in patients with covid-19: a systematic review and meta-analysis. *Pubmed*. V. 7, p. 67-77. 2022. Disponível em: <https://pubmed.ncbi.nlm.nih.gov/35224518/>. Acesso em: 20 abr. 2023.

Ocampo-garza, s. S. *Et al.* Micro needling: a novel therapeutic approach for androgenetic alopecia, a review of literature. *Dermatologic therapy*, [s. L.], v. 33, n. 6, p. E14267. 2020. Disponível em: <https://search.ebscohost.com/login.aspx?direct=true&db=mdc&an=32882083&lang=pt-br&site=ehost-live>. Acesso em: 7 mar. 2023.

Ogbuefi n.; erickson t.; mhlaba j. M. A case of rapid progression of central centrifugal cicatricial alopecia after covid-19 infection. *National library of medicine*, v. 29, p. 89-91. Disponível em: [https://www.ncbi.nlm.nih.gov/pmc/articles/pmc9458759/#:~:text=hair%20loss%20has%20been%20reported,and%20androgenetic%20alopecia%20\(aga\)](https://www.ncbi.nlm.nih.gov/pmc/articles/pmc9458759/#:~:text=hair%20loss%20has%20been%20reported,and%20androgenetic%20alopecia%20(aga)). Acesso em: 15 abr. 2023.

Ohyama, m.; matsudo, k.; fujita, t. Management of hair loss after severe acute respiratory syndrome coronavirus 2 infection: insight into the pathophysiology with implication for better management. *The journal of dermatology*, v. 49, n. 10, p. 939-947. 2022. Disponível em: <https://doi.org/10.1111/1346-8138.16475>. Acesso em: 7 abr. 2023.

Perelli, fernanda cristina; lucca, patricia stadler rosa. Distúrbios capilares pós covid-19 na cidade de iguatu-pr. *Research, society and development*, v. 11, n. 15, p. E273111537145-e273111537145. 2022. Disponível em: <https://rsdjournal.org/index.php/rsd/article/download/37145/30996/409416>. Acesso em: 15 abr. 2023.

Saki, n. *Et al.* Intermittent chronic telogen effluvium with an unusual dermoscopic finding following covid-19. *Clinical case reports*, v. 10, n. 8, p. E6228. 2022. Disponível em: <https://www.ncbi.nlm.nih.gov/pmc/articles/pmc9361802/>. Acesso em: 15 abr. 2022.

Santos, f. L. S.; fernandes, p. A.; ramos, m. J. Enzima tmprss2. *Rev. Ciência elem*, v.9, n. 04:065. 2021. Disponível em: <https://rce.casadasciencias.org/rceapp/art/2021/065/>. Acesso em: 15 abr. 2023.

Seyfi, s. Prevalence of telogen effluvium hair loss in patients with covid-19 and its relationship with disease severity. *Journal of medicine and life*, v. 15, n. 5, p. 1-6. 2022. Disponível em: <https://www.ncbi.nlm.nih.gov/pmc/articles/pmc9262270/#!po=56.250>. Acesso em: 15 abr. 2023.

Starace, m. *Et al.* Preliminary results of the use of scalp microneedling in different types of alopecia. *Journal of cosmetic dermatology*, v. 19, n. 3, p. 646–650. 2020. Disponível em: <https://search.ebscohost.com/login.aspx?direct=true&db=mdc&an=31254437&lang=pt-br&site=ehost-live>. Acesso em: 7 mar. 2023.

Talei, b.; shauly, o.; gould, d. Platelet rich plasma hybridized adiposetransplant (phat)for the treatment of hair loss: a case series. *Aesthetic plastic surgery*, v. 45, n. 6, p. 2760–2767. 2021. Disponível em: <https://search.ebscohost.com/login.aspx?direct=true&db=mdc&an=34236484&lang=pt-br&site=ehost-live>. Acesso em: 7 mar. 2023.

Vieira, talita aquira dos santos *et al.* Queda capilar em pessoas acometidas por covid-19: uma revisão de literatura. *Dermatologia: delineando a pesquisa clínica e preventiva*, v. 1, n. 1, p. 10-16, 2022. Disponível em: <https://www.editoracientifica.com.br/artigos/queda-capilar-em-pessoas-acometidas-por-covid-19-uma-revisao-de-literatura>. Acesso em: 15 abr. 2022.

Wambier, c. G. *Et al.* Androgen sensitivity gateway to covid-19 disease Severity. *Drug development research*, v. 81, n. 7, p. 771–776. 2020. Disponível em: <https://search.ebscohost.com/login.aspx?direct=true&db=mdc&an=32412125&lang=pt-br&site=ehost-live>. Acesso em: 26 mar. 2023.

Zhou, y. *Et al.* The effectiveness of combination therapies for androgenetic alopecia: a systematic review and meta-analysis. *Dermatologic therapy*, [s. L.], v. 33, n. 4, p. E13741, 2020. Disponível em: <https://search.ebscohost.com/login.aspx?direct=true&db=mdc&an=32478968&lang=pt-br&site=ehost-live>. Acesso em: 7 mar. 2023.