 <https://doi.org/10.56238/alookdevelopv1-151>

Tatiane Ribeiro de Morais

Academic of the medical course Federal University of Cariri

Harnowd Felipe Nogueira de Carvalho

Academic of the medical course Federal University of Cariri

Milena Maria Felipe Girão

Academic of the medical course Federal University of Cariri

Lucas Pereira Albuquerque

Academic of the medical course Federal University of Cariri

Metton Ribeiro Lopes e Silva

Graduated in Biomedicine specialist in Exfoliative Cytology and Oncohematology Laboratory Vicente Lemos/Crato-CE

Claudio Gleidiston Lima da Silva

Physician, Post-Doctorate from the ABC-SP Medical School (2016), in the area of concentration Collective Health
Professor at the Federal University of Cariri – UFCA

Maria do Socorro Vieira dos Santos

Veterinary Physician, Post-Doctorate from the Medical School of ABC-SP (2016), in the area of concentration Collective Health
Professor at the Federal University of Cariri – UFCA

ABSTRACT

Introduction: With the first case reported in 1970 in the Democratic Republic of Congo, the Monkeypox virus, belonging to the Poxviridae family, affected,

for many years, mainly the countries of West and Central Africa, with rare and self-limited outbreaks outside endemic areas. The increase in the number of cases registered in countries in Europe, the Americas, the Eastern Mediterranean and the Western Pacific in recent years has alerted the scientific community and culminated in the production of several studies on monkeypox. Objective: This study aimed to understand the risk factors and the epidemiological profile of the etiological agent. Methods: A literature review was performed using Public Medline, Scopus and Web of Science databases, adopting the descriptors “Monkeypox” and “Epidemiology”. Results: 366 articles related to the theme were found, of which, after applying the inclusion and exclusion criteria, 19 studies were selected to integrate this review. After an incubation period of approximately 2 weeks, the interruption of skin and mucosal integrity caused by the Monkeypox virus is often the first pathological manifestation in most patients, starting in a macular pattern and progressing to the formation of crusts. Other studies observed that systemic involvement was the majority as the first manifestation of the disease among their participants, especially those who performed receptive anal sex. Furthermore, men who have sex with other men, people who have sex with individuals affected by monkeypox or with people with risk factors for the development of STIs, were more likely to be infected by the Monkeypox virus, even though information about the infectivity of semen and vaginal secretions is insufficient. Conclusion: It is recommended to carefully examine any rashes in all patients, regardless of sex, gender or age.

Keywords: Epidemiology, Monkey, Smallpox.

1 INTRODUCTION

Monkeypox virus (MPX) is a zoonotic disease analogous to emerging severe smallpox, caused by the genus Orthopoxvirus (OPXV) (MAILHE et al., 2022; ADLER et al., 2022). It has lethality ranging from 1% to 10% depending on the region (ORVIZ et al., 2022; BIZOVÁ et al., 2022). Human-to-human transmission occurs by close contact with infectious material from skin lesions of an infected person, respiratory droplets in prolonged contact, and fomites (BIZOVÁ et al., 2022; Thornhill et al.,

2022). In addition, the known reservoir of MPX is believed to include rodents as well as great apes (PATEL et al., 2022).

The usual average incubation period of monkeypox ranges from 6 to 13 days, but can range from 5 to 21 days (BRITES et al., 2022). In addition, the symptomatology of MPX resembles the picture of smallpox, especially in severe cases, and include a febrile prodrome, lymphadenopathy and flu-like symptoms, followed by the development of multiple papular, vesicopustular and ulcerative lesions distributed throughout the body and face (THORNHILL et al., 2022; TARÍN-VICENTE et al., 2022).

The severity of monkeypox disease is determined by the route of exposure, the strain of the infecting virus, and the patient's immune status (PATEL et al., 2022). And as main complications of the pathology are observed secondary bacterial infections, encephalitis, dehydration and blindness due to the cicatricial processes by lesions in the cornea (THORNHILL et al., 2022; PATEL et al., 2022).

The first case of human MPX was reported in the Democratic Republic of the Congo in 1970, and subsequently with endemic circulation recorded in African regions, with a predominance in West and Central Africa (THORNHILL et al., 2022; HOFFMANN et al., 2022). Outbreaks occurring outside endemic areas were initially considered rare and self-limiting (MAILHE et al., 2022).

Several countries in Europe, the Americas, and regions of the Eastern Mediterranean and Western Pacific have reported a rapid increase in the number of cases of this disease among the population, with no evident epidemiological links to endemic areas (GIROMETTI et al., 2022). In addition, since May 2022 more than 16,000 cases of MPX and five deaths have been reported in more than 75 countries, prompting the World Health Organization (WHO) to declare MPX a "Public Health Emergency of International Concern" (SOUSA et al., 2022). The increase in the number of cases is mainly due to a combination of factors, which include increased exposure (deforestation and displacement), improved surveillance and diagnostic capacity (ORVIZ et al., 2022). Given the rapid spread of cases of monkeypox today, the study aims to review the epidemiological factors involved in the transmission of this pathology.

2 METHODS

This is a literature review in the databases Public Medline (PUBMED), Scopus and Web of Science, using the descriptors: "Monkeypox" and "Epidemiology", in addition to the Boolean operator AND.

The inclusion criteria were complete and fully available articles published in English, Portuguese and Spanish. In addition, we used case studies, cross-sectional study and cohort study (prospective and retrospective) that included patients in any age group with the diagnosis of

chickenpox by swab or blood test, with epidemiological characteristics presented. The exclusion criteria were articles that did not address the proposed topic, works written in languages other than those mentioned above, literature and/or systematic reviews, short communication, opinion article, research report, letter to the editor, and studies involving animal testing.

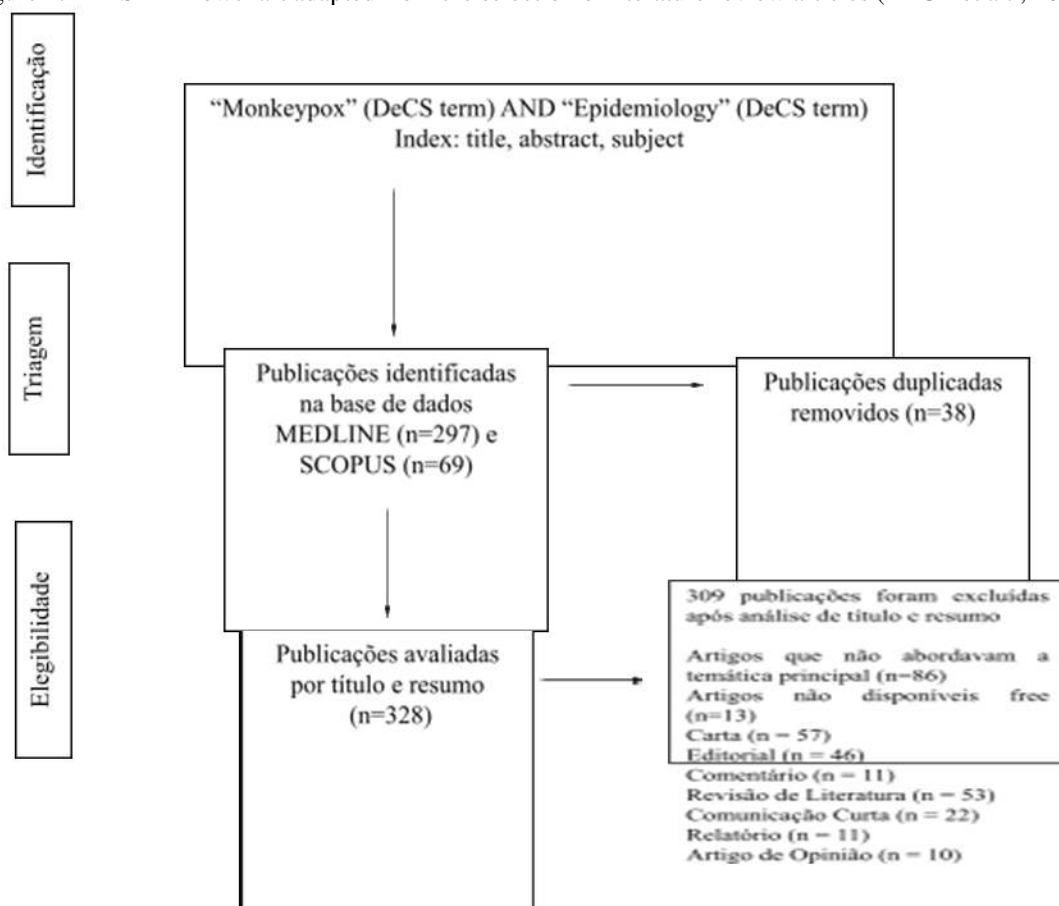
The selection of articles was performed by two independent evaluators and, in case of disagreements, a third examiner was called for the final consensus. The results were arranged in a spreadsheet, including year of publication, authors, databases and journals.

3 FINDINGS

The search strategy in the Medline and Scopus databases identified 366 publications. After the removal of 38 duplicate records, 328 were evaluated by reading titles and abstracts. In the end, 19 articles were included in the qualitative synthesis of the literature review and 309 did not meet the eligibility criteria.

Figure 1 presents the flowchart with the inclusion and exclusion criteria specified for the selection of studies according to the PRISMA (Preferred Reporting Items for Systematic Reviews and Meta-Analyses) model (PAGE et al., 2021).

Figure 1. PRISMA flowchart adapted from the selection of literature review articles (PAGE et al., 2021).



Incluídos

Publicações incluídas na
revisão qualitativa
(n=19)

The articles included in the literature review were classified according to the type of study as Observational Studies (9), Case Report (5), Case Series (4) and Cross-sectional Study (1). We identified 2,064 patients with a confirmed diagnosis of smallpox, of which approximately 99.07% were male and 0.87% were female. One patient was identified as trans or non-binary (THORNHILL et al. , 2022). Regarding the place of diagnosis of the patients, individuals were screened in 4 continents, the vast majority of them in Europe (2,042), and the remainder in America (19), Asia (2) and Oceania (1). The three countries that had the most confirmed cases of monkeypox in this literature review were Spain (45.34%), Germany (26.69%) and France (12.88%). Other information on author, year, location, type of study, sample, mean and age range, sample by sex and main results evidenced in the publications are gathered in Table 1.

Table 1. Characteristics of the articles included in the qualitative synthesis of the literature review.

Author and Year	Type of Study	Country	Sample	Main Findings
Adler et al., 2022	Observational Study	United Kingdom	4 men and 3 women	Four patients acquired smallpox from the monkeys outside the UK. Three patients acquired simian smallpox in the United Kingdom. A patient who acquired the virus abroad transmitted it to an adult and a child within their household. 5 patients were aged 30 to 40 years; 1 patient was 40 to 50 years old and 1 patient was less than 2 years old.
Bízová et al., 2022	Case Report	Czech Republic	1 man	The 34-year-old patient took a trip to Spain, where he had sex with same-sex partners five days before the appearance of an ulceration. Serologic testing was

				positive for syphilis. PCR and electron microscopy positive for monkeypox
Brites et al. , 2022	Series of Cases	Brasil	2 Women	A 37-year-old HIV-positive patient who travelled to Italy but denied close contacts on the trip. 14 days ago he received oral sex from an occasional partner. He did not use psychoactive substances and reported moderate alcohol consumption. Another patient, aged 31 years, reported moderate alcohol consumption. He has denied recent travel or sexual contact with new partners in the past 3 weeks.
Català et al. , 2022	Cross-sectional study	Spain	185 men	In this outbreak, cases have been reported in men who have sex with men (MSM) and are strongly associated with high-risk sexual behaviors. 76% of patients had other sexually transmitted diseases at screening. The mean age of the patients was 38 years.
Girometti et al. , 2022	Observational Study	Kingdom United	54 men	All patients were identified as MSM and two were bisexual. The mean age was 41 years. 38 of the 54 individuals were white, 8 were black or brown, 4 were Asian, and 4 were of other ethnicities. 48% were born in the UK and 24% lived with HIV. One in four patients had a concomitant STI.
Hoffmann et al. , 2022	Study	Germany	1 man	A 20-year-old patient returned to the United States from the United Kingdom and reported no sexual contact at the time. The first injury came about 14 days after he attended a large, crowded outdoor rave. He denied sexual contact in the previous 3 months. He had a history of syphilis treated 3 months before and was doing pre-exposure HIV prophylaxis.
Loconsole et al. , 2022	Observational Study	Italy	8 men and 2 women	Six patients were MSM. The mean age was 36.7 years. Nine individuals reported recent sexual exposure. One female subject without sexual exposure only reported participation in a social gathering.

Mailhe et al. , 2022	Study Observational	France	262 men and 2 women	In the study conducted 99% were men, 95% were men who have sex with men and 42% practiced chemsex in the last 3 months. The mean age was 35 years. In the research, 29% of the patients lived with HIV infection and 71% were taking pre-exposure prophylaxis against HIV infection. Overall, 47% had contact with a confirmed case of monkeypox.
Martínez et al. , 2022	Observational Study	Spain	508 men	Patients with a median age of 35 years. In the study, 84.1% reported condomless sex or sex with multiple partners in the 21 days prior to symptom onset, predominantly MSM (93%).
Mark; Miranda, 2022	Case Report	Brazil	1 man	The patient was a 41-year-old HIV-positive patient and had no history of travel abroad or to other Brazilian states, but reported unprotected sexual contact with a man. He underwent the last cycle of chemotherapy for the treatment of a diffuse large B-cell lymphoma with metastases in the spine, skull and liver less than 1 month ago.
Orviz et al., 2022	Study Observational	Spain	48 Men	Patients with a median age of 35 years. In the study, 87.5% of patients identified as MSM, 4.1% as bisexual men, 4.1% as homosexual sex workers, 2.1% as homosexual/bisexual men who used intravenous drugs, and 2.1% indicated sex only with cisgender women. A total of 25% of patients were vaccinated against smallpox in childhood. Regarding sexual intercourse, 89.5% of the patients had unprotected sex in the three weeks prior to the onset of symptoms
Patel et al. , 2022	Series of Cases	Kingdom United	197 men	In the study, 196 identified as gay, bisexual or other men who have sex with men. The median age was 38 years. Was reported that 35.9% of participants had concomitant HIV infection. .
Peiró-Masters et al. , 2022	Study Observational	Spain	12 Men	All patients studied were young adult men who have sex with men. The median age was 38.5 years. Most had a previous

				history of sexually transmitted infections (STIs), and three patients had a concomitant STI. Four were HIV positive. All patients were sexually active with up to 10 sexual partners during the last month and seven were on pre-exposure HIV prophylaxis. Three reported trips to other parts of Spain. Four patients reported previous sexual contact with a confirmed case of MPX.
Shah Et al., 2022a	Series of Case	Portugal	2 men	The patients had no pre-exposure vaccination against smallpox, nor a history of international travel in the last 3 months. One of them, a 34-year-old, reported 18 unprotected casual sexual contacts with men in the past 30 days. The other, 35 years old, reported 3 sexual contacts with men in the last 30 days. Both evolved to MPX complicated by deep skin infection.
Sousa et al. , 2022b	Report from Case	Portugal	1 man	A 24-year-old patient with no prior medical conditions, medication, or pre-exposure smallpox vaccination. He reported two sexual contacts in the past 30 days, with a woman and a man, asymptomatic to his knowledge.
Sukhdeo et al. , 2022	Case Report	Canada	1 man	The study reported a 33-year-old patient who 21 days before the onset of symptoms had unprotected and receptive orogenital and oroanal intercourse with a new anonymous male partner.
Tarin-Vincent et al. , 2022	Study Observational	Spain	175 men and 6 women	In the study, 92% were identified as gay men, bisexual men or other MSM and 8% identified as straight men or straight women. The median age was 37 years. It was reported that 32 patients reported previous smallpox vaccination, 72 were HIV positive, 31 were diagnosed with sexual infection concomitant with the transmitted infection.
Thornhill et al. , 2022	Series of Cases-	United Kingdom (5), Germany (5), Italy (5), Spain (2),	527 trans or not and 1 torque	Overall, 98 percent of those with infection were gay or bisexual men, 75 percent were white, and 41 percent had human

		Belgium (2), France (2), Switzerland (2), Denmark (1), Portugal (1), Netherlands (1), United States (2), Canada (10), Mexico (1), Argentina (1), Israel (2) and Australia (1).		immunodeficiency virus infection. The median age was 38 years. Transmission was suspected to have occurred through sexual activity in 95% of people with infection. Concomitant sexually transmitted infections were reported in 109 of the 377 people who were tested.
--	--	--	--	---

4 DISCUSSIONS

It is of paramount importance to understand the epidemiological and clinical characteristics of the current outbreak of monkeypox, considering that through epidemiological knowledge strategies are outlined to limit the spread of diseases. Regarding the clinical pattern, in previous outbreaks an incubation period of 5 to 21 days was described, with febrile prodrome of 8 to 12 days and later painful and itchy eruptions in 2 days. The lesions were initially characterized as macules, but then turned into papules, vesicles, pustules, and finally crusts. In addition, the disease mainly affected children (SUKHDEO et al., 2022; PATEL et al., 2022).

In contemporary times, it was noted, an incubation period of around two weeks (ADLER et al., 2022). According to a study conducted at the Bichat Claude Bernard university hospital, there was a lower frequency of systemic and dermatological signs, as well as a predominance of lesions in the oral, genital and anal mucosa (MAILHE et al., 2022). Moreover, it is important to report that most patients presented as their first symptoms the interruption of the cutaneous-mucosal integrity to the detriment of the fever and rash observed in the epidemics previously described (ORVIZ et al., 2022). It is also noteworthy that dermatological manifestations may assimilate to those caused by other etiologies, such as syphilis, herpes simplex, folliculitis or molluscum contagiosum (SUKHDEO et al., 2022).

It is worth noting the occurrence of a case in California of a patient with infection by the disease in question who did not present systemic or dermatological manifestations. Your The main risk factor for contamination was related to non-sexual inter-human contact with numerous people outdoors. This case highlights the potential transmission by fomites in an alternative way in the general population (KARAN et al., 2022; LOCONSOLE et al., 2022). However, in a study produced in Spain, it was observed that systemic symptoms were quite common being present as an initial phase of the disease in most of the research participants. It should be noted that the vast majority of individuals had previous sexual exposure to a partner who had monkeypox or who have risk factors for sexually transmitted infections (STIs). In addition, members who reported anal-receptive sex more frequently had early

systemic symptoms before developing the skin lesions compared to the other participants (TARÍN-VICENTE et al. , 2022; CATALÀ et al. , 2022; HOFFMANN et al. , 2022).

According to an analysis generated in Madrid in 2022, the current outbreak has affected adults with a median age of 35 years, most of whom are men who have sex with men (MSM). It should be noted that in the 21 days prior to the onset of symptoms, half of the individuals had practiced sex under the influence of psychoactive drugs with multiple partners for several hours or days (ORVIZ et al. , 2022). On the other hand, in a study conducted in the United Kingdom in the same year, the mean age of 41 years was perceived, with all MSM patients having high rates of STIs (GIROMETTI et al., 2022).

In line with the information previously highlighted, another epidemiological study conducted in Madrid showed that 99% of the cases confirmed by monkeypox affected MSM with a median age of 35 years, in addition to a predominance of lesions in the genital, perineal and inguinal lymphadenopathy regions. This study also attested that a high percentage of individuals had exposure to multiple partners without the use of condoms (MARTÍNEZ et al., 2022).

These characteristics reinforce the strong probability of sexual transmission, considering that the mucosal lesions mentioned above may represent the site of virus inoculation. However, there is insufficient information to support that semen or vaginal secretions are capable of functioning as a means of transmission. It is assumed that group sexual practices at parties or saunas in association with the use of psychotropic substances highlight the potential for transmission of the pathology by sexual contact (THORNHILL et al. , 2022; MAILHE et al., 2022; PEIRÓ-MESTRES et al., 2022).

Nowadays, close contact with injuries, contact with body fluids during sexual activity, especially between MSM or bisexuals, and contaminated materials are transmission routes with a higher index of suspicion. (HOFFMANN et al. , 2022; BRITES et al. , 2022; SOUSA et al. , 2022¹). Therefore, sexual practice with multiple partners and in the presence of psychoactive drugs, in addition to the associated diagnosis of STI are framed as agents of relevance for modifying the pattern of spread of the disease (TARÍN-VICENTE et al. , 2022; BÍŽOVÁ et al. , 2022).

In addition, children, pregnant women, nursing mothers, or immunosuppressed people may be at increased risk of disease severity, although they do not manifest themselves so far in the current outbreak (ADLER et al. , 2022; BRITES et al. , 2022). It should be noted that well-controlled human immunodeficiency virus (HIV) infection and smallpox vaccination were not related to severity indices (MARTÍNEZ et al., 2022; CATALÀ et al. , 2022).

Corroborating with the risks of severity previously described, an important presentation was reported in a patient with recent HIV infection, where he had his condition aggravated by dysfunction of the immune system secondary to the aforementioned acute disease not treated (SOUSA et al. , 2022²). Moreover, the first death reported in Brazil occurred in an immunosuppressed individual due

to chemotherapy treatment for diffuse large B-cell lymphoma with metastases in the skull, liver and spine (MENEZES et al. , 2022).

It is relevant to highlight that although the current outbreak mainly affects MSM or bisexuals with multiple partners or with lifestyle habits at risk for STIs, monkeypox can affect anyone without distinction of gender or sexual option (CATALÀ et al. , 2022). Caution is recommended when examining unusual rashes in any patient, specifically if concomitant with systemic symptoms (THORNHILL et al., 2022). This time, it is essential to balance health promotion aimed at groups that are unequally affected, as well as to consider when classifying this outbreak as sexually transmitted, since this virus is propagable by close contact and not purely in sexual circumstances (GIROMETTI et al., 2022; ORVIZ et al. , 2022).

5 CONCLUSION

Most of the articles included in this review highlight the factor of sexual contact as a possible cause of some of the outbreaks caused by the Monkeypox virus. In addition, the type of sexual contact may influence the pattern of evolution of monkeypox, especially in the initial symptomatology of the disease. Therefore, despite the relative lack of information about the transmissibility of the etiologic agent via semen or vaginal secretion, prophylactic measures should be implemented with the aim of alerting possible risk groups to the high probability of sexual transmission. In this sense, the identification of new risk groups becomes of fundamental importance to direct health education actions aimed at reducing transmission via sexual contact. Despite the identification of the epidemiological pattern of the virus in the studies, it should be emphasized that the prophylaxis of monkeypox should be directed to the general population, since sexual contact is presented only as an aggravating factor for the infection of new individuals. The possibility of children and pregnant women presenting themselves as risk groups reinforces the idea that prophylactic measures should not focus exclusively on care during sexual practices, in addition to evidencing the need for further studies on the subject.

ACKNOWLEDGMENT

To the Vicente Lemos Laboratory for its support and encouragement.

REFERENCES

- Adler, hugh et al. Clinical features and management of human monkeypox: a retrospective observational study in the uk. *The lancet infectious diseases*, [s.l.], v. 22, n. 8, p. 1153-1162, ago. 2022. Elsevier bv. [Http://dx.doi.org/10.1016/s1473-3099\(22\)00228-6](http://dx.doi.org/10.1016/s1473-3099(22)00228-6).
- Bížová, beatrice et al. Coinfection of syphilis and monkeypox in hiv positive man in prague, czech republic. *Travel medicine and infectious disease*, [s.l.], v. 49, p. 102368, set. 2022. Elsevier bv. [Http://dx.doi.org/10.1016/j.tmaid.2022.102368](http://dx.doi.org/10.1016/j.tmaid.2022.102368).
- Brites, carlos et al. The first two cases of monkeypox infection in msm in bahia, brazil, and viral sequencing. *Viruses*, [s.l.], v. 14, n. 9, p. 1841, 23 ago. 2022. Mdpi ag. [Http://dx.doi.org/10.3390/v14091841](http://dx.doi.org/10.3390/v14091841).
- Català, alba et al. Monkeypox outbreak in spain: clinical and epidemiological findings in a prospective cross sectional study of 185 cases*. *British journal of dermatology*, [s.l.], v. 187, n. 5, p. 765-772, 20 ago. 2022. Wiley. [Http://dx.doi.org/10.1111/bjd.21790](http://dx.doi.org/10.1111/bjd.21790).
- Girometti, nicolò et al. Demographic and clinical characteristics of confirmed human monkeypox virus cases in individuals attending a sexual health centre in london, uk: an observational analysis. *The lancet infectious diseases*, [s.l.], v. 22, n. 9, p. 1321-1328, set. 2022. Elsevier bv. [Http://dx.doi.org/10.1016/s1473-3099\(22\)00411-x](http://dx.doi.org/10.1016/s1473-3099(22)00411-x).
- Hoffmann, christian et al. Clinical characteristics of monkeypox virus infections among men with and without hiv: a large outbreak cohort in germany. *Hiv medicine*, [s.l.], v. 4, n. 2, p. 15-25, 4 set. 2022. Wiley. [Http://dx.doi.org/10.1111/hiv.13378](http://dx.doi.org/10.1111/hiv.13378).
- Karan, abraar et al. Human monkeypox without viral prodrome or sexual exposure, california, usa, 2022. *Emerging infectious diseases*, [s.l.], v. 28, n. 10, p. 2121-2123, out. 2022. Centers for disease control and prevention (cdc). [Http://dx.doi.org/10.3201/eid2810.221191](http://dx.doi.org/10.3201/eid2810.221191).
- Loconsole, daniela et al. Monkeypox virus infections in southern italy: is there a risk for community spread?. *International journal of environmental research and public health*, [s.l.], v. 19, n. 18, p. 11719, 17 set. 2022. Mdpi ag. [Http://dx.doi.org/10.3390/ijerph191811719](http://dx.doi.org/10.3390/ijerph191811719).
- Mailhe, morgane et al. Clinical characteristics of ambulatory and hospitalized patients with monkeypox virus infection: an observational cohort study. *Clinical microbiology and infection*, [s.l.], v. 4, n. 2, p. 5-15, ago. 2022. Elsevier bv. [Http://dx.doi.org/10.1016/j.cmi.2022.08.012](http://dx.doi.org/10.1016/j.cmi.2022.08.012).
- Martínez, jesús iñigo et al. Monkeypox outbreak predominantly affecting men who have sex with men, madrid, spain, 26 april to 16 june 2022. *Eurosurveillance*, [s.l.], v. 27, n. 27, p. 327-347, 7 jul. 2022. European centre for disease control and prevention (ecdc). [Http://dx.doi.org/10.2807/1560-7917.es.2022.27.27.2200471](http://dx.doi.org/10.2807/1560-7917.es.2022.27.27.2200471).
- Menezes, yargos rodrigues et al. Severe disseminated clinical presentation of monkeypox virus infection in an immunosuppressed patient: first death report in brazil. *Revista da sociedade brasileira de medicina tropical*, [s.l.], v. 55, p. 327-337, 2022. Fapunifesp (scielo). [Http://dx.doi.org/10.1590/0037-8682-0392-2022](http://dx.doi.org/10.1590/0037-8682-0392-2022).

Orviz, eva et al. Monkeypox outbreak in madrid (spain): clinical and virological aspects. *Journal of infection*, [s.l.], v. 85, n. 4, p. 412-417, out. 2022. Elsevier bv. [Http://dx.doi.org/10.1016/j.jinf.2022.07.005](http://dx.doi.org/10.1016/j.jinf.2022.07.005).

Page, matthew j et al. Prisma 2020 explanation and elaboration: updated guidance and exemplars for reporting systematic reviews. *Bmj*, [s.l.], n160, 29 mar. 2021. *Bmj*. [Http://dx.doi.org/10.1136/bmj.n160](http://dx.doi.org/10.1136/bmj.n160).

Patel, aatish et al. Clinical features and novel presentations of human monkeypox in a central london centre during the 2022 outbreak: descriptive case series. *Bmj*, [s.l.], p. 410-440, 28 jul. 2022. *Bmj*. [Http://dx.doi.org/10.1136/bmj-2022-072410](http://dx.doi.org/10.1136/bmj-2022-072410).

Peiró-mestres, aida et al. Frequent detection of monkeypox virus dna in saliva, semen, and other clinical samples from 12 patients, barcelona, spain, may to june 2022. *Eurosurveillance*, [s.l.], v. 27, n. 28, p. 327-346, 14 jul. 2022. European centre for disease control and prevention (ecdc). [Http://dx.doi.org/10.2807/1560-7917.es.2022.27.28.2200503](http://dx.doi.org/10.2807/1560-7917.es.2022.27.28.2200503).

Sousa², diogo de et al. Human monkeypox coinfection with acute hiv: an exuberant presentation. *International journal of std & aids*, [s.l.], v. 33, n. 10, p. 936-938, 13 jul. 2022. Sage publications. [Http://dx.doi.org/10.1177/09564624221114998](http://dx.doi.org/10.1177/09564624221114998).

Sousa¹, diogo de et al. Monkeypox infection and bacterial cellulitis: a complication to look for. *International journal of infectious diseases*, [s.l.], v. 123, p. 180-182, out. 2022. Elsevier bv. [Http://dx.doi.org/10.1016/j.ijid.2022.08.024](http://dx.doi.org/10.1016/j.ijid.2022.08.024).

Sukhdeo, sharon s. Et al. A case of human monkeypox in canada. *Canadian medical association journal*, [s.l.], v. 194, n. 29, p. 1031-1035, 6 jul. 2022. Cma impact inc.. [Http://dx.doi.org/10.1503/cmaj.220886](http://dx.doi.org/10.1503/cmaj.220886).

Tarín-vicente, eloy josé et al. Clinical presentation and virological assessment of confirmed human monkeypox virus cases in spain: a prospective observational cohort study. *The lancet*, [s.l.], v. 400, n. 10353, p. 661-669, ago. 2022. Elsevier bv. [Http://dx.doi.org/10.1016/s0140-6736\(22\)01436-2](http://dx.doi.org/10.1016/s0140-6736(22)01436-2).

Thornhill, john p. Et al. Monkeypox virus infection in humans across 16 countries — april–june 2022. *New england journal of medicine*, [s.l.], v. 387, n. 8, p. 679-691, 25 ago. 2022. Massachusetts medical society. [Http://dx.doi.org/10.1056/nejmoa2207323](http://dx.doi.org/10.1056/nejmoa2207323).