 <https://doi.org/10.56238/ciesaudesv1-119>

Alana Valéria Matos Besteiro

Roberto Freitas de Castro Leão

Ana Catarina Mattos Fernandes

Tássio Cruz Xavier

Cantídio João Silva da Trindade Júnior

Vitor Hugo Auzier Lima

RESUMO

This research aimed to report the prevalence of conjunctival tumors, and their severity between genders, age groups, and to observe the distribution of their laterality in patients of a public health service in Belém do Pará, in the Eastern Amazon, Brazil. Methods: Data were collected at the Bettina de Souza Ferro University Hospital from 253 medical records from the last 12 years (2010 to 2022) regarding conjunctival tumors that were removed and histopathologically examined by the Department of Ophthalmology of the Federal

University of Pará (UFPA). The incidence of tumors submitted to excision surgery, the rate of malignancy, and margins were investigated, and matched with gender, age, and laterality. Results: The subjects included 161 men and 92 women, with a mean age of 49.4 ± 47.2 years. Of these 193 were benign tumors (76.3%), being the most banally found - 99 Pterygium; followed by 28 Squamous Cell Carcinomas; 24 Granulomas, Pyogenic; 20 Intraepithelial Neoplasia and 18 Squamous Papilloma. Among the 31 cases (23.7%) of malignant tumors, the number of male patients was 21 and 10 females. Most malignant tumors were composed of squamous cell carcinoma (28 cases), followed by melanoma (3 cases). The mean age of patients with malignant tumors removed was 65.0 ± 31 years, since in older patients malignant tumors were more prevalent (chi-square, $p < 0.001$). Conclusions: The most common conjunctival tumors were pterygia and squamous cell carcinomas, more present in male patients, younger and older, respectively.

Palavras-Chave: Conjunctival Tumor, Gender, Age, Malignancy, Laterality.

1 INTRODUÇÃO

Conjunctival tumors are a group of essentially ophthalmic pathologies (SHIELDS & SHIELDS, 2019). Among these, benign tumors are more frequent than malignant, with their proportions increasing with aging (ESLAMI, 2018). And taking primarily the complex structure of the conjunctiva, eventually it is understood most of the tumors (benign and malignant) that occur in this site (BIZARRO, 2014). Because the conjunctiva is composed of a membrane of mucous aspect, and it is a tissue adjacent to the eye, which has the function of covering, anteriorly, the outermost region of the eye, known as the conjunctiva of the bulbar region, and, behind the eyelids, called the conjunctiva of the eyelid region (KANSKI, 2019; HÖFLING, DANTAS & ALVES, 2016), whose main functions contribute, above all, to the composition of the tear film, synthesizing mucus. The conjunctival lining, in parallel, with excreted secretions, makes up a relevant barrier against infections (viruses, fungi and bacteria) and foreign bodies (HIRT, 2022; BAEK, 2005).

Regarding its histology, the conjunctiva of the eyes is characterized by a stratified columnar epithelium without keratin, with columnar cells in the form of mixed calyces, formed by 2 to 5 layers of cells, supported on a basement membrane, while its stroma, containing blood and lymphatic vessels, as well as nerves, is composed of fibrovascular tissue of conjunctive origin (BAEK, 2005). Eventually, neoplastic cells may arise in the conjunctiva from their epithelial and stromal structures. When they multiply anomalously they become similar, clinically and histopathologically, to tumors that arise from other mucous membranes of the body. However, unlike other mucous membranes in the body, the conjunctiva is partially exposed to sunlight, which may be a factor in the development of some tumors (SHIELDS & SHIELDS, 2019).

The conjunctiva of the eyes, eventually, is injured by several small injuries and damages of the most different causes, such as degenerative damage; circulatory; inflammation; which can lead to tumors in this tissue. If these damages become mutagenic, they may be blamed, not only for more urgent vision injuries, but also for a fatality. These conjunctival tumors are didactically divided into malignant tumors (more severe), pre-malignant and benign, the less severe (NANJI et al., 2017). Other studies, similar in other populations, have also described the histological types of ocular tumors, and, among these, conjunctiva tumors are the most frequently found, corresponding to about 44.28% of cases (DE ALMEIDA & FERREIRA, 2019)

And even though, mostly, the lesions diagnosed, without much difficulty, are demystified clinically, they are, soon after, surgically removed (MIYANO, 2021; BAEK, 2005), however it is difficult, eventually, only by clinical observation, to differentiate malignant tumors, that is, a histopathological evaluation is imperative for a more assertive conclusive diagnosis (ESLAMI, 2018). Bearing in mind that the incidence of malignant tumors is divergent among ethnic-racial groups, nations, and, within these localities, still, dependent on the genetic composition of the individuals of these populations; socioeconomic status; accessibility to health services, and epidemiological understanding of tumor lesion rates, parameters that guide physicians' final decisions (HIRT, 2022; MIYANO, 2021), moreover, scarce are the researches that are published and that carry epidemiological data about conjunctival tumors (BIZARRO, 2014). Much of the research reported advocates the work of researchers who have been concerned with the prevalence of the most diverse groups of ocular tumors, and few are those who seek to study their clinical-pathological correlation specifically of conjunctival malignant tumors (ESLAMI, 2018; BIZARRO, 2014).

Considering that conjunctival tumors almost always develop slowly and their signs and symptoms are not specific; and their carriers avoid seeking clinical help, to try an evaluation for a more accurate diagnosis, suggesting that the estimated prevalence of these groups of tumors is greatly underestimated (BAEK, 2005). However, this information obtained demonstrates the importance of

knowing the epidemiological profile about this diagnostic suspicion and requires an early conduct of ophthalmic practice (MIYANO, 2021).

Therefore, the relevance of this research is due, on the one hand, to the scarcity of epidemiological information about conjunctival tumors, and also to its clinical-pathological interconnection, especially with the Brazilian Amazon, in addition to, on the other hand, the prevalence of conjunctival tumors have increased in the last decade (BIZARRO, 2014). This added to the insufficiency of data, especially with regard to the Brazilian population, regarding the incidence of malignant primary ocular tumors, hindering the advent of new strategies of secondary prophylaxis and brevity in the diagnosis of the pathology, as well as hindering the elucidation of the major sociodemographic and epidemiological indicators investigated by health professionals when they suspect plausible impairments in individuals at higher risk. Considering that a delayed diagnosis of the disease incurs a bad outcome that corroborates in the loss of his vision and/or removal of his eyeball and adjacent regions, restricting not only hylically the patient, but also his biopsychosocial well-being (MIYANO, 2021; AMARO, 2006). For these pretexts, the attempt was made to obtain more statistical data on the frequency of the most divergent typologies of conjunctival tumors in the population of the Brazilian Amazon and to investigate the clinical-pathological relationship, under the gaze of ophthalmic pathology, that is, in an abundant contingent of cases, and in a determined period of time. Thus, this research aimed to collect these data to inform the incidence of the most diverse types of conjunctival tumors; as well as reflecting on the epidemiological characteristics, such as age, gender and clinic, which permeates anatomical location; and also to investigate the differences possibly found in the largest groups of conjunctival tumors, regarding the variables analyzed in this research.

2 METHODOLOGY

2.1 SEARCH LOCATION

The research was conducted in the Department of Ophthalmology, Hospital Universitário Bettina Ferro de Souza, in Belém-PA, after authorization from the management of the same hospital and approval from the Ethics Committee for Research on Human Beings of UFPA (CEP-UFPA).

2.2 ACCEPTANCE OF ORIENTATION

The project was submitted to the appreciation of the CEP-UFPA and after the acceptance of the advisor Dr. Roberto Leão, expressed by signing the term of Guidance accepted.

2.3 ETHICAL PRECEPTS

This study was conducted in compliance with research standards involving human beings (Res. CNS 466/12) of the National Health Council After authorization of the project by the direction of the University Hospital, accepted by the advisors and approval of the Human Research Ethics Committee of UFPA. As it was the collection of information from the medical record, it was requested to release of the use of a free and informed consent form.

2.4 METHODOLOGY USED

As a methodological design, we used a standard form prepared by the authors of the project, containing information that was collected, through an online data collection protocol, from 253 medical records, in the year 2022, to perform the statistics of the same, the variables are gender, age, tumor laterality, whether malignant or benign, according to the classification already established by the local service, which histological type of the conjunctival tumor, as well as whether it has a surgical safety margin described.

2.5 TYPE OF STUDY AND SAMPLE

The project was retrospective, cross-sectional, and was based on describing changes found in the histopathological report, as well as evaluating the data of gender, age, tumor laterality and clinical characteristics, in the period from 2010 to 2022.

2.6 INCLUSION CRITERIA

Patients who underwent surgery for excision of conjunctival tumor in the period from 2010 to 2022.

2.7 EXCLUSION CRITERIA

Patients whose histopathological report confirmed a non-neoplastic lesion. And in this study, medical records and injuries were not included/excluded, but people (patients) were included/excluded. Therefore, always the human being, and not his disease or his medical record were taken into account.

2.8 DATA STORAGE, CONSOLIDATION, AND ANALYSIS

The collected data (gender, age group, histopathological diagnosis, laterality and tumor location) were stored in databases and subsequently submitted to comparative statistical analysis. The results were compared with those observed in the literature on the subject. According to the nature of

the variables, descriptive statistical analysis was applied, and the percentage values of the analyzed data were then informed. For the statistical analysis of the differences between the proportions, didactically, the Chi-square test was used, with level α : 0.05 (5%), with the aid of the BioEstat 5.5 software. And the value of $p < 0.05$ was accepted as a significant difference.

In the operationalization stage, the data were organized in the Microsoft Excel 2010 program. The graphs and tables were constructed with the tools available in Microsoft Word, Excel and Bioestat 5.5. All tests were performed with the aid of Bioestat 5.5 software. Quantitative variables were described by minimum, maximum, and mean and qualitative variables by frequency and percentage. 95% confidence intervals were calculated for the proportion to infer how the prevalences behaved in relation to the population from which they were obtained. The independence or association between two categorical variables was tested by the chi-square test. Results with $p \leq 0.05$ (bilateral) were considered statistically significant.

2.9 BENEFITS

Regarding the benefits of this research, we can mention the epidemiological identification of conjunctiva tumors in the Amazon region, in the north of Brazil, contributing to the scientific study and early diagnosis of these pathologies.

2.10 RISKS

To the participants, the risk of leakage of their identities. As a way to minimize it, the identities of the patients were kept in absolute secrecy and the information collected was presented in the set, and not individually, serving, only, for scientific purposes, but the participants were informed about it. The participants were not identified by names, and for this purpose alphanumeric codes referring to each participant in the sample were used.

3 FINDINGS

After the analysis of the medical records, they were organized, analyzed, didactically, converted into the graphs, and the following statistics were made. In which they were divided into 2 sessions, a session of characterization of the samples, in which the absolute values and percentages of gender, age group, type of tumor, number of surgeries undertaken, laterality, and severity of the tumor were observed. In addition to another session in which an association was made between the results obtained in the categories of gender, age, histological types, and laterality, for a more accurate analysis of the profile.

And as can be observed in the session (5.1), below, the study sample was quite balanced, composed only by binary genders (female and male), and with 5 age groups (ranging from 2 to 96 years), as can be observed below:

3.1 SAMPLE CHARACTERIZATION

A total of 253 records were obtained. Most patients (161 or 63.6%) were male. In the sample, 33.6% of the individuals were aged between 40 and 59 years and 32.4% were elderly (Table 1). Ages ranged from 2 to 96 years, with a mean of 49.6 years.

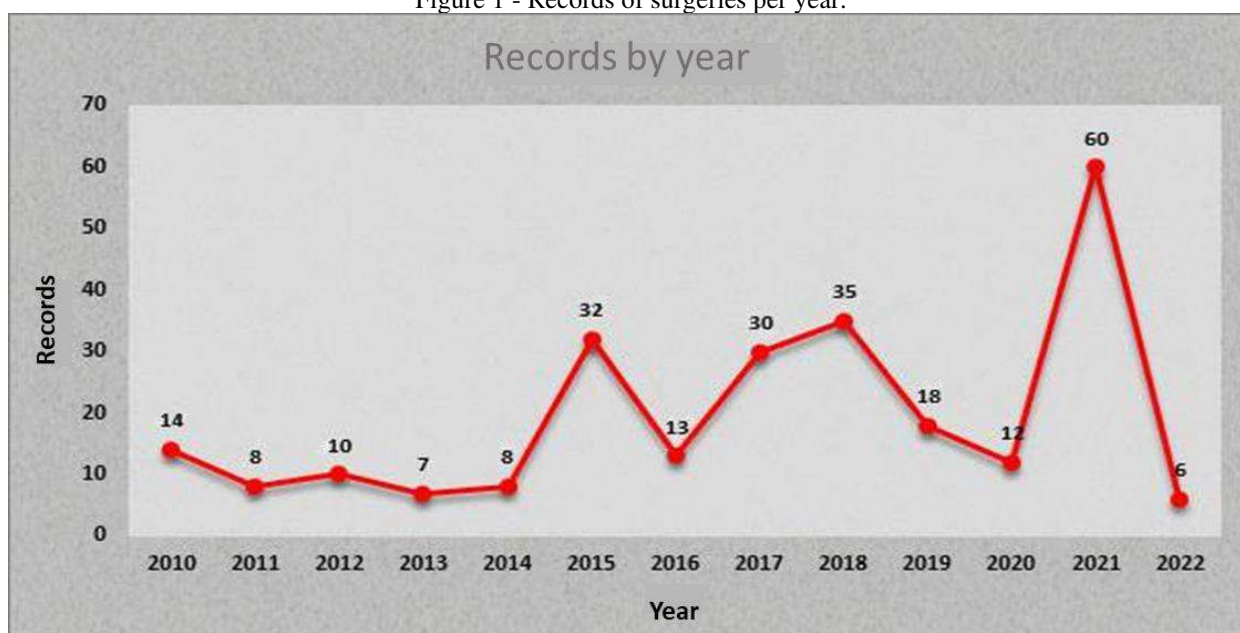
Table 1 - Sociodemographic characteristics of patients undergoing conjunctival tumor exeresis surgery at Hospital Universitário Bettina de Souza Ferro, from 2010 to 2022, Belém-Pará.

Variable	Frequency	Percentage
Sex		
Female	92	36,4
Male	161	63,6
Age		
Of 2 to 19 years	23	9,1
Of 20 to 39 years	57	22,5
Of 40 to 59 years	85	33,6
Of 60 to 96 years	82	32,4
Not Informed	6	2,4

The percentages are relative to the total number of records (n=253).

Figure 1 shows the total records of surgeries per year (2010-2022). And it was observed that the highest number of cases occurred in 2021 (60 records).

Figure 1 - Records of surgeries per year.



When analyzing the prevalence of laterality, it was noticed that 119 (47%) patients had a diagnosis in the right eye, similar to the proportion in the left eye (45.5%). Regarding the severity of the tumor, it can be noted that most (193 or 76.3%) had a benign tumor. To access the generalizability of the prevalences, 95% confidence intervals (95%CI) were calculated for the proportion, represented below. And the narrower this interval, the greater the certainty related to that proportion in the population from which this sample was obtained (Table 2).

Table 2 - Prevalence of laterality and malignancy in patients undergoing surgery for excision of conjunctival tumor at Hospital Universitário Bettina de Souza Ferro, from 2010 to 2022, Belém-Pará.

Variable	Frequency	Percentage	95% CI*
Laterality			
Left Eye	115	45,5	39,2 - 51,8
Right Eye	119	47,0	40,8 - 53,4
Not Informed	19	7,5	4,7 - 11,7
Malignancy			
Benign	193	76,3	70,5 - 81,3
Pre-Malignant	24	9,5	6,3 - 14,0
Malignant	36	14,2	10,3 - 19,3

*95%CI: 95% confidence interval for prevalence. The percentages are relative to the total number of records (n=253).

In the histopathological analysis, 39.1% of the individuals had pterygium, followed by squamous cell carcinoma (in 11.1%) and pyogenic granuloma (9.5%, Table 3). 20 patients had a record of compromised margins, and of these, 16 (80%) had histopathological type squamous cell carcinoma, one person (5% of 20 patients) had intraepithelial neoplasia, two (or 10%) had melanoma and one had mucoepidermoid carcinoma. 9 patients had free margins, of which two (22.2%) had squamous cell carcinoma, one had intraepithelial neoplasia, three (33.3%) had melanocytic nevus, one had pseudoepitheliomatous hyperplasia, one had conjunctival melanoma and one had conjunctival compound nevus.

Table 3 - Prevalence of histopathological examination results in patients undergoing conjunctival tumor exeresis surgery at the Bettina de Souza Ferro University Hospital, from 2010 to 2022, Belém-Pará.

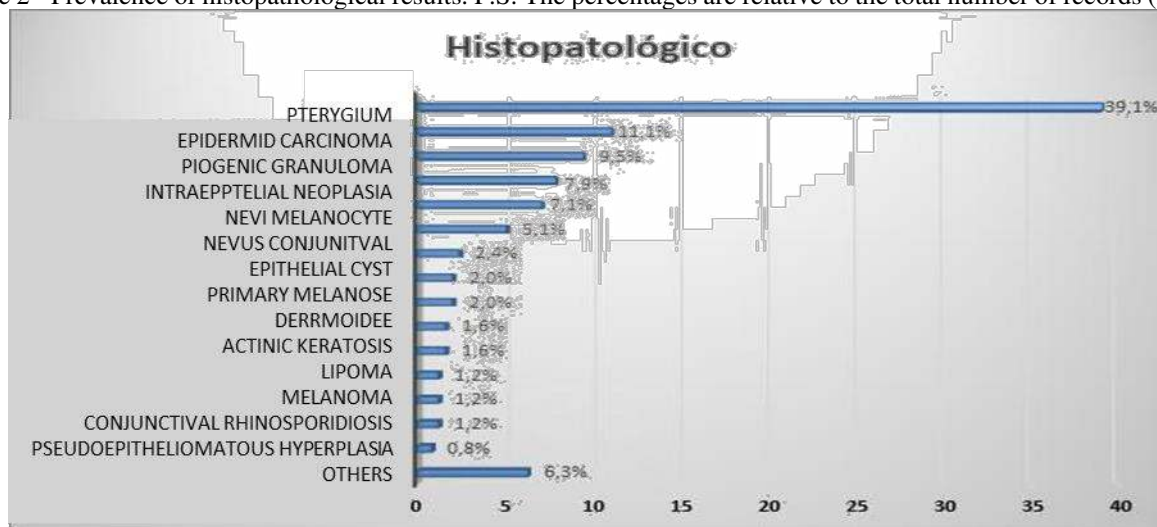
Variable	Frequency	Percentage	IC95%
Histopathology			
Pterygium	99	39,1	33,1 - 45,5
Squamous cell carcinoma	28	11,1	7,6 - 15,8
Granuloma Piogênico	24	9,5	6,3 - 14,0
Intraepithelial Neoplasia	20	7,9	5,0 - 12,1
Scaly Papilloma	18	7,1	4,4 - 11,2
Nevo Melanocítico	13	5,1	2,9 - 8,8
Conjunctival nevus	6	2,4	1,0 - 5,3
Epithelial Cyst	5	2,0	0,7 - 4,8
Primary Melanosis	5	2,0	0,7 - 4,8
Leatherette	4	1,6	0,5 - 4,3
Actinic keratosis	4	1,6	0,5 - 4,3
Lipoma	3	1,2	0,3 - 3,7
Melanoma	3	1,2	0,3 - 3,7

Conjunctival rhinosporidiose	3	1,2	0,3 – 3,7
Pseudoepitheliomatous hyperplasia	2	0,8	0,1 – 3,1
Other	16	6,3	3,8 - 10,3

* 95%CI: 95% confidence interval for prevalence. Findings cited only once were grouped into "other". The percentages are relative to the total number of records (n=253).

Figure 2 below shows these results from Table 3, graphically.

Figure 2 - Prevalence of histopathological results. P.S: The percentages are relative to the total number of records (n=253).



3.2 ASSOCIATION BETWEEN HISTOLOGICAL TYPES, GENDER, AGE AND LATERALITY

Subsequently, factors related to the most prevalent pathological types were evaluated. For example, in females, most (40 or 61.5%) had pterygium histopathology, in the male group, 47.6% of individuals also had pterygium histopathology. However, these differences observed were not significant ($p=0.322$), that is, there was no significant association between the most frequent histological types and the sex of the patients (Table 4).

Table 4 - Association between gender and the main histological types of patients undergoing surgery for excision of conjunctival tumor at the Bettina de Souza Ferro University Hospital, from 2010 to 2022, Belém-Pará.

Variable	Female (n=65)	Male (n=124)	p- value
Histopathology			0,322
Pterygium	40 (61,5)	59 (47,6)	
Squamous cell carcinoma	9 (13,8)	19 (15,3)	
Granuloma Piogênico	8 (12,3)	16 (12,9)	
Intraepithelial Neoplasia	4 (6,2)	16 (12,9)	

Categorical variables are displayed as n (%). The percentages are relative to the total of each column. The chi-square test was used for this analysis.

The analyzed parameters of Age and histopathology were significantly associated ($p < 0.001$): at the age of 40 to 59 years, 64.8% were of the pterygium histopathology, and this proportion was higher than expected by the statistical test; of the individuals aged 60 to 96 years, 18 (25.7%) had histopathological squamous cell carcinoma, and this proportion was higher than expected by the statistical test; of individuals aged 2 to 19 years, 2 (50%) had pyogenic granuloma, and this proportion was higher (†) than expected; of the individuals aged 20 to 39 years, 11 (27.5%) had pyogenic granuloma, in a higher proportion than expected; in the group aged 60 to 96 years, 13 (18.6%) there was intraepithelial neoplasia, and this proportion was higher than expected by the statistical test (†); of the individuals aged 20 to 39 years, 17.5% had squamous papilloma, and this proportion was higher than expected (Table 5). That is, these frequencies were significantly higher in the respective age groups.

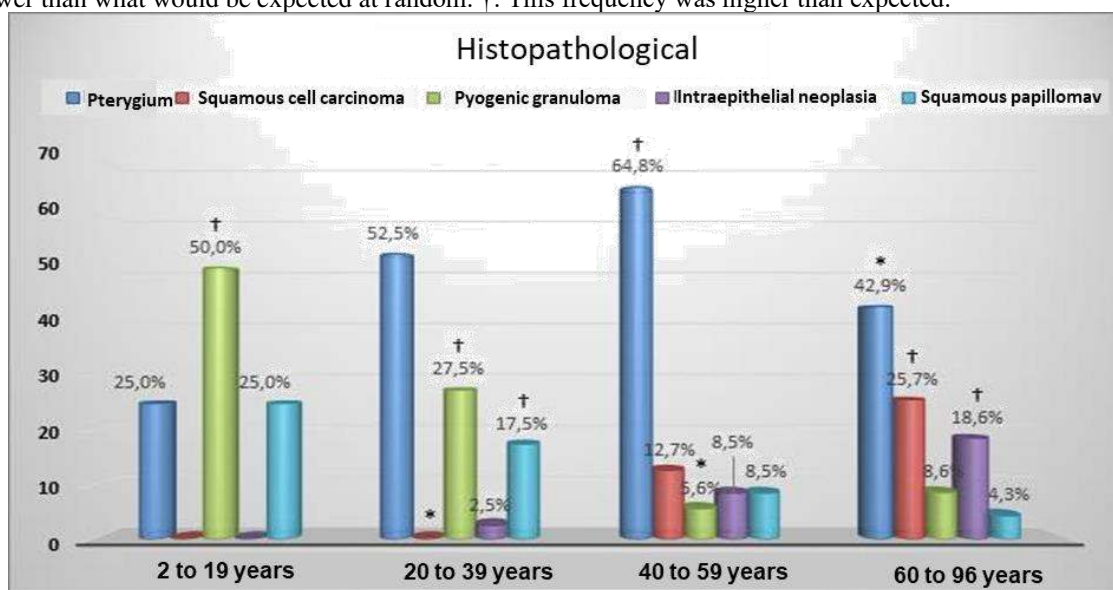
Table 5 - Association between age and the main histological types of patients undergoing surgery for excision of conjunctival tumor at the Bettina de Souza Ferro University Hospital, from 2010 to 2022, Belém-Pará.

Variable	From 2 to 19 years (n=4)	From 20 to 39 years (n=40)	From 40 to 59 years (n=71)	From 60 to 96 years (n=70)	p-value
Histopathology					$< 0,001$
Pterygium	1 (25,0)	21 (52,5)	46 (64,8)†	30 (42,9)*	
Squamous cell carcinoma	0 (0,0)	0 (0,0)*	9 (12,7)	18 (25,7)†	
Granuloma Piogênico	2 (50,0)†	11 (27,5)†	4 (5,6)*	6 (8,6)	
Intraepithelial Neoplasia	0 (0,0)	1 (2,5)	6 (8,5)	13 (18,6)†	
Scaly Papilloma	1 (25,0)	7 (17,5)†	6 (8,5)	3 (4,3)	

Categorical variables are displayed as n (%). The percentages are relative to the total of each column. The chi-square test was used. *: this frequency was lower than what would be expected at random. †: This frequency was higher than expected.

Figure 3 below shows these results from Table 5, graphically.

Figure 3 - Association between age and the main histological types. The chi-square test was used: $p < 0.001$. *: this frequency was lower than what would be expected at random. †: This frequency was higher than expected.



When analyzing the laterality and histopathological parameters, together, it was noticed that these were not significantly associated ($p=0.251$), that is, the histopathological types did not vary significantly between the two eyes.

Table 6 - Association between tumor laterality and the main histological types of patients undergoing conjunctival tumor exeresis surgery at the Bettina de Souza Ferro University Hospital, from 2010 to 2022, Belém-Pará.

Variable	Left Eye (n=85)	Right Eye (n=90)	p-value
Histopathology			0,251
Pterygium	38 (44,7)	55 (61,1)	
Squamous cell carcinoma	14 (16,5)	11 (12,2)	
Granuloma Piogênico	12 (14,1)	10 (11,1)	
Intraepithelial Neoplasia	13 (15,3)	7 (7,8)	
Scaly Papilloma	8 (9,4)	7 (7,8)	

Categorical variables are displayed as n (%). The percentages are relative to the total of each column. The chi-square test was used.

4 DISCUSSION

Regarding the results obtained in this research, in this session, we discussed in the light of the comparison, with similar findings existing and contrary in the literature, as well as the theoretical data that elucidate the phenomena found here with that of other researches. In addition to, primarily, being compared to the findings of other researchers who exclusively researched, malignant and benign conjunctival tumors; secondarily, they were also compared to the findings of studies with other types of ocular tumors, methodology, and objectives analogous to those claimed in this research. And finally, the phenomena found in this research were discussed with studies that elucidate and/or tangential them,

in order to explain the data reported in the previous session of this research, but that had not been reported in the articles of this field of study. Therefore, the most accessible, relevant published studies that contemplated the most prominent findings in the 2 categories addressed in this research were shown: characterization of the collected sample and the association between these results obtained with regard to the categories of gender, age, histological types, and laterality.

4.1 SAMPLE CHARACTERIZATION

After the analysis of the sociodemographic data of the patients of the research, it can be verified that 63.6% of them were male, the sample had a mean age of 49.6 years. But 33.6% of the research participants were in a range between 40 and 59 years of age, and the elderly corresponded to 32.4% of the sample collected (from 2 to 96 years).

These data, corroborated by the findings of Margotto (2016), in which, in his epidemiological research, he detected that 27.77% of men, compared to 9.43% of women, exhibited cancerous lesions among several eye injuries, demonstrating a clear difference between the 2 genders. At the same time, in other studies, the female gender stood out, percentageally, in relation to the male. As can be seen in the findings of Hirt, (2022), in which it was observed that the female prevalence, in his sample of 155 patients, was 56.4%; as well as by Damasceno (2018), when reporting that the distribution of his sample between the genders was 165 women (51%) against 159 men (49%); data similar to those of Bizarro (2014), that when investigating 1622 patients, showed a sample of 59.6% who belonged to the female sex and 40.4% to the male sex. A proportion corroborated by the findings of Xu et al. (2008) and Díaz (2004), who found similar proportions to these, with, respectively, 57% and 55.1% of female individuals, and 43% and 44.9% of male patients, leading their research on ocular tumors.

A phenomenon that can be explained by the greater demand of women for health services, reflecting a greater self-care and concern for health than men, which can cause data from the male gender to be underreported (BIZARRO, 2014). As well as the population proportion of gender in Brazil, which according to the Brazilian Institute of Geography and Statistics (2022), was 51.1% female and 48.9% male, corresponding to 4,800,000 more women than men in Brazil, which may be expanding the sample space in some studies. While men are exposed to risk factors more prominently than women, which can trigger possible developments of conjunctival tumor diseases. And, these, are more inclined to immune suppression caused by ultraviolet rays, and, in this regard, does not level to the female gender, especially with regard to environmental inclement weather (ALKALLAS, 2020; LIU-SMITH, 2017), as well as being less likely to wear sunglasses; avoid exposure to the sun near noon; seeking shade during outdoor work (AMERICAN CANCER SOCIETY, 2019); in addition, they are more prone to ocular tumors because they are the largest contingent of labor in agriculture and

construction, either by the sun or by exposure to chemical and physical risks (MARGOTTO, 2016; RADESPIEL-TRÖGER, 2009); and also because they are the majority transmitters, by sexual route, of HPV to females, which explains the 10,000 cases of laryngeal carcinomas; oropharynx; mouth; eyes; anus; and penises correlated with HPV infection (MEDRADO, 2017; ZARDO, 2013), and, finally, most men are concentrated in regions below 30 degrees latitude (north or south) in relation to the equator, due to the high population density of these regions (India, Africa, China and the Middle East), and which predisposes to greater exposure to ultraviolet rays, infrared radiation, and carcinogenic pollutants (HENN, 2022; GICHUHI, 2013).

Regarding the age of the research participants with ocular tumors, there was a similar pattern of research in the literature, since Hirt (2022) reported that the patients in his research had an average age of 49.5(±20.1)years; as well as Damasceno (2018) had patients who paired with the second group reported in this research (elderly), who had an average between 65 and 75 years; Matheus (2017) published that conjunctival tumors most often affected individuals between 20 and 39 years of age, while Bizarro (2014) noticed a high prevalence of tumors in middle-aged and elderly individuals, with an average of 59.4 years per their diagnosed patients.

The records of surgeries, in the interval between 2010 and 2022, report more surgical procedures being performed in the years 2015 (32), 2017 (30), 2018 (35) and 2021, the year in which the largest increase (60 records) in the number of surgeries performed was observed. These results were the result of components of the management and hiring of ultra-specialized and experienced professionals in the ophthalmic-surgical field, since, according to the hires made in 2015, Dr. Ana Cláudia Wanzeler (PhD in medical sciences with emphasis in ophthalmology and specialist in ophthalmology), was able to leverage the indicators of surgeries, which were awaiting the results of the preoperative examinations still from 2014, initiating the series of increases in surgeries undertaken in 2015, which eased the waiting lines in 2016. That later rose again in the years 2017 and 2018, after the completion of preoperative examinations of 2016. And after the finalization of his contract, this phenomenon was also observed after the hiring of Dr. Frederico Lobato (specialist in ophthalmology), who received the accumulated queue of 2020, the year in which there was the beginning of the pandemic. Therefore, in 2021, all of the postponed surgeries of 2020 were performed. These factors contributed to achieving a record year of surgical care as never seen in the last 12 years.

While the highest measured prevalence of laterality was right-handed in 47% of the diagnoses of the tumors found (similar to the sinister laterality of 45.5%). And the malignancy of these conjunctival tumors, in the medical records analyzed, was mostly benign (76.3%).

As for the side of the eye most affected by tumors, it was a question that demonstrated divergences, not very significant, among the studies found in the literature, since Hirt (2022) reported

that the right eye was the one that presented the most tumors (169 cases) while 162 cases were in the left eye; while Bizarro (2014) reported that the right and left eyes, respectively, they were affected by benign and malignant tumors, also proportionally, with percentiles of 44% and 45%. And finally, Kumar, (2013) and Saari (2001) did not observe statistical divergences between the groups of ocular tumors (right-handed and sinister) found in these studies.

The severity of eye tumors, reported in the literature, were of higher benign prevalence, according to Hirt research (2022); De Almeida & Ferreira (2019); Bizarre (2014); Deprez & Uffer (2009); Xu et al. (2008); Paul (2008); Obata (2005) and Díaz (2004). With the exception of the findings of Fotouhi et al. (2009) who reported a lower prevalence of benign tumors, such as pterygium and pinguecula, in 44% of cases. Which according to Eslami (2018) can be explained by divergences of genetic factors, socioeconomic issues and environmental nuances in the populations analyzed. In addition, according to the American Academy of Ophthalmology (2011), most of the suspicious findings are removed by surgeries performed due to cosmetic purposes, which can lead to a possible underreporting of malignant tumors.

At the same time, the highest prevalences of conjunctival tumors, confirmed by histopathological examinations, in the sample were between pterygium (39.1%); squamous cell carcinoma (11.1%); pyogenic granuloma (9.5%); intraepithelial neoplasia (7.9 %); and squamous papilloma (7.1%). In this sample, Squamous Cell Carcinoma (11.1%) and Melanoma (1.2%) were detected as the only malignant tumors present in the sample.

These histopathological findings demonstrate, in some points, divergences with other epidemiological studies of benign tumors, found in the literature, since Hirt (2022) found more benign tumors of the squamous cell papilloma type with 26% of incidence, and 27.3% of pyogenic granuloma in his sample. While Eslami (2018), ratifying the findings of this research, reported a higher frequency of pterygium diagnoses in 52.5% of cases, and papilloma with 2.1% of the sample. In contrast Damasceno (2018), even with a sample reporting a majority of 70.9% of benign tumors, pointed to actinic keratosis as responsible for 36.5% of cases. For Bizarro (2014) the most prevalent benign tumors, in his research, were the squamous papilloma, with 1/3 of the representativeness of the sample, followed by the presence of melanocytic nevus and granuloma. In addition to Deprez & Uffer (2009) who found in descending order, in their research, the squamous papilloma; the melanocytic nevus and the epidermoid cyst, as the most prevalent benign tumors. Data similar to those published in China by Xu et al. (2008) in another study, in which the most evident benign tumors were the melanocytic nevus, the squamous papilloma, the epidermoid cyst and the dermoid. Just like Díaz (2004), in a research conducted in Spain, he found the melanocytic nevus and the epidermoid cyst, among the most prominent benign tumors.

Contrary to what has been reported, in a heterogeneous way, about benign tumors, malignant tumors, here in this study, were quite similar with the literature researched. Since Hirt (2022), Yousef & Finger (2012) and Toshida (2012) reported squamous cell carcinoma as one of their most prevalent tumors in their studies. Following the same path Miyano (2021), in his research with conjunctival tumors, found a higher prevalence of conjunctival carcinomas (64.5%), while conjunctival melanomas reached 32.2% of his sample. B in how Damasceno (2018) pointed, in an analogous way, Carcinomas and Melanomas as the most prevalent malignant tumors in his research. Similarly, Eslami (2018), Bizarro (2014) and Aghogho, Ernest, Temitope (2009) reported squamous cell carcinomas and melanoma as the malignant tumors present among the most prevalent in their sample. Similarly, Coroi (2010); Deprez & Uffer (2009); Diaz (2004); Margo (1999); Proença (1998) and Cook (1990) reported, in agreement, that, in their research, among the most frequently found malignant tumors, carcinomas and melanomas were among those present. And finally, among the analyzed researches Tonietto (2003), Kato (1996); Schelini (1992); Burnier Júnior (1988) and Schelini (1987) published that squamous cell carcinomas are one of the most common malignant conjunctival tumors found in their research, covering from 20% to 61.53% of the tumors in their samples.

According to Bizarro (2014) divergences in epidemiological findings around the world on tumors are common, as well as this theory is shared by Kumar (2013); Mak (2011); Xu et al. (2008); Takamura (2005); Wang (2003); Lee (1999); Sihota (1996), who are authors of an Asian series of studies. For Yousef & Finger (2012) the incidences of these can change between countries, but in countries close to the equator have higher incidences and occur earlier. And yet, Deprez & Uffer (2009) contributes by elucidating that the frequency of different types of tumors is more vehemently due to factors such as geographical position; population genetics; socio-economic situation and access to health services.

Among the tumors removed, 20 (7.9% of the sample) had records of compromised margins, which, prior to surgery, were affected by squamous cell carcinomas (80%); melanomas (10%); and intraepithelial neoplasms (5%). And 9 patients (3.55% of the sample) had free margins, from which benign tumors (melanocytic nevus, pseudoepitheliomatous hyperplasia, and conjunctival compound nevus) were previously removed in more than half of the cases (55.5%), and 33.3% of the cases by malignant tumors (squamous cell carcinoma and melanoma).

These findings may have their importance ratified in the literature by the experiments of Yacoub (2012) and Midena (2000), in which they found that 92.3% of conjunctiva and corneal tumors had a high risk of recurrence after being removed, especially when they previously exhibited margins compromised by squamous cell carcinoma, which was shown to be responsible for at least 22.2% of the cases of tumor recurrence, while tumors with perilocal invasion (scleral and intraocular) were

associated with a higher prevalence (50%) of recurrence, as well as for Pizzarello (1978) who detected that subtypes with greater severity of squamous carcinoma in the conjunctiva show higher recurrence rates. For example, the increase of up to 41% in squamous cell carcinomas and 24% in conjunctival intraepithelial neoplasms after surgical treatment. Since tissues with dysplastic characteristics can recur in 69% of cases (YACOUB, 2012). But they can have their recurrence rates reduced, between 7% and 22%, by concomitant treatments such as cryotherapy (FINGER, 2005; Peksayar, 1989).

For Kathryn (2011), Shields (2004) and Erie, (1986) recidivism rates after surgical removal of intraepithelial neoplasms of the conjunctiva can occur in up to the second year after surgery, and diverge between 15% and 52%. But that can be reduced to 5% if the removal of the tumor is complete (TUNC, 1999). Therefore, for Kathryn (2011), surgical removal associated with cryotherapy and other topical therapies (5-FU, Interferons and MMC), are encouraged by their promising prognoses. In parallel, for Williams & Nicola (2021) one should have a distance of 2 mm, as a margin, when surgically removing these tumors, in addition to at least 2 sessions of cryotherapy, to vitrify the tumor, through successive freezes and thawings of these margins, and, it is still suggested epitheliectomy, using alcohol, in the circumscribed pathology, because for Shields (2004) these procedures promote a histopathological advantage in these tumors.

4.2 ASSOCIATION BETWEEN HISTOLOGICAL TYPES, GENDER, AGE AND LATERALITY

When the main types of tumors were associated with the genders of the patients, it was noted that the benign tumor with the highest prevalence was pterygium, with 61.5% and 47.6%, respectively, in females and males, and Squamous Cell Carcinoma, as the most incident malignant tumor, in females (13.8%) and males (15.3%).

The findings of this research session diverge with the results of Hirt (2022) who demonstrated that women, 54.8% of the sample, had malignant tumors. Going against the findings of Damasceno (2018), which revealed that 29.1% of his patients with tumors were malignant. And, there was a higher incidence (83.3%) of malignant melanomas in males. While for Kathryn (2011) the highest incidence of squamous cell carcinomas and intraepithelial neoplasms of the conjunctiva, were present in elderly Caucasian males.

For Bizarro (2014) the difference between the prevalence of benign and malignant tumors was insignificant and did not show to be related to the gender of the patient. Contrasting Xu et al. (2008), who reported that benign tumors were more present in women, while premalignant and malignant tumors were no longer predominant in a given gender. For Díaz (2004) there was a higher prevalence of benign tumors in females, and malignant tumors in men. And, in another research, Coroi (2010), reported that malignant tumors, such as carcinomas, were more numerous in males. Such findings are

plausible, considering that for Kathryn (2011) and Tonietto (2003) the excess of smoking; increased exposure to chemicals and environmental agents (such as a dry climate or excess of suspended particles); lesions and contaminations on the ocular surface; and HPV infection, are factors that are more prevalent in males and lead to more mutations in the genome of eye tissues.

In view of the crossing of parameters such as age group and types of conjunctival tumors, it can be understood that younger patients, between 2 and 19 years old, had a higher incidence of a benign tumor (pyogenic granuloma) in 50% of the cases; Following this pattern of benign tumor, individuals aged 20 to 39 years had a prevalence of pyogenic granuloma in 27.5% and squamous papilloma in 17.5%. Both groups did not demonstrate, in this study, the presence of any malignant tumors. In the age group between 40 and 59 years, 64.8% exhibited pterygium more vehemently. And in individuals between 60 and 96 years old, 25.7% demonstrated squamous cell carcinomas, twice as many as in the group 20 years younger. In parallel, intraepithelial neoplasia corresponded to 18.6% in the latter more advanced age group.

The results of this research, which paired conjunctival tumors with age groups, were homogeneous with those reported in the literature. Since Damasceno (2018) reported more malignant tumors in patients aged 67 years and older. While for Kathryn (2011) squamous cell carcinomas and intraepithelial neoplasms of the conjunctiva were more frequent in individuals from 56 years of age. For Tonietto (2003) and Schellini (1991) the appearance of conjunctival squamous cell carcinoma eventually occurs in people over 50 years of age, however it is possible to also appear in young groups, even if it is not common, especially if they are Caucasian, and live in regions of the equatorial range of the planet, or carry HIV.

Bizarro (2014) observed that most cases of eye tumors are recorded in the middle age range, followed by the elderly, and low among the youngest. It also demonstrated that benign tumors had higher prevalence of onset in younger groups, and that the mean age of patients diagnosed with malignant tumors was higher. However, benign tumors are common in all age groups, but malignant tumors have an incidence that increases with each year of life, and is therefore higher in people over 65 years.

In an attempt to pair the tumor laterality with the types of tumors surgically removed, it was verified that their presentations did not vary significantly ($p=0.251$) between the right-handed ($n=90$) and/or sinister ($n=85$) positions in the patients' eyes.

Although the laterality of the tumor was not significant in the sample, it was slightly higher on the right-handed side (5.5%). This finding was also irrelevant for Bizarro (2014), in which there was a prevalence of 45% in the right eye and 44% in the left, being considered involved in an equivalent way both for lesions caused by benign tumors, as in lesions originating from malignant tumors. Saari

(2001) and Kumar (2013) also did not report any difference in predominance in the correlation of laterality with tumor severity.

5 CONCLUSION

This study ended by reporting that 63.6% of the patients in this study with conjunctival tumors were male, of these 33.6% were aged between 40 and 59 years and 32.4% were elderly. Most patients (76.3%) had benign tumors, among which 39.1% were of the pterygium type. The malignant tumor with the highest incidence was squamous cell carcinoma (11.1%) followed by melanoma (1.2%). Of those with compromised margins after surgical removal, 80% had squamous cell carcinoma as histopathological type, and among those with free margins, 33.3% had melanocytic nevus.

Almost half of the men (47.6%) were diagnosed with pterygium, and only 15.3% of the men were diagnosed with squamous cell carcinoma. Patients aged 2 to 39 years had more diagnoses of pyogenic granuloma. Middle age (40 to 59 years) represented 64.8% cases of pterygium, while squamous cell carcinoma was more present in the range between 60 and 96 years (25.7%), as well as intraepithelial neoplasia (18.6%). The severity of the tumors was distributed similarly between the two eyes.

And although the profile of this group has been traced in Belém do Pará. In future studies, variables such as risk behaviors, comorbidities, occupational activities, family history and level of education can always be paired. Which, also, are observed in the most varied researches reported around the world, but neglected in this research by the lack of these data in the digital porters. Therefore, it is suggested to implement them so that future profiles are drawn and the relationships of these factors in the Eastern Amazon region are better understood.

REFERENCES

- AGHOGHO AB, ERNEST OA, TEMITOPE IE. Histopathology of ocular tumor specimens in benin city, Nigeria. *J Ophthalmic Vis Res.* 2009; 4 (4): 232-7;
- ALKALLAS, R., LAJOIE, M., MOLDOVEANU, D. Multi-omic analysis reveals significantly mutated genes and DDX3X as a sex-specific tumor suppressor in cutaneous melanoma. *Nat Cancer.* 2020; 1:635-652.
- AMERICAN ACADEMY OF OPHTHALMOLOGY. *Ophthalmic Pathology and Intraocular Tumors. Basic and Clinical Science Course. Section 4.* 2010-2011,13:199.
- AMERICAN CANCER SOCIETY. *Cancer Facts and Figures 2019.* <https://www.cancer.org/content/dam/cancer-org/research/cancer-facts-and-statistics/annual-cancer-facts-and-figures/2019/cancer-facts-and-figures-2019.pdf> Accessed June 13, 2020.
- BIZARRO, M.B. Estudo da frequência e correlação clinicopatológica de tumores de localização palpebral. Artigo de conclusão de curso de medicina. Universidade de Coimbra, Portugal. 2014.
- BURNIER JÚNIOR MNN, BERFORT JÚNIOR R, RIGUEIRO MP, MONTEZZO LC, CHIFERI JÚNIOR V. Neoplasias malignas da conjuntiva. *Arq Inst Penido Burnier.* 1988; 30(2): 80-3.
- COOK BE, BARTLEY GB. Epidemiologic Characteristics and Clinical Course of Patients with Malignant Eyelid Tumors in an Incidence Cohort in Olmsted County , Minnesota. 1990:746– 750.
- COROI MC, ROSCA E, MUTIU G, COROI T, BONTA M. Eyelid tumors: histopathological and clinical study performed in County Hospital of Oradea between 2000-2007. *Rom. J. Morphol. Embryol.* 2010;51(1):111–5. Available at: <http://www.ncbi.nlm.nih.gov/pubmed/20191129>.
- DE ALMEIDA, R.F.;FERREIRA, I.S. Tumores oculares. Artigo Informativo da Clínica Oftalmológica DUO. 2019.
- DEPREZ M, UFFER S. Clinicopathological features of eyelid skin tumors. A retrospective study of 5504 cases and review of literature. *Am. J. Dermatopathol.* 2009;31(3):256–62. Available at: <http://www.ncbi.nlm.nih.gov/pubmed/19384066>.
- DÍAZ M DEL C. Tumores Palpebrales: Correlación Clínico-Patológica de 1334 Casos. Tese de Doutorado. Universidade Complutense. Madrid. 2004.
- ERIE JC, CAMPBELL RJ, LEISGANG J. Conjunctival and corneal intraepithelial and invasive neoplasia. *Ophthalmology* 1986;93:176-83
- FINGER PT. “Finger-tip” cryotherapy probes: treatment of squamous and melanocytic conjunctival neoplasia. *Br J Ophthalmol* 2005;89:942–5.
- FOTOUHI A, HASHEMI H, KHABAZKHOOB M, MOHAMMAD K. PREVALENCE and risk factors of pterygium and pinguecula: the Tehran Eye Study. *Eye (Lond).* 2009;23:1125.
- GICHUHI S, SAGOO MS, WEISS HA, BURTON MJ. Epidemiology of ocular surface squamous neoplasia in Africa. *Trop Med Int Health.* 2013;18(12):1424-43

HENN ML, GRUMANN JÚNIOR A, DUARTE DA SILVA TM. Análise do perfil clínico de pacientes portadores de neoplasia ocular escamosa atendidos em hospital referência de oculoplástica. *Rev Bras Oftalmol.* 2022;81:e0055.

HÖFLING, L.A.L; DANTAS, M.C.N.; ALVES, M.R. Doenças externas oculares e córnea. Conselho Brasileiro de Oftalmologia. 4a ed. Cultura Medica, 2016.

IBGE. Censo Demográfico. Instituto Brasileiro de Geografia e Estatística. 2022. Disponível em: <<https://www.ibge.gov.br/estatisticas/sociais/populacao/22827-censo-demografico-2022.html?=&t=resultados>>. Consultado em: 20 de dez. 2022.

KANSKI. *Clinical Ophthalmology*. 9a Ed. Elsevier. 2019.

KATO ET, MACRUZ E, MORAIS L, SABROSA NA, HOLZCHUH N, ALVES MR. Tumores conjuntivais: ocorrência na clínica oftalmológica da Faculdade de Ciências Médicas da Unicamp. *Arq Bras Oftalmol.* 1996; 55 (12): 921-5.

MEDRADO, KS; SANTOS, MO; MORAES FILHO AV. Papiloma Vírus Humano (HPV): Revisão Bibliográfica. V.3,n 2:Agosto-dezembro, 2017, ISSN:24479330.

KUMAR R. Clinicopathologic study of malignant eyelid tumours. *Clin. Exp. Optom.* 2010;93(4):224–7. Available at: <http://www.ncbi.nlm.nih.gov/pubmed/20465547>. Accessed October 16, 2013.

LEE SB, SAW SM, AU EONG KG, CHAN TK, LEE HP. Incidence of eyelid cancers in Singapore from 1968 to 1995. *Br. J. Ophthalmol.* 1999;83(5):595–7. Available at: <http://www.pubmedcentral.nih.gov/articlerender.fcgi?artid=1723038&tool=pmcentrez&rendertype=abstract>.

LIU-SMITH F, FARHAT AM, ARCE A. Sex differences in the association of cutaneous melanoma incidence rates and geographic ultraviolet light exposure. *J Am Acad Dermatol.* 2017;76(3):499-505.e493.

MAK ST, WONG AC-M, IO IY-F, TSE RK-K. Malignant eyelid tumors in Hong Kong 1997-2009. *Jpn. J. Ophthalmol.* 2011;55(6):681–5. Available at: <http://www.ncbi.nlm.nih.gov/pubmed/21842179>. Accessed October 16, 2013.

MARGO CE. Eyelid tumors: accuracy of clinical diagnosis. *Am. J. Ophthalmol.* 1999;128(5):635–636.

MIDENA E, ANGELI CD, VALENTI M. Treatment of conjunctival squamous cell carcinoma with topical 5-fluorouracil. *Br J Ophthalmol* 2000;84:268–72.

MIYANO, F.S.K. Neoplasias oculares primárias malignas confirmadas por histopatologia em duas décadas no município de Passo Fundo no Rio Grande do Sul. Monografia. <https://rd.uffs.edu.br/handle/prefix/4469>. 2021.

NANJI, A.A.; MERCADO, C.; GALOR, A.; DUBOVY, S.; KARP, C.L. Updates in Ocular Surface Tumor Diagnostics. *Int Ophthalmol Clin.* Summer;57(3):47- DOI: 10.1097/IIO.000000000000174. PMID: 28590280; PMCID: PMC5484070. 2017.

- OBATA H, AOKI Y, KUBOTA S, KANAI N, TSURU T. Incidence of benign and malignant lesions of eyelid and conjunctival tumors. *Nihon Ganka Gakkai Zasshi*. 2005;109(9):573-9.
- PAUL RIORDAN-EVA, JOHN P. WHITCHER. Vaughan & Asbury's general ophthalmology. 16th ed. 2008;4:102-25.
- PEKSAYAR G, SOYTURK MK, DEMIRYONT M. Long-term results of cryotherapy on malignant epithelial tumors of the conjunctiva. *Am J Ophthalmol* 1989;107:337-40.
- PIZZARELLO LD, JAKOBIEC FA. Bowen's disease of the conjunctiva: a misnomer. In: Jakobiec FA, ed. *Ocular and Adnexal Tumors*. Birmingham, AL: Aesculapius; 1978:553-71
- PROENÇA R, VERÍSIMO J. Tumores do Globo Ocular e Anexos. 25 anos de Registo do Centro de Patologia Ocular. *Exp Ophthalmol*. 1998; 24 (1), 27-42.
- RADESPIEL-TRÖGER M, MEYER M, PFAHLBERG A, LAUSEN B, UTER W, GEFELLER O. Outdoor work and skin cancer incidence: a registry- based study in Bavaria. *Int Arch Occup Environ Health* [Internet]. Springer-Verlag; 2009;82(3):357-63. Available from: <http://dx.doi.org/10.1007/s00420-008-0342-0>.
- SAARI MK, PAAVILAINEN V, TUOMINEN J, COLLAN Y. Epidemiology of basal cell carcinoma of the eyelid in South-Western Finland. *Graefe's Arch. Clin. Exp. Ophthalmol*. 2001;239(3):230-233. Available at: <http://link.springer.com/10.1007/s004170100260>. Accessed October 16, 2013.
- SCHELINI SA. Carcinoma epidermóide de conjuntiva com metástase - Relato de um caso. *Arq Bras Oftalmol*. 1992; 55 (5):212-4.
- SCHELINI SA. Tumores da conjuntiva - ocorrência na Faculdade de Medicina de Botucatu - UNESP (São Paulo). 24º. Congresso Brasileiro de Oftalmologia. Curitiba, 1987. Anais . Curitiba, 1987. p.75.
- SCHELLINI SA, KAWAKAMI LT, SILVA MRBM, MARQUES MEA. Carcinoma epidermóide conjuntival em pacientes jovens. *Arq Bras Oftalmol*. 1991; 54(3): 115 - 8.
- SHIELDS CL, SHIELDS JA. Tumors of the conjunctiva and cornea. *Surv Ophthalmol* 2004;49(1):3-24.
- SHIELDS, C.L.; SHIELDS, J.A. Tumores da conjuntiva e da córnea. *Revista indiana de oftalmologia* vol. 67,12: 1930- 1948. DOI:10.4103/ijo.IJO_2040_19. 2019.
- SIHOTA, R., K. TANDON, S. BETHARIA, R. ARORA ND. Malignant Eyelid Tumors in an Indian Population. 1996.
- TAKAMURA H, YAMASHITA H. Clinicopathological analysis of malignant eyelid tumor cases at Yamagata university hospital: statistical comparison of tumor incidence in Japan and in other countries. *Jpn. J. Ophthalmol*. 2005;49(5):349-54. Available at: <http://www.ncbi.nlm.nih.gov/pubmed/16187033>. Accessed October 16, 2013.
- TUNC M, CHAR DH, CRAWFORD B. Intraepithelial and invasive squamous cell carcinoma of the conjunctiva: analysis of 60 cases. *Br J Ophthalmol* 1999;83(1):98-103.

WANG J-K, LIAO S-L, JOU J-R. Malignant eyelid tumours in Taiwan. *Eye (Lond)*. 2003;17:216–220.27

XU X, LI B, SUN X, LI L, REN R, GAO F. Clinical and pathological analysis of 2639 cases of eyelid tumors. *Zhonghua. Yan Ke Za Zhi*. 2008;44(1):38–41.

ZARDO, G. P. Vacina Como Agente de Imunização Contra o HPV. Paraná, p.3801, 2013.