 <https://doi.org/10.56238/alookdevelopv1-190>

**Erick Platini Ferreira Souto**

Post-doctoral internship in Veterinary Medicine.  
Institution: Federal Rural University of Pernambuco.  
Address: Rua Dom Manuel de Medeiros, s/n - Dois Irmãos, Recife - PE, 52171-900.

**Artefio Martins de Oliveira**

Master's Degree in Animal Science, Graduate Program in Animal Science.  
Institution: Federal University of Campina Grande.  
Address: Avenida Universitária, s/n - Santa Cecília, Patos - PB, 58708-110.

**Dlean da Silva Garcia**

Master's student in Animal Science and Health, Graduate Program in Animal Science and Health.  
Institution: Federal University of Campina Grande.  
Address: Avenida Universitária, s/n - Santa Cecília, Patos - PB, 58708-110.

**Antonio Flávio Medeiros Dantas**

PhD in Veterinary Science.  
Institution: Federal University of Campina Grande.  
Address: Avenida Universitária, s/n - Santa Cecília, Patos - PB, 58708-110.

**ABSTRACT**

The epidemiological, clinical and anatomopathological aspects of an outbreak of endoparasitosis in free-range chickens caused by *Raillietina* spp. are described. In a subsistence farm, 10 free-range chickens from a commercial farm were purchased. All birds began to manifest inappetence, hypodipsia, cachexia, reluctance to move, progressive lethargy, ventral decubitus and death. Three birds were sent for necropsy and presented cachectic body status, muscular atrophy and pale mucous membranes. In the small intestine there were numerous white cestoid helminths, segmented, with semiparallel walls, compatible with *Raillietina* spp. In histopathology, necrosis of the epithelial cells of the mucous tunic, lymphoplasmocytic inflammatory infiltrate permeating the mucosa and ectasia of the crypts were observed. Periodic assistance from a veterinarian is recommended, with the institution of a targeted or broad-spectrum deworming protocol.

**Keywords:** Bird disease, Intestinal helminths, Cachexia.

**1 INTRODUCTION**

According to the Brazilian Poultry Union, Brazil holds the title of the second largest producer of chicken meat in the world. As a result, several models of poultry production have been instituted, from subsistence farms to technified models. (Rodrigues et al., 2014). In subsistence farms, birds are usually raised outdoors and travel great distances in search of food, most of which are insects and seeds, which favors infections of the gastrointestinal tract by endoparasites (Rodrigues et al., 2014).

The main endoparasites of the gastrointestinal tract of commercial birds are: in the phylum of nematodes, *Ascaridia galii*, *Capillaria* spp. and *Heterakis* spp. (Silva et al., 2016; Costa et al., 1986; Gomes et al., 2009); in the trematode class, *Ostharmostomum commutatum* and *Zygoctyle lunata* (Silva et al., 2016; Costa et al., 1986); and in the class of cestodes, *Raillietina* spp., *Amoebotaenia cuneata*, *Choanotaenia infundibulum* and *Hymenolepis* spp. (Silva et al., 2016), with *Raillietina* spp. being the most prevalent cestode in birds (Adang et al., 2014).

Infections by these gastrointestinal endoparasites interfere with host metabolism, resulting in poor food utilization, reduced growth rate, and death in marked infections (Dawet et al. 2012). The objective of this work is to describe an outbreak of fatal endoparasitosis in free-range chickens caused by *Raillietina* spp.

## 2 MATERIAL AND METHODS

An outbreak of endoparasitosis in free-range chickens was reviewed at the Animal Pathology Laboratory (LPA) of the University Veterinary Hospital (HVU) of the Federal University of Campina Grande (UFCG). Epidemiological and clinical data were obtained from the owner and the veterinarian who accompanied the birds. The anatomopathological findings were obtained from the autopsy and histopathological exams, and the rescue of the photographic records.

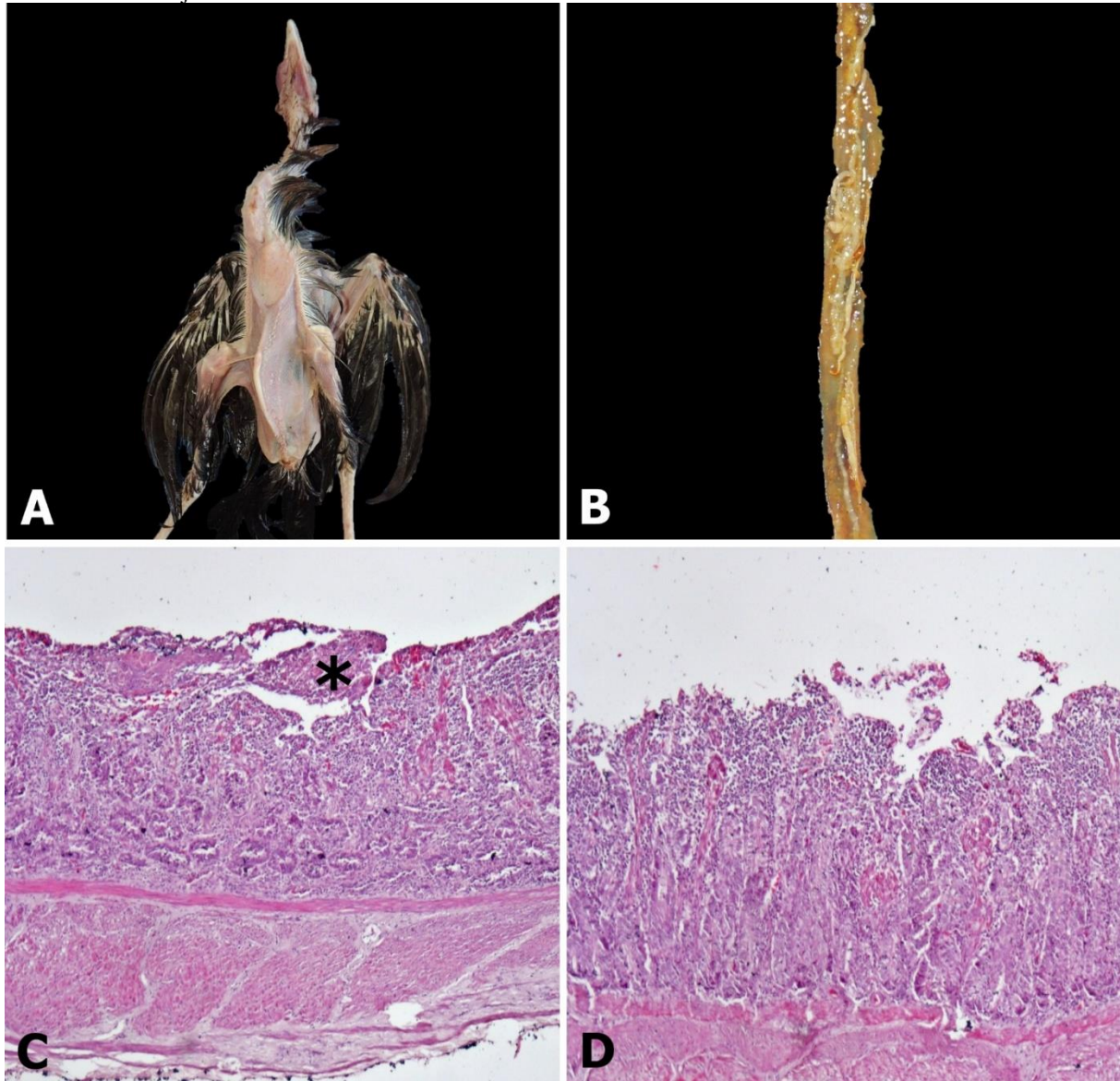
## 3 FINDINGS

In a subsistence farm located in the municipality of Patos, Paraíba, 10 free-range chickens (*Gallus gallus domesticus*) were purchased from a commercial farm. After three months in the new environment, when they were already five months old, the birds presented inappetence, hypodipsia, weight loss, reluctance to move and progressive lethargy, being persistently in decubitus. Of the 10 birds acquired, seven died and the remaining three became seriously ill and were referred for clinical examination at the UFCG HVU. In the clinical evaluation, they were extremely thin, with reluctance to move and decubitus. The animals died two days after entering the HVU and were necropsied.

In the external evaluation of the cadavers, animals were found in a cachectic body state, with pale mucous membranes and ectoparasites (*Dermanyssus gallinae*) distributed among the feathers. At necropsy, diffuse muscle atrophy was observed, particularly appreciable in the pectoral musculature (Fig. 1A). At the opening of the small intestine, there were numerous cestode helminths, characterized by being white, segmented, with semiparallel walls and measuring from 3 cm to 10 cm in length, morphologically compatible with *Raillietina* spp (Fig. 1B).

In the histopathological evaluation of the small intestine, necrosis of the mucosal epithelial cells was observed, particularly in the region of the apical surface of the villi (Fig. 1C) and sometimes associated with moderate villous atrophy; accentuated inflammatory infiltrate consisting of lymphocytes, plasma cells and rare macrophages permeating the mucosa (Fig 1.D); and discrete ectasia of the crypts, with occasional epithelial cells presenting pycnosis and intraluminal detachment.

Figure 1 - A) Animal in cachectic body state with diffuse muscular atrophy. B) Small intestine, jejunum. Numerous specimens of *Raillietina* spp. C) Photomicrograph of the small intestine are observed. Area of necrosis of the intestinal villi (asterisk). HE. Obj. 5x. D) Photomicrograph of the small intestine. Mononuclear inflammatory infiltrate permeating the mucous tunic. HE. Obj. 25x.



#### 4 DISCUSSION

The diagnosis of endoparasitosis by *Raillietina* spp. was established based on epidemiological, clinical and anatomopathological findings. Tapeworms belonging to the genus *Raillietina* spp. are the most frequent cestode helminths in birds worldwide. Their intermediate hosts are ants and beetles, which are usually available in abundance in the environment (Adang et al., 2014), being particularly important in subsistence farms in which animals are kept outdoors.

*Raillietina echinobothrida* is the most important species in terms of prevalence and pathogenicity. Tapeworms reside in the small intestine and usually cause decreased growth rates in chicken, weight loss in adult birds and decreased egg production in chickens (Lalchhandama, 2010). In conditions of marked infection, parasites actively consume ingested nutrients and can lead to death

(Adang et al., 2014; Lalchhandama, 2010), which justifies the marked muscular atrophy (due to malnutrition) and weakness observed in these birds.

The anatomopathological findings are characteristic of parasitic enteritis, caused by numerous specimens of *Raillietina* spp. Infection by a large number of parasites in the intestinal lumen determined the occurrence of an emaciant disease with a fatal outcome, which occurred in the form of an outbreak, and whose morbidity and lethality rates reached 100% of the rearing.

The prevalence of parasitic infections in the digestive tract of birds in subsistence farms is around 100%, and some birds may harbor more than one type of parasite (Permin et al., 2002). It is believed that infections by a single type of parasite, such as the one observed in this study, are related to the order of onset of infection, as the first parasite to infect the host can dominate the microhabitat and establish itself in isolation (Adang et al., 2014).

## **5 CONCLUSIONS**

For effective control of endoparasite infections in birds, periodic assistance from a veterinarian is recommended, with the institution of a targeted or broad-spectrum deworming protocol. Albendazole is an easily accessible, low-cost and known effective vermifuge against cestodes of the genus *Raillietina* spp.

## **ACKNOWLEDGEMENT**

Acknowledgement To the National Council for Scientific and Technological Development (CNPq) for granting the postdoctoral fellowship to EPF Souto (Grant: 151086/2022-2).

## REFERENCES

- Adang, K. L.; Asher, R.; Abba, R. Gastro-intestinal Helminths of Domestic Chickens *Gallus gallus* domestica and Ducks *Anas platyrhynchos* Slaughtered at Gombe Main Market, Gombe State, Nigeria. *Asian Journal of Poultry Science*, vol. 8, n. 2, p. 32-40, 2014, DOI: 10.3923/ajpsaj.2014.32.40.
- Costa, H. M. A.; Leite, A. C. R.; Guimarães, M.P.; Lima, A.S. Distribuição de helmintos parasitos de animais domésticos no Brasil. *Arquivo Brasileiro de Medicina Veterinária e Zootecnia*, v. 38, n. 4, p. 465-579, 1986.
- Dawet, A. D. P.; Yakubu, Y. H.; Daburum, J. P.; Dung, U. I. H. Gastrointestinal helminths of domestic chickens (*Gallus gallus*) in Jos, Plateau State, Nigeria. *Nigerian Journal of Parasitology*. v. 33, n. 1, p. 85-89, 2012.
- Gomes, F. F.; Machado, H. H. S.; Lemos, L. S.; Almeida, L. G.; Daher, R. F. Principais parasitos intestinais diagnosticados em galinhas domésticas criadas em regime extensivo na municipalidade de Campos dos Goytacazes, RJ. *Ciência Animal Brasileira*, v. 10, n. 3, p. 818-822, 2009. DOI: 10.5216/cab.v10i3.1095.
- Lalchandama, K. In vitro Effects of Albendazole on Raillietina echinobothrida, the Cestode of Chicken, *Gallus domesticus*. *J Young Pharm*, v. 2, n. 4, p. 374–378, 2010, DOI: 10.4103/0975-1483.71630.
- Permin, A.; Esmann, C. H.; Hove, T.; Mukaratirwa, S. Ecto-, endo- and haemoparasites in free-range chickens in the Goromonzi district in Zimbabwe. *Preventive Veterinary Medicine.*, v. 54, p. 213–224, 2002. DOI: 10.1016/S0167-5877(02)00024-7.
- Rodrigues, W. O. P.; Garcia, R. G.; Nääs, I. A.; Rosa, C. O.; Caldarelli, C. E. Evolução da avicultura de corte no Brasil. *Revista enciclopédia biosfera*, v.10, n.18; p. 1666 - 1684, 2014.
- Silva, G. S.; Romera, D. M.; Fonseca, L. E. C.; Meireles, M. V. Helminthic Parasites of Chickens (*Gallus Domesticus*) in Different Regions of São Paulo State, Brazil. *Brazilian Journal of Poultry Science*, v. 8, n. 1, p. 163-168, 2016. DOI: 10.1590/18069061-2015-0122.