

Use of ozone therapy as an integrative treatment in an elderly dog with canine atopic dermatitis (CAD) and food hypersensitivity (AH): case report

 [10.56238/tfisdwv1-170](https://doi.org/10.56238/tfisdwv1-170)

Henrique Galvani de Souza

Postgraduate in Veterinary Clinical Pathology - Qualittas College - Belo Horizonte, Minas Gerais, Brazil. E-mail: hgalvani@hotmail.com

Bruna Ribeiro Gomes Costa

Veterinary Physician, Formiga, Minas Gerais, Brazil. E-mail: bbrunaribeiro@gmail.com

João Victor Ferreira Campos

Veterinarian, Santo Antônio do Monte, Minas Gerais, Brazil
E-mail: joaovfcampos@outlook.com

Talitha Oliveira de Rezende Acurcio

Veterinary Physician, Formiga, Minas Gerais, Brazil. E-mail: talitha.o.r@gmail.com

Gabriel Rodrigues Silva

Veterinary Doctor - Banana's Pet, Formiga, Minas Gerais, Brazil
E-mail: gabrielrosilva17@gmail.com

Priscila Mara Rodarte Lima e Pieroni

Professor - University Center of Formiga, Minas Gerais, Brazil
E-mail: priscilarodarte@yahoo.com.br

Leonardo Borges Acurcio

Professor - University Center of Formiga, Minas Gerais, Brazil
E-mail: leoacurcio@unifor.edu.br

ABSTRACT

Dermatopathies are among the most observed problems in the clinical routine of animals and the main etiological agents are bacteria, fungi and parasites. Atopic dermatitis develops due to the genetic character, the affected dogs become sensitive to environmental antigens, developing serious changes in the skin, with pruritic, fetid, scaly skin characteristics, and prone to secondary infections, which interferes in the animal's quality of life. Ozone therapy is a technique that uses ozone as a therapeutic agent and is being used in order to minimize the indiscriminate use of antimicrobials and to help promote the healing of skin lesions. The objective of this study is to analyze a specific case of a male animal, aged 11 years, diagnosed at 06 years of age with allergic contact dermatitis (CAD) and food hypersensitivity (AH), being observed in treatment with ozone therapy in water. It is observed with the study the effectiveness and evolution of the treatment, as well as the clinical improvement achieved, being the treatment of atopic dermatitis lifelong, due to its genetic character and exposure of the animal to the allergic factor. The benefits of introducing baths with ozonated water are the quality of life offered to the animal, since some drugs used, such as corticosteroids, can cause unwanted effects that in the long run, are able to shorten the animal's life span.

Keywords: atopic dermatopathy, dogs, ozone therapy.

1 INTRODUCTION

The dermatopathys are conceptualized as diseases that affect the tegumentary system, and may be of infectious cause, involving bacteria, parasites and fungi (Ramsey & Tennant, 2010) or immunomediated aspect. An example of non-infectious presentation is canine atopic dermatitis (AD), finding it in the clinical routine of small animals, one being the common cutaneous disease, presenting as an inflammatory condition of pruriginous aspect and difficult to control, because it is of genetic predisposition of hypersensitivity against food and/or environmental allergens by the formation of IgE antibodies (Thorsteinsdottir et al., 2016).

For diagnostic detailing, physical examination and anamnesis are performed with analysis of the patient's history, which is crucial for the differential diagnosis (Mencalha, 2019). And in some cases, however, work tests are necessary for the confirmation of clinical suspicion (Madureira & Brum, 2017).

After diagnosis of the disease, treatment is usually done with systemic and topical therapies, and may include the administration of antibiotics, in infectious cases or with secondary opportunistic infection. This is the addition of decontamination treatment. However, halopathic treatment may be ineffective, considering the multifactorial aspect of cutaneous dermatoses. Thus, the search for alternative therapies, especially in the dermatological area, has gained prominence. Thus, ozone, an integrative treatment widely used in Veterinary Medicine, has its use highlighted for skin lesions, due to its low cost, ease of application, absence of side effects and high rate of satisfactory results in clinical protocols (Freitas, 2011; Smith et al., 2017). Furthermore, ozone has viricidal, bactericidal and fungicidal properties, by oxidation of the cell membrane and other cytoplasmic component, which have a microbicidal effect (Vilarindo et al., 2013).

The objective of this study is to report the case of a Maltese dog, male, 11 years old, diagnosed at six years of age with canine atopic dermatitis (DAC) and dietary hypersensitivity (AH), and treatment with ozone therapy in water was used, associated with the use of hypoallergenic shampoo.

2 CASE REPORT

The patient is a Maltese male, who had a body weight of 4,400 kg. In the anamnesis, the guardian reported that she acquired the dog at 45 days of life, she did not know the family history of the animal. Feeding was made of dry feed for adult Maltese dogs (Table 2. Ration A. 140g a day). The animal was neutered in 2016, vaccinated and wormed according to its medical records. Ectoparasite control was maintained with Fluralaner 25 mg/kg (Bravecto®) for dogs up to 4.5kg.

Allergic dermatitis to flea bites (DAPP) or ticks was not considered, because the animal performed regular control of ectoparasites, but there was the possibility of allergic contact dermatitis. The tutor exchanged household cleaning products for the floor, even for the hygiene of clothes and blankets. However, the dog persisted with itching disease.

In the clinical examination in 2017, the animal had a body weight of 3,600 kg, was with purulent lesions on the skin, areas of alopecia, erythema and foul odor. The owner reported that the animal had the lesions on a recurrent basis and that during the period of two consecutive years (2015 - 2017) had led to another professional. Due to the successes in the treatment, the owner chose to seek a new professional.

Asked about the animal's therapeutic history, she did not know how to inform, she only mentioned that the animal used a corticosteroid for a long period, not to mention the frequency and doses. In relation to the feeding of the dog and its habits, the animal fed on feed for adult dogs with a sensitive formula claim (directed to allergic animals), with the addition of omega 6 fatty acid complex and vitamin E (Table 2. Ration B. 120g a day). As a petisco, the tutor offered her carrot, potato and apricot.

After evaluation, we opted for the total exclusion of snacks and was prescribed in place of the ration with a claim of sensitive formula, a diet with hypoallergenic appeal, formulated to reduce food sensitivities with a formulation containing hydrolyzed proteins (Table 2. Ration C. 140g a day). It was recommended to change shampoo to hypoallergenic, with miconazole nitrate (2.53g/100ml) and chlorhexidine glyconate (2.0g/100ml), with indication of two baths per week, in the period of five consecutive weeks, without evidence of improvement. We then chose to start oral antibiotic cephalexin (Lexin®) 300mg (30mg/kg), every twelve hours, for twenty-one days, with significant improvement of the animal. At the end of treatment, pruritus, as well as the areas of alopecia, itching and foul odor returned and intensified. It was decided to keep the treatment at the peaks of clinical signs of ató pica dermatitis.

At the clinical examination, during 2018, the animal had a body weight of 4,200kg, and had lesions on all skin. The tutor complained that the animal was barely scratching too much, besides presenting urine air with intense coloring. In the anamnesis, the temperature of the animal was 38°C (normothermic), cardiac frequency of 100 bpm (normocardial), respiratory rate of 40 rpm (normopnea), was hydrated, mucosal with a rosy color (normal), skin turgor less than two seconds (normal), TPC less than one second (normal). Ultrasound was requested to evaluate the complaint related to urine staining. The ultrasound examination was performed in the abdominal region, and showed no apparent alteration. A therapeutic protocol was maintained, and prednisolon steroidal anti-inflammatory drugs were added to 5mg (Prediderm®) 5mg (2.2mg/kg) for three days every twelve hours.

At the end of 2018, the animal had clinical signs of a dermatitis in remission. During the use of medications, the animal showed an important improvement in the clinical picture, did not present a foul odor, lesions, alopecia, hyperpigmentation and skin flaking. The use of hypoallergenic shampoo with miconazole nitrate (2.53g/100ml) and chlorhexidine glyconate (2.0g/100ml), was redone.

In the anamnesis, in 2019 the animal had a body weight of 4,200 kg, with areas of skin alterations, alopecia, intense itching, diffuse lesions, flaking. Fhi submitted to *SPOT PLATINUM* test (CEPAV laboratories, Água Branca, SP, Brazil), para diagnosis of allergy, which makes the combination of the two main labor methods to measure the levels of ige specific immunoglobulins (which present increased in cases of allergic reactions). For the test to be more sensitive and highly specific, all serum samples undergo IgG removal from the serum to be tested, as exposure to the allergen causes the organism to produce IgE and IgG antibodies (IgG, produced in large quantities, can interfere with the results). This ige removal is done by adding the *Staphylococcus* type A protein to the samples to be tested.

The presence of increased levels of IgE antibodies in serum is justified by the presence of parasites in animals, being of infectious origin, which interferes with the results, due to the non-specific IgE competition with the specific IgE (Medeiros et al., 2006). The usual solution is the removal of antigen samples from Helminths.

The *PLATINUM SPOT test* is divided into 5 groups, starting with grasses, shrubs/herbs, trees, mites, fungi and molds, homemade inalants, *Staphylococcus* spp. antigen and *Malassezia* spp. In the food group,

they are the main ones consumed by domestic animals, including the composition of commercial feed. A total of 91 substâncias are individually tested, according to the prevalence of allergens commonly found in Brazil, by CEPAV laboratories.

The CEPAV laboratory receives samples from all over Brazil, being necessary to perform the animal is fasting before 12 hours, the blood should contain approximately 10 mL, where it will be necessary 3 to 5 mL of serum, properly refrigerated. The collection of this material in small animals should preferably be from the jugular vein, after 1 hour of collection it is centrifuged and the serum is packed in a sterile vial, duly identified. As the material was harvested in the state of Minas Gerais, it went to São Paulo in a styrofoam box with recyclable ice and sent by land, on September 27, 2019. The average deadline for delivery of the result is approximately 45 days, being received on November 1, 2019.

The RESULTS OF THE *SPOT PLATINUM* test indicated the positive and negative sensitizing allergens (Table 1). In the group of grasses presented a negative reaction to *Cynodon dactylon* (donkey grass), *Agrostis alba* (grass ramallete), *Bromus inermis* (barley), *Lolium perenne* (azevem), *Poa pratensis* (field grass), *Phleum pratense* (rat tail grass), *Dactylis glomerata* (orchard grass), *Secale cereale* (rye). For the same group, the patient had a positive allergic reaction to *Festuca rubra* (field grass), *Anthoxanthum odoratum* (smell hay) and *Holcus lanatus* (lanudo grass)." The positive allergens here are probably caused by cross-reaction or indirect reaction of food origin (grass allergen present in meat that gave rise to feed) (Zur et al., 2002). It reinforces the absence of national literature on the theme for comparison, which prevents a deeper discussion about such results found.

In the group directed to allergic reactions to plants (Table 1), the animal had sensitivity of 80% positive, being *Rumex acetosella* (sour), *Parietaria sp.* (snake alfalfa), *Taraxacum officinale* (dandelion), *Ambrosia elatior* (cravoana), *Amaranthus sp.* (caruru), showing negative reaction to *Salsola kali* (Russian tristan) and *Chenopodium sp.* (fake santa maria herb). For the group referring to allergenic agents of trees, the animal showed 50% positive reaction, being the environmental irritants *Morus alba* (blackberry), *Quercus alba* (oak), *Salix sp.* (whiny), *Populus alba* (white poplar). In the classification fungi and levedeiras, it demonstrated an allergic reaction to *Alternaria spp.*, which is a genus of ascomycete fungi, whose species are known as important plant pathogens. Already *Stemphylium spp.* it is a pathogen of several cultivated plants, wild or invasive. *Pullularia*, in turn, fungus and yeast found in different environments such as soil, water, air and limestone. *Helminthosporium*, finally rice pathogen. Again, the scarcity of the literature and the probability of such reactions result from cross-reactions or indirect reactions are reinforced, considering that similar studies indicate the predominant allergenic factors in dogs derived from insects and arachnids (either in the parasitic context or not) (Chantick et al., 2008).

The animal with food hypersensitivity will show a positive reaction to the test, as it has sensitizing antibodies on the skin. As in the patient in the present report, related to feed components: wheat, turkey, barley, tomato, pea, chicken and corn, as visualized in (Table 1), referring to laboratory examination of the animal.

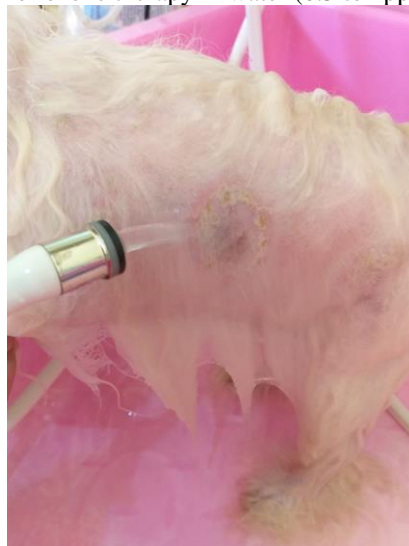Table 1 - PLATINUM SPOT test *results* (CEPAV Laboratories) for diagnosis of allergy in dogs.

Allergens	Positive Result	Negative Result
Grass	Fetusca rubra Paspalum Notatum Anthoxanthum odora Holcus lanatus	Cynodon dactylon Agrostis alba Bromus inemis Lolium PErenne Poa ratensis Phleum pratense Dactyllis glomerata Secale cereale
Shrubs/Herbs	Acetosella Rumex Parietaria sp. Taraxacum officina Elatior Ambrosia Amarhantus sp.	Kali Salsola Chenodpodium sp.
Trees	Morus Alba Quercus Salix sp. Populus alba	Ulmus sp. Platanus sp. Pinus sp. Eucalyptus sp.
Fungi/Yeasts	Helminthosporium spp. Altenaria spp. Stemphylium spp. Pullularia spp. Curvularia spp.	Aspergillus spp. Hormodendrum spp. Candida Albicans Saccharomyces spp. Rhizopus spp.
Inalantes caseiros	Pernilongo	Wool Pyrethroides Farinae D. Tyrophagus spp. Housefly Malassezia spp. Cotton Makeup D. Pteronyssinus Cockroach Fleas Kapok Jute/sisal Lepidoglyphus spp. Staph
Food	Wheat Peru Barley Tomato Pea Chicken Corn	Ox Pig Milk Algae Carrot Rabbit Veal Soy Ram Sorghum Potato Egg Rice Oats Yeast Peixe Duck

After the result of the allergic test, the tutor discussed the importance of keeping the animal away from allergenic agents was discussed with the tutor. As the animal presented flaking, diffuse lesions, hematomas and very itching, a prednisone 5mg steroidal anti-inflammatory was prescribed with action in the treatment of disorders that respond to corticosteroids (Meticorten[®]) 1mg/kg every twelve hours for three days and then, for another four days, half a tablet every twelve hours, associated with a proton pump inhibitor, omeprazole 5mg (Gaviz[®]) 1mg/kg, as well as geriatric vitamin supplement during the four-month period (Gerioox[®]) 0.5 tablet/animal weighing up to 10kg every twenty-four hours.

The tutor maintained the bath with hypoallergenic shampoo, which had in its composition lactic acid and glycerin based on wheat germ, hydrolyzed keratin and liposomes. It also used the application of therapeutic baths with ozonized water. The bathing protocol for integrative ozone treatment was initiated in July 2019. Figure 1 shows an area of alopecia, pruritus and hyperpigmentation. The process of hygiene of the animal was performed with hypoallergenic shampoo mentioned, followed by washing for twenty-five minutes. After the mechanical procedure of removal of all dirt, the dog is hydrated with neutral conditioner. Then, the animal undergoes humidification of the lesions with active ozone in water, for a period of twenty minutes, at a temperature of 10 to 15°C, with dissolution concentration 0.5 to 1 ppm. The ozonized water was obtained by means of an Ozonized Water Generator Ozoxi Pet (Ozoxi Ozone Generators, São José dos Campos, SP). Care should be taken with the eye areas in order not to cause irritability. The tutor chose to take the animal's towel for drying, avoiding possible secondary contamination by microorganisms or allergenic compounds. The procedure was performed during the period of eight weeks, twice a week.

Figure 1 - Session of ozone therapy in water (0.5 to 1ppm) for 20 minutes.



The post-observation of the remission of the clinical condition of pruritus, squamous, foul odor, alopecia, the baths were maintained, once a week, following the same protocol, with satisfactory improvement of clinical signs, with diminuição of the symptomatology of the circular, pruriginous and

desquamative lesion. Resending that the animal always when exposed to any allergenic agents, presented the clinical signs for ACA and/or AH, in the caudal dorsum region, but in a controlled manner and within the expected standards, not extending to other areas, not presenting hyperpigmentation, foul odor, with fully restored coat, without alopecia, crusts, flaking or erythema, only itching.

Doctor Veterinário observed after four months of introduction into the routine of baths with ozoned water that the patient had a significant improvement in the appearance of the hair and skin, without odor, itching, scum, hyperpigmentation and with appearance of hair in the affected areas. In remission, the baths were maintained once a week, following the therapeutic protocol described above. The main improvement was observed by the reduction in the frequency of visits to the office with complaints of clinical signs for AD.

In January 2020, the tutor reported that the patient's skin was intact, without alterations, odor or scing. The dog had no prurido, no alopecia area and subpelo present. The owner, in March, felt the need to change the animal's diet to a diet with natural antioxidants, absent from *transgênicos* and gluten, sensitive (Table 2. Ration D. 120 grams per day).

Table 2 - Nutritional composition of commercial diets for dogs according to age, breed and sensitivity or food allergen.

RATION A (Race and Age)	RATION B (Sensitive)	RATION C (Hypoallergenic)	RATION D (Sensitive)
Rice Quirera	Rice Quirera	Rice	Meat meal and lamb bones
Ground whole meal corn	Ground whole meal corn	Soy protein isolate	Rice Quirera
Poultry viscera flour	Poultry viscera flour	hydrolysate	Rice bran
Corn gluten meal	Corn Gluten Meal	Animal fats	Beet pulp
Chicken fat	Egg powder	Minerals	Poultry viscera oil
Crackling flour	Ground whole line	Hydrolyzed poultry	Beer yeast
Dried chicory pulp	Refined soybean oil	livers	Palatabilizing of pig and chicken
Refined soybean oil	Chicken fat	Soybean oil	viscera
Wheat gluten	Potassium chloride	Beet pulp	Salmon oil
Refined fish oil	Calcium carbonate	Fish oil	Sodium chloride
Brewery dry yeast	Sodium chloride	Fruit-oligosaccharides	Seaweed flour
Borage oil	Vitamins (A, C, D3, E) Thiamine (B1)	Borage oil	<i>Schizochytrium sp.</i>
Potassium chloride	Riboflavin (B2)	Tagete flower extract (lutein source).	Prébiotics (mananoligosaccharides, inulin)
Sodium chloride	Niacin (B3)	Vitamin (E, D3, C, B1, B6, B12, PP.)	Probiotic yucca extract, chondroitin sulfate, glucosamine sulfate
Monocalcium phosphate	Calcium Pantothenate (B5)	Biotin	Vitamins (A, D3, E, K3, C, B1, B2, B6, B12)
Magnesium oxide	Pyridoxine Hydrochloride (B6)	Pantothenic acid	Biotin
Glycosamine Hydrochloride	Biotin (B7)	Folic acid	Calcium pantothenate
Condroitin sulfate	Folic Acid (B9) Cobalamin (B12)	Choline Chloride	Folic acid
Sodium tripolyphosphate	Beta Carotene Choline Chloride	Inositol	Niacin
Potassium sorbate	Ferrous Sulfate	Iron	Colin chloride
Fruit-oligosaccharides	Zinc Oxide	Iodine	Iron sulfate
Marigold extract	Copper Sulfate	Copper	Copper sulfate
Green tea extract	Manganese Oxide	Manganese	Calcium iodate
Zeolite	Calcium Iolate	Zinc	Potassium chloride
Vitamins (A, C, D3, E, B1, B2, B6, B12, PP)	Sodium Selenium	Selenium	Zinc proteinate
Pantothenic acid	Palatabilizing Additives based on Pig Liver and Chicken Ofcera	Taurine	Zinc oxide
Biotin, folic acid	Antioxidants (BHA & BHT).	Tyrosine	Manganese oxide
		Clinoptilolite of sedimentary origin	

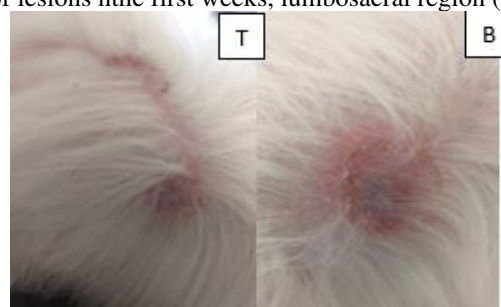
Choline Chloride Iron sulfate Copper sulfate Zinc oxide Manganese oxide Calcium iodate Yeast enriched with selenium Zinc amino acid quelate Manganese amino acid quelate Copper amino acid quelate L-lysine Taurine DLmethionine Chicken liver-based palatabilizing Antioxidant (BHA)		Antioxidants (BHA) DL-methionine	Selenium proteinate Sodium selenium Propionic acid Plant extracts (green tea, mint and rosemary) DL-Alpha-Tocopherol (natural antioxidant)
---	--	-------------------------------------	--

In August 2020, the patient had body weight of 4,100 kg, manifested atopic dermatitis and food hypersensitivity, due to exposure by food to which the patient was sensitized, or induction by conventional environmental allergen.

Topical treatment was redone with therapeutic bath of ozonized water, adding to the protocol topically: shampoo with active ingredients ketoconazole and chlorhexidine, contendo, every 100 ml, chlorhexidine digluconate at 20%, 20g and ketoconazole at 4%, being indicated as antiseborrheic, antiseptic and antique, assisting in the health of the skin and fur of dogs and cats. This active ingredient is of great use in Veterinary Medicine in controlling the proliferation of bacteria and fungi that are secondary microorganisms that affect atopic animals. The oleo de jojoba enters its formulation due to its action of calming the irritated skin, moisturizing and strengthening the growth of the hair. It was alternated with hypoallergenic shampoo, composed of lactic acid and glycerin based on wheat germ, hydrolyzed keratin and liposomes, with bathing frequency every seven days for a period of two months. Treatment with glucocorticoide-based drugs was not necessary at this time.

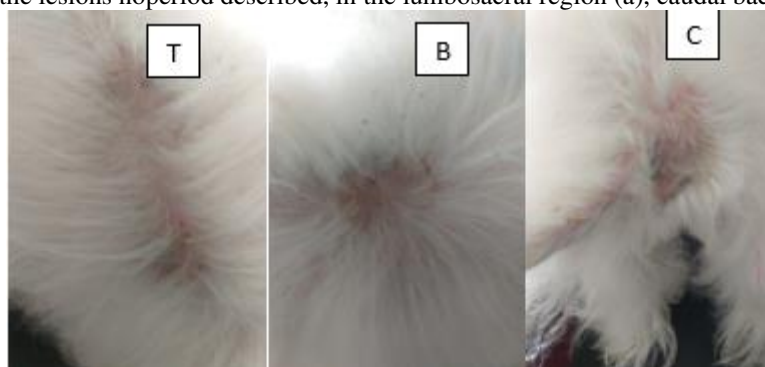
The patient during the first week (Figure 2a), second and third week, presented lesions with puriginous aspect, areas of alopecia, eritrema, skin flaking, foul odor, located in the lumbosacral region (Figure 2a) and caudal back (Figure 2b).

Figure 2 – Aspects of lesions nthe first weeks, lumbosacral region (a) and caudal back (b).



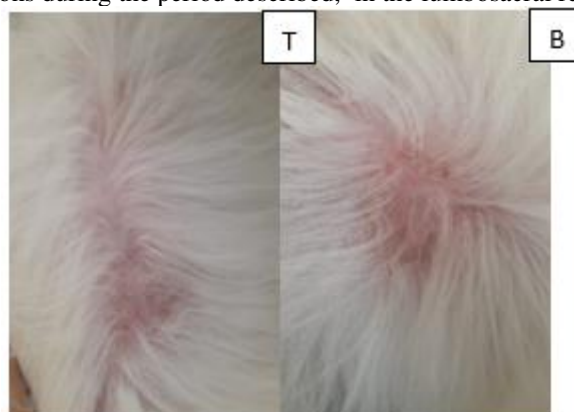During the fourth week (Figure 3a and 3b), it was possible to observe the increase in flaking after the use of the hypoallergenic shampoo based on wheat germ, where the wheat element is inside the allergenic agents of the *PLATINUM SPOT test* allergic test, but it was not possible to identify the level of sensitivity by the skin barrier that the patient presents. Houve doursinization of pruritus and absence of foul odor, however, the exposed to the food sensitizing agent and/or alis environmental allergen may have been responsible for the apaeming of new lesions in the caudal region (Figure 3c). The regeneration of this new lesion was rapid in view of topical treatment with ozonized water, and only three baths were required once a week, maintaining the same dissolution concentration (0.5 to 1 ppm) in the 21-day period.

Figure 3 - Aspect of the lesions noperiod described, in the lumbosacral region (a), caudal back (b) and tail base (c).



The improvement in the skin was notorious around the fifth application of ozone in the lumbosacral region (Figure 4a) and in the sixth application in the caudal dorsum region (Figure 4b). The lesions did not present itching, flaking and foul odor, but remained hyperpigmented.

Figure 4 - Aspect of the lesions during the period described, in the lumbosacral region (a) and caudal back (b).




After the sixth session in the lumbosacral area (Figure 5a) and s isthe last session in the dorsocaudal region (Figure 5b), there was a decrease in crusts and inicioof hair growth in alopecicas areas, hyperpigmentation only at the edge of the lesion.

Figure 5- Aspect of the lesions during the period described, in the lumbosacral region (a) and caudal back (b).



Next in the session (Figure 6a) and eighth session (Figure 6b and 6c) there was total absence of crusts, pruritus, hyperpigmentation and settling of normal hair growth.

Figure 6- Aspect of the lesions during the described period, in the lumbosacral region (a,b) and caudal back (c).



3 DISCUSSION

The skin is the main constituent of the integumentary system and functions as an anatomophysiological barrier between the animal and the environment; protects the body against chemical, physical and microbiological damage agents and participates in the excretion of substances. Through its sensory components, it can perceive pain, cold, heat, touch, pressure, itching, as well as reflect pathological processes that have their origin in other organs or systems. Skin diseases are one of the main reasons that lead animals to veterinary care and to consequent laboratory tests (Scott et al. , 2001; Macêdo et al., 2008).

In the clinic of small animals, dermatopathies have great importance, representing about 30 to 40% of clinical diseases (Willense, 2002). The main dermatopathies of dogs and cats are bacterial, parasitic and fungal (Meneses et al. , 2000; Ramsey & Tennant, 2010; Cardoso et al., 2011).

In Brazil, skin-related problems are mainly bacterial, immunological, endocrine and parasitological (Machado et al., 2004). Among the diseases, atopic dermatitis in dogs is a high degree of prominence, occupying the second place among canine diseases, second only to allergic dermatitis to flea bite (PPD), which is the most common cause (Zanon et al., 2008). Borges (2006) also reports, as usual forms of dermatopathies, scabies such as demodicosis and scabies, endocrine dermatitis, atopic dermatitis, bacterial folliculitis, skin cancer, otitis, allergic dermatitis by ectoparasite bite and lickdermatitis.

Dermatological cases are a challenge for the veterinarian, as often the diagnosis is not evident only by clinical examination. These more complex cases require, in addition to detailed anamnesis and physical examination, the elaboration of a list of differential diagnoses and the performance of complementary tests (Horta & Costa Val, 2013). The dog of the present demoreport highlighted several triggering factors for sensitivity to *the SPOT PLATINUM test*, showing the importance of carrying out complementary tests to assist owners during their routine with the animal with AD and HÁ.

Rapid diagnostic tests can be performed in the office and mainly comprise trichographic examination, parasitological skin scraping and cytological examination. However, these tests do not always allow obtaining the definitive diagnosis and skin biopsy may be necessary (Horta & Costa Val, 2013). Histopathological examination of skin biopsies is indicated for cases of erosive or ulcerative disorders of the skin, nodules and tumors, as well as when the clinical presentation suggests immunomediated diseases, zinc-responsive dermatoses or even when the lesion does not respond to treatment (Haargis & Ginn, 2007).

Among the dermatopathies, the most common allergic dermatitis, atopic dermatitis (AD), flea-bite allergic dermatitis (PPD), allergic contact dermatitis (DAC) and dietary hypersensitivity (AH) (Halliwell, 2009).

AD is genetic in nature, and an inflammatory and pruriginous disease of the dermis (Halliwell, 2009) is histologically characterized by a mild and mild perivascular mononuclear inflammatory process in the superficial dermis (Gross et al., 2005). The distal extremities and ventral regions are more affected, being their snout, face, carpal and ears (Gross et al., 2005).

AD has as characteristic inflammatory and pruriginous skin lesions, caused by an allergic reaction that affects animals with genetic predisposition. The exacerbated production of immunoglobulin E (IgE) is a defense action against environmental allergens (Marsella & Olivry, 2001). Chronic inflammation is the result of type IV hypersensitivity reaction, triggered by skin contact with allergen (Gross et al., 2005). DAC can also affect mixed dogs (White & Yu, 2006)

In the present report, it was observed that the animal started with clinical signs already with advanced age, at six years of age. The literature describes that because it is a disease of genetic characteristic, clinical signs appear in the first months of life, around six months, but clinical symptoms appear until the age of seven years. It is emphasized that about 70% of dogs develop allergic reactions between one and three years of age (Scott et al., 1996; DeBoer & Griffin, 2001). However, breeds such as Akita and Golden Retriever may have atopy before six months of age.

Allergens such as molds, dust, human epidermis, feathers, and especially domestic dust are responsible antigens for triggering DAC, promoting exaggerated immune response causing a type 1 hypersensitivity (Scott et al., 1996). AH is characterized as a non-seasonal pruriginous skin change, associated with antigenic material in the diet. Basically, any food ingredient can be an allergen for a particular patient (Nascente et al., 2006).

Most food allergens are glycoproteins, thermostable and that stimulate the production response of ige specific allergen. These glycoproteins can be recognized only after digestion or heating and preparation of food. They are almost exclusively originated by proteins (glycoproteins) and peptides that resist digestion and are absorbed intact through the mucosa. The immunological reaction present in food allergy is similar to the allergy promoted by the body's defense against infectious agents or others that may cause it damage (Nascente et al., 2006). Avoiding patient contact with allergens is the crucial point for successful treatment (Marsella & Olivry, 2001).

Commercial diets *with sensitive* names, are indicated for dogs with predisposition to dermatological problems or pathology associated with food intolerance, having in their composition ingredients selected to offer a balanced diet, maintaining the skin and healthy hair, providing nutrition that prevents dryness, irritation and skin flaking. Feed C (Table 2) has a low molecular weight protein, assisting patients with AH. Such ration presents ideal levels of salmon oil and contains diversified sources of omegas 3 and 6, which assists in skin nutrition and in the reposição dits natural oil, promoting skin health. In addition, it presents a combination of natural antioxidants, a combination of special fibers, prebiotics, probiotics and yucca extract, which help in maintaining global and intestinal health.

Hypoallergenic diets are developed without grains and have hydrolyzed meats, as pointed out in Table 2, as in the composition of Feed C, represented by composition based on fruits and vegetables, due to the greater sensitivity to animal protein of the allergic dog. In its composition, the main source of protein is hydrolyzed soybean, and the source of carbohydrates is rice. Protein hydrolysis is obtained using food-quality proteolytic enzymes. The goal of hydrolysing protein and carbon sources is to destructure proteins and carbon in the diet to remove all allergens and allergenic epitopes and thus avoid the immunological recognition of the patient already sensitized to the protein intact. A secondary goal may be to disrupt proteins to such an extent that there are no antigens capable of causing sensitization.

A tratation that vandm being applied to atopic dermatitis concerns ozone or triatomic oxygen (O_3), which is formed by three elementary oxygen atoms (O) (Nogales et al., 2008). It is a gas produced naturally in the stratosphere, slightly bluish at high concentrations and responsible for preventing excessive entry of ultraviolet radiation to the surface of planet Earth (Gimenes, 2008). It is produced from two main mechanisms: when electrical discharges occur in storms, created when an oxygen molecule (O_2) receives an electrical discharge and is broken into two oxygen atoms ($O + O$). The individual atom then reacts with O_2 ($O + O_2$), constituting a molecule of O_3 (Nogales et al., 2008). It is also produced due to ultraviolet (UV) radiation emitted by the sun, situated between the wavelength of 180 to 200 nanometers, having the same role as electrical discharges on the O_2 present in the stratosphere (Gimenes, 2008).

The gas is unstable at room temperature, exhibits half-life of almost 40 minutes when at $20^\circ C$ and spontaneously decomposes in the presence of oxygen, hindering its transport and storage (Bocci, 2006). Its water solubility is 50% higher than that of O_2 , in addition, its oxidative power is also bin faster (Pereira et

al., 2005). This oxidizing molecule reacts with any component that has carbon bonds, breaking down molecules and generating a variety of compounds (Brady & Senese, 2009).

The use of ozone gas as a therapeutic practice is justified by the power of oxidation. Animals affected by DAC are predisposed to secondary infections due to the skin barrier being sensitive. This sensitivity is proven in studies that point to transepidermal water loss and the reduction of the local concentration of ceramides, a triggering factor of the epidermal barrier defect, both in the injured skin and in theygra (Shimada et al., 2009). This epidermal barrier defect facilitates the penetration of pathogenic microorganisms such as bacteria, fungi and/or viruses; ozone is capable of causing the death of microorganisms. Additionally, it is responsible for releasing antioxidants, acting as a pro-inflammatory agent, promoting improvement of circulation and oxygenation, due to tissue penetration capacity, also promoting the reduction of platelet aggregation (Vilarindo et al., 2013).

The present study was based on the application of ozonized water, which can be applied to ulcers, wounds and several other lesions. Depending on the result expected to be achieved: disinfect or regenerate and the type of tissue where it will be applied, several concentrations can be considered, such as dissolution in water for topical application, the concentration is 0.5 to 1 ppm (Schwartz et al., 2010). It is recommended for pain relief, disinfection and for anti-inflammatory effects in acute and chronic lesions with and without infection (Viebahn-Hansler et al. , 2012).

Medicinal ozone is obtained by means of an ozone generating equipment. Oxygen (O₂) connected through a cylinder with the gas attached to the apparatus undergoes electrical discharges, transforming into two atomic oxygen (O) molecules, which reattach to oxygen molecules, originating O₃. This high frequency generator is used in skin lesion treatments (Barros et al. , 2007).

To achieve success in the application of ozone, its concentration should be verified, having a concentration variation of up to 95% oxygen and 5% ozone. Ozone therapy is reported to be based on pharmacology and not homeopathy, where ozone should be used accurately. It is important to note that its toxicity occurs only by inalatory route due to its toxic effects on the trachea and pulmonary bronchi (Bocci, 2011).

Therapeutic ozone is produced when a high voltage gradient comes into contact with pure oxygen. Because this is pure, the production of toxic compounds such as nitrogen dioxide, formed when atmospheric air is used, is avoided. There are still three industrial ways of producing ozone through generators, for use in medicine, which are: electrical discharge system that produces high concentrations of O₃. Ultraviolet production system, which produces low concentrations of O₃ (Bocci, 2006). And the cold plasma production system, used only for air and water purification (Araujo, 2006). According to Nogales et al. (2008), the ozonized solution should be prepared immediately before use due to the instability of the O₃ molecule.

Thus, ozone gas, when used as an alternative therapy in veterinary medicine, has been shown to be efficient due to its oxidative stress when interacting with lipids, increasing the endogenous production of

antioxidants. Oxidative stress is the excess of free radicals compared to the intrinsic protective system of each cell. Ozone therapy is a promising therapy due to its low cost, ease of application, absence of side effects and high rate of satisfactory results in clinical protocols (Freitas, 2011; Smith et al., 2017).

According to Bocci (2006), the mechanism of action of ozone is not completely known, since studies using ozone therapy are more concerned with knowing the therapeutic dose than in trying to understand in depth how ozone acts in the biological system.

Ozone reacts with polyunsaturated fatty acids; Antioxidants; Thiol compounds such as glutathione and albumin and, depending on the dose, also react with carbohydrates, enzymes, DNA and RNA. All these compounds act as electron donors and undergo oxidation (Bocci, 2006). According to Anagha et al. (2016), there are three possible mechanisms of action for ozone. The first is related to the inactivation of microorganisms. In fungi, O₃ blocks cell growth. In viruses, it injures the viral capsid and alters the reproductive cycle by interrupting virus-cell contact with peroxidation. In bacteria there is inhibition of the integrity of the cell wall through the oxidation of phospholipids and lipoproteins.

In the second mechanism of action, O₃ causes an increase in the rate of glycolysis of red blood cells, increasing the concentration of 2,3-diphosphoglycerate, which leads to an increase in the amount of oxygen released to tissues. Then there is a stimulation of the production of enzymes, such as prostacyclin, which act as free radical sequesters and cell wall protectors, also promoting vasodilation (Anagha et al., 2016). It is noted, however, that in the second mechanism of action, ozone represents an important function in tissue healing, returning oxygenation of the affected area. Its oxidizing action acts on the polyunsaturated fatty acids of the membrane, increasing the supply of tissue oxygen and modulating the immune system, enabling an improvement and acceleration in tissue repair.

The third mechanism of action is linked to the activation of the immune system, because ozone, when administered in concentrations between 30 and 55 µg/mL, increases the production of interferons and decreases the concentration of tumor necrosis factor (TNF) and interleukin-2, promoting local inflammatory response (Anagha et al., 2016).

4 CONCLUSION

The treatment of atopic dermatitis is lifelong, due to its genetic character and exposure of the animal to the allergic factor. Most of the time such a condition has no cure, only control. According to the findings of the present case study, it was concluded that topical ozonotherapy may be a satisfactory integrative alternative in conventional clinical protocols in the treatment of atopic dermatitis in dogs, since it was possible to observe the remission of dermatitis, significant improvement of itching and consequently herding, flaking and alopecia with the performance of sessions with hypoallergenic shampoo associated with exposure to ozonized water.

REFERENCES

- Zur, G; Ihrke, P.J; White, S.D.; Kass, P.H. Canine atopic dermatitis: a retrospective study of 266 cases examined at the University of California, Davis, 1992-1998. Part I. Clinical features and allergy testing results. *Veterinary Dermatology*, 13(2):89-102, 2002.
- Chanthick, C.; Anaman, S.; Buathet, K. The prevalence of positive intradermal allergy tests in 114 dogs with atopic dermatitis in the Bangkok metropolis, Thailand, *Veterinary Immunology and Immunopathology*, 126(3-4): 256-262, 2008.
- Barros, C.S.L. Ectima contagioso, p.98-102. In: Riet-Correa, F.; Schild, A.L.; Lemos, R.A.A; Borges, J.R. *Doenças de Ruminantes e Equinos*. 1.ed. Palloti: Santa Maria, 2008.
- Bocci, V. Scientific and Medical Aspects of Ozone Therapy. *Archives of Medical Research*, 37(4):425-435, 2006.
- Bocci, V. *Ozone: a new medical drug*. 2.ed. Springer: Londres, 2011.
- Borges, F. *Dermato-funcional: modalidades terapêuticas nas disfunções estéticas*. 1.ed. São Paulo: Phort. 2006.
- Cardoso, M. J. L., Machado, L. H. A., Melussi, M., Zamarian, T. P., Carnielli, C. M. & Júnior, J. C. M. F. (2011). Dermatopatias em cães: revisão de 257 casos. *Archives of Veterinary Science*, 16, 66-74.
- CEPAV. Disponível em <<https://www.cepav.com.br>>. Acesso em 10 nov. 2022
- Deboer, D. J.; Griffin, C. E. The ACVD task force on canine atopic dermatitis (XXI): antihistamine pharmacotherapy. *Veterinary Immunology and Immunopathology*, 81:323-329, 2001.
- Freitas, A. I. A. Eficiência da Ozonioterapia como protocolo de tratamento alternativo das diversas enfermidades na medicina Veterinária. *PUBVET*, 5:1194, 2011.
- Gross T. L.; Ihrke P. J.; Walder E. J.; Affolter V. K. *Skin diseases of the dog and cat. Clinical and histopathologic diagnosis*. 2.ed. Blackwell: Oxford, 2005.
- Haargis A. M.; Ginn P. E. The integument. In: McGavin M. M.; Zachary J. F. *Pathologic Basis of Veterinary Disease*. 4.ed. St Louis: Mosby/Elsevier. 2007
- Halliwell, R. E. W. Allergic skin diseases in dogs and cats: na introduction. *EJCAP*, 19(3): 209-211, 2009.
- Horta, R. dos S. & Costa Val, A. P. (2013). Exames complementares no diagnóstico dermatológico em pequenos animais. *Cadernos Técnicos de Veterinária e zootecnia*. Belo Horizonte: FEPMVZ Editora, 23-31.
- Macêdo, J. T. S. A; Riet-Correa, F.; Dantas, A. F. M.; Simões, S. V. D. Doenças da pele em caprinos e ovinos no semi-árido brasileiro. *Pesquisa Veterinária Brasileira*, 28:633- 642, 2008.
- Machado, M. L. S.; Appelt, C.E.; Ferreiro, L. Dermatofitos e leveduras isolados da pele de cães com dermatopatias diversas. *Acta Scientiae Veterinariae*, 32:225-232, 2004.
- Madureira, R.; Brum, J. S. Diagnóstico dermatológico em pequenos animais: o que pode influenciar? *Archives of Veterinary Science*, 22:9-19, 2017.

- Marsella, R.; Olivry, T. The ACVD task force on canine atopic dermatitis (VII): mediadores cutaneous inflammation. *Veterinary Immunology and Immunopathology*, 81: 205-213, 2001.
- Medeiros, D.; Silva, A. R.; Rizzo, J. A.; Motta, M. E.; Oliveira, F. H.; Sarinho, E. S. Total IgE level in respiratory allergy: study of patients at high risk for helminthic infection. *Journal de Pediatria (Rio J)*, 82(4):255-9, 2006.
- Meneses, A. M. C.; Ardoso M. J. L.; Franco, S. R. V. S.; Abe, K. C. Ocorrência das dermatopatias em cães e gatos. *Revista Brasileira de Ciência Veterinária*, 7:90, 2000.
- Mencalha, R. N. Atlas de dermatologia em cães e gatos – de A a Z. MedVep: Curitiba, 2019.
- Nascente, P. S.; Xavier, M. O.; Rosa, C. S.; Souza, L. L.; Meireles, M. C. A.; Mello, J, R, B. Hipersensibilidade alimentar em cães e gatos. *Clínica Veterinária*, 64:6066, 2006.
- Pereira, M. M. S.; Navarini, A.; Mimica, L. M. J.; Pacheco, A. M.; Silva, R. A. Efeito de diferentes gases sobre o crescimento bacteriano: estudo experimental "in vitro". *Revista do Colégio Brasileiro de Cirurgiões*, 32:12-14. 2005.
- Ramsey, I. K.; Tennant, B. Manual de Doenças Infecciosas em Cães e Gatos. Roca: São Paulo, 2010.
- Viebahn-Hänsler, R.; Fernández, O. S. L.; Fahmy, Z. Ozone in Medicine: The Low-Dose Ozone Concept - Guidelines and Treatment Strategies, *Ozone: Science & Engineering*, 34(6):408-424, 2012.
- Shimada, K.; Yoon, J. S.; Yoshihara, T.; Iwasaki, T.; Nishifuji, K. Increased transepidermal water loss and decreased ceramide content in lesional and non-lesional skin of dogs with atopic dermatitis. *Veterinary Dermatology*, 20:541-546, 2009.
- Scott, D. W.; Miller, W. H.; Griffin, C. E. Muller & Kirk: *Dermatologia de pequenos animais*. Rio de Janeiro: Interlivros, 1996.
- Scott, D. W.; Miller, W. H.; Griffin, C. E. Muller e Kirk's small animal dermatology. Philadelphia: W.B. Saunders, 2001,
- Smith, N.L.; Wilson, A. L.; Gandhi, J.; Vatsia, S.; Khan, S. A. Ozone therapy: an overview of pharmacodynamics, current research, and clinical utility. *Medical Gas Research*, 7: 212-223, 2017.
- Thorsteinsdottir, S.; Thyssen, J. P.; Stokholm, J.; Vissing, N. H.; Waage, J.; Bisgaard, H. Domestic dog exposure at birth reduces the incidence of atopic dermatitis. *Allergy*, 71(12): 1736–1744, 2016.
- White, S. D.; Yu, A. A. Equine Dermatology. *AAEP Proceeding*, 52:457-500, 2006.
- Willense, T. *Dermatologia clínica de cães e gatos*. Barueri: Manole, São Paulo, 2002.
- Zanon, J. P.; Gomes, L. A.; Cury, G. M. M.; Teles, T. C.; Bicalho, A. P. C. V. Dermatite atópica canina. *Semina: Ciências Agrárias* 29:905-920, 2008.