


CHAPTER 15

Nonoperative treatment of liver injury caused by firearm: a case report

 [10.56238/pacfdnsv1-015](https://doi.org/10.56238/pacfdnsv1-015)

Heloiza Fiamoncini

Medical Student
University of the Joinville Region
Rua Rio do Sul, 270, Joinville, Brazil
fiamoncini.helo@gmail.com

Djulia Adriani Frainer (Corresponding Author)

Medical Student
University of the Joinville Region
Rua Rio do Sul, 270, Joinville, Brazil
djuliafrainer@gmail.com

Carolina da Silveira Welter

General Surgery Residency
São José Municipal Hospital
Rua Dr Placido Gomes, 488, Joinville, Brazil
carol.welter@hotmail.com

Claudia Theis

General Surgery Residency
São José Municipal Hospital
Rua Dr Placido Gomes, 488, Joinville, Brazil
claudiaaaa117@gmail.com

Dayana Talita Galdino

Trauma Surgery
São José Municipal Hospital
Rua Dr Placido Gomes, 488, Joinville, Brazil
dayanatgaldino@gmail.com

ABSTRACT

Nonoperative treatment (NOT) of blunt liver injury is a widespread practice that has a high success rate (82-100%). Because of this, NOT has been used in cases of penetrating liver injury. However, despite the positive outcomes, the indication of NOT in these cases is controversial. Due to high incidence of associated thoracoabdominal injuries, this treatment modality requires a careful selection of the patient. This report presents a case of a victim of a firearm injury whose projectile was lodged in segment II of the liver, and this injury was managed with NOT, without any liver complications. However, due to its thoracic path to the abdominal cavity, it was necessary to approach the pleural empyema condition, with good evolution, without other associated complications.

Keywords: Wounds, Gunshot, Conservative Treatment, Liver, Case Reports.

1 INTRODUCTION

The liver is the most affected organ in penetrating chest trauma (40% of cases), with stabbing and firearm injuries being the main causes.^{1,2,3} In recent decades, non-operative treatment (NOT) of blunt liver injuries has been widely adopted, currently being used in about 86.3% of cases, and has a significant success rate (82-100%).^{1,4,5}

Currently, due to the good results in the non-operative treatment (NTO) of blunt liver injuries with a significant success rate (82-100%), TNO has been extended to penetrating liver injuries. However, a more rigorous selection is necessary in these cases, given that they may present associated intra-abdominal lesions, which are usually the reasons for the failure of TNO.^{4,6,7}

In this report, we present a patient with a gunshot wound, with a projectile lodged in the liver, which was chosen for TNO, progressing well and without liver complications.

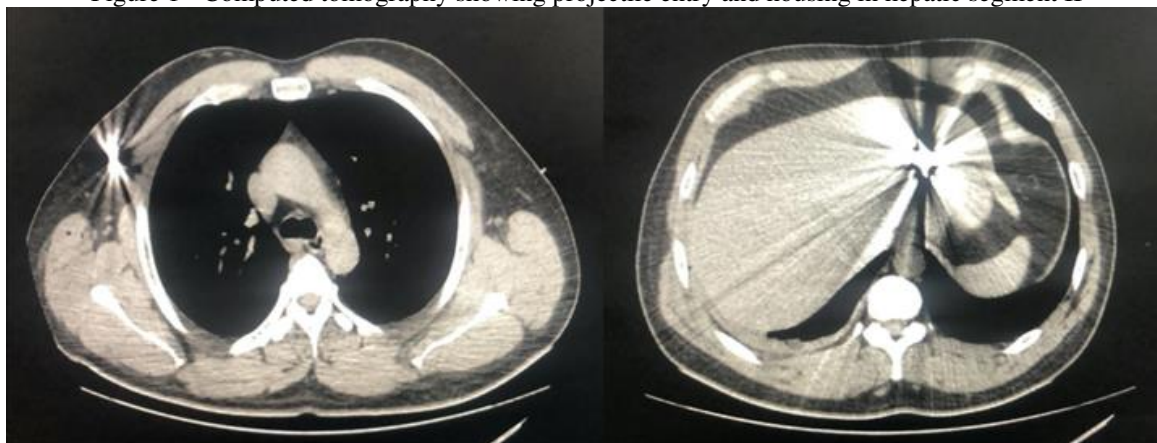
This article was registered under CAAE 45326321.8.0000.5362 and approved by the ethics committee of the proposing institution by opinion No. 4,644,920. The free and informed consent form was obtained on the use of information from the medical record and images by the patient.

2 CASE REPORT

Male patient, 38 years old. Victim of gunshot wound with entry wounds in the arm and right hemithorax and projectiles lodged in the right axillary region and in the liver. He is admitted to the emergency department with a blood pressure of 138/80 mmHg, a heart rate of 56 bpm, and a saturation of 98%. On physical examination, there is no subcutaneous emphysema or decreased chest expansion, only a slight decrease in breath sounds in the right lung base. Examination of the abdomen showed hydro-air sounds present, and the abdomen was painless on deep palpation, with no signs of peritoneal irritation. Expectant management was chosen, and the patient was monitored with strict control of vital signs, laboratory and imaging tests.

The computed tomography result showed a metallic projectile lodged in the hepatic segment II, resulting in a grade 3 hepatic lesion, with an entry path into the right hemithorax, in the seventh intercostal space, and with a trail of metallic splinters in the hepatic domus, where small hypodense foci could be seen. (Figure 1) The second projectile was lodged in subcutaneous tissue in the right axillary/pectoral region, associated with minimal right hydropneumothorax. Patient kept in absolute rest, with no indication for surgical intervention due to hemodynamic stability, opted for monitoring and follow-up with laboratory and imaging tests.

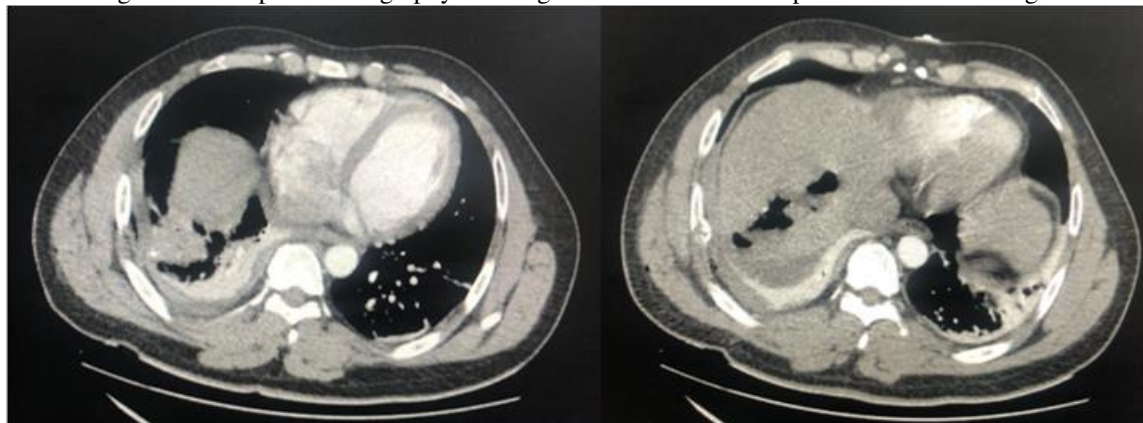
Figure 1 - Computed tomography showing projectile entry and housing in hepatic segment II



On the 2nd day of hospitalization, despite being instructed to maintain absolute rest, the patient left the bed, evolving with pain in the right hypochondrium. He maintained hemodynamic stability in the period. A new contrast-enhanced tomography of the thorax and abdomen was performed, with evidence of a small amount of basal pleural fluid on the right posterior with passive atelectasis and aerated focus in the right lower lobe in the posterior basal segment with a path through the diaphragm to the hepatic parenchyma,

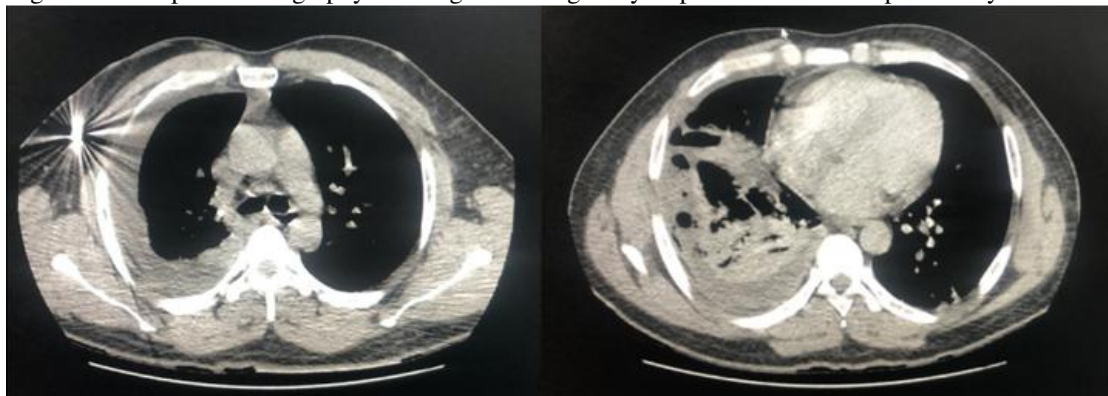
between segments VII and VIII, noting in this topography metallic residues associated with a small amount of subphrenic fluid on the right (Figure 2). Opted in conjunction with thoracic surgery to maintain conservative treatment in an intensive care bed.

Figure 2 - Computed tomography showing a small amount of subphrenic fluid on the right.



On the 4th day of hospitalization, he had a fever peak of 38°C, without changes in the leukogram. Ampicillin + sulbactam was prescribed, and an abdominal US was requested, which showed irregular hyperechogenic foci in the right hepatic lobe, subdiaphragmatic, with signs of hepatomegaly, but without evidence of fluid collection. Still without indication for surgical intervention, he was released for relative rest and discharged from the ICU. One day later, he complained of dyspnea on minor exertion, and a new tomography of the chest and abdomen was requested, which revealed worsening of hydropneumothorax and pulmonary consolidative opacities in the trajectory of the projectile, with intermingled gas bubbles, suggesting pulmonary contusion (Figure 3).

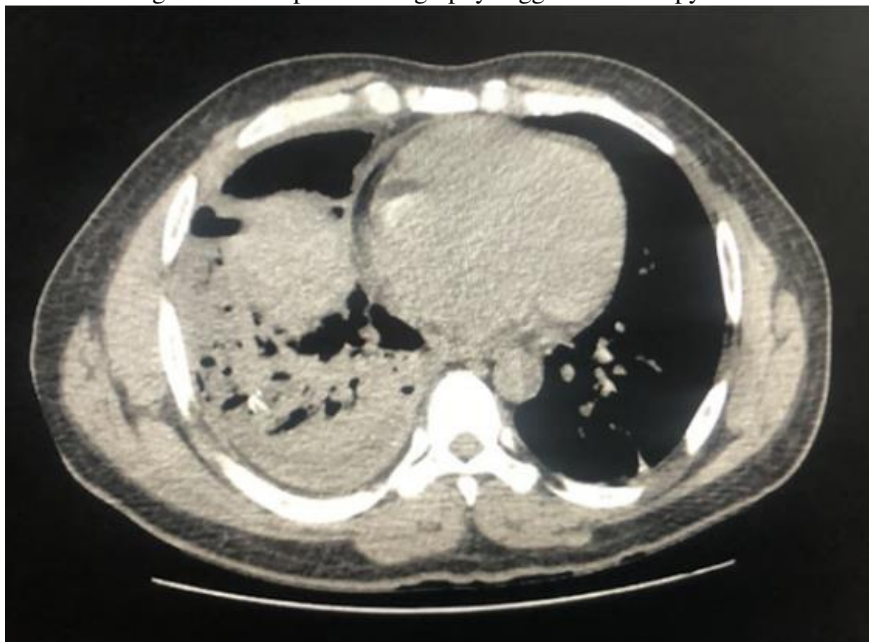
Figure 3 - Computed tomography showing worsening of hydropneumothorax and pulmonary contusion.



A decision was made for operative intervention through videothoracoscopy with evidence of septate empyema. Pulmonary decortication and anterior and posterior right chest drainage were performed, and the drains were removed on the 4th and 5th postoperative days, respectively. The patient evolved well, with a stable condition, being discharged on the 7th postoperative day. However, he returned to the emergency

department the next day with dyspnea and a fever of 39°C. A new tomography was performed and showed an increase in the pleural effusion, septate, suggestive of empyema (Figure 4). We opted for new decortication by thoracotomy and antibiotic therapy with piperacillin + tazobactam.

Figure 4 - Computed tomography suggestive of empyema.



During the second hospitalization, he presented an episode of abdominal pain, performed abdominal ultrasound with Doppler, without changes, and therefore, the follow-up of the TNO of the liver injury was chosen. This complaint improved, but fever peaks remained, and the antibiotic therapy was changed to meropenem, with which the patient showed an improvement in the clinical picture, with good evolution and hospital discharge for outpatient follow-up.

3 DISCUSSION

With the evolution of imaging tests for evaluation and diagnosis, the treatment of liver lesions has also evolved. Today, the management of most liver trauma is performed through TNO. However, the indication of TNO for cases of penetrating liver injury is still controversial, mainly due to the high possibility of other associated abdominal or thoracic injuries. Due to this reason, the selection of patients to undergo NOM should be performed with caution, despite the positive outcomes.^{2,6,7}

Among the benefits of using TNO, we can mention the reduction in the frequency of unnecessary laparotomies, which represent about 30% of all laparotomies for cases of perforating liver trauma, as well as its complications. In addition, the length of hospital stay, the need for blood transfusion and intensive care are lower. As well as mortality, when compared with surgical management. This is due to the fact that most deaths from liver trauma result from surgical complications, such as intraoperative hemorrhage and postoperative sepsis. In those hemodynamically stable patients, bleeding from isolated liver lesions usually

ceases spontaneously, for this reason NOM has high levels of success. Trunkey et al, evaluated 428 patients with perforating liver injury caused by a firearm, and found that 72% of them did not need any treatment during surgery, except for drainage. However, in view of the manipulation of the lesion, there is a possibility of bleeding due to the loss of the clot, which leads to bleeding that is difficult to control with high morbidity and mortality. ^{2,3,6,8}

Despite the many benefits, TNO has increased the incidence of late complications such as persistent hemorrhage, biliary leaks and fistulas, liver necrosis or abscesses, and abdominal compartment syndrome. However, all of these can be treated, if necessary, with interventions via laparotomy or laparoscopy, endoscopic techniques or interventional radiology. These interventions are planned and carried out outside an emergency scenario, and they are not considered a failure in the TNO, but an anticipated eventuality in the management. In addition to those mentioned above, other complications such as hemothorax, empyema, pulmonary contusion and diaphragmatic injury are also observed, and are quite frequent, which was also evidenced as a complication in this case report. ^{1,2,4,6,7.}

Even with positive results in the literature, and in this case explanation, the indication of NOM in penetrating gunshot wounds in the right thoracoabdominal transition should be carefully evaluated. Its use should only be carried out in hospitals with professionals and infrastructure for the correct monitoring of such patients. The hospital in which this patient was treated is a trauma reference in its region and, although it does not yet have its own protocol for these cases, the procedures adopted are based on the guidelines of the SBAIT (Brazilian Society for Integrated Assistance to the Traumatized). Although more studies are needed to disseminate this indication, the option to perform the TNO has been shown to be coherent and with a favorable outcome.

REFERENCES

1. Fonseca-Neto OCL, Ehrhardt R, Miranda AL. Estudo da morbimortalidade em pacientes com trauma hepático. *ABCD, arq. bras. cir. dig.* 2013;26(2):129-132.
2. Kalil M, Amaral IMA. Epidemiological evaluation of hepatic trauma victims undergoing surgery. *Rev. Col. Bras. Cir.* 2016;43(1):22-27.
3. Smaniotto B, Bahten LCV, Nogueira Filho DC, Tano AL, Thomaz JL, Fayad O. Trauma hepático: análise do tratamento com balão intra-hepático em um hospital universitário de Curitiba. *Rev. Col. Bras. Cir.* 2009;36(3):217-222.
4. Bouras AF, Truant S, Pruvot FR. Management of blunt hepatic trauma. *J Visc Surg.* 2010;147(6):351-358.
5. Létoublon C, Arvieux C. Nonoperative management of blunt hepatic trauma. *Minerva Anesthesiol.* 2002;68(4):132-7.
6. Starling SV, Azevedo CI, Santana AV, Rodrigues BL, Drumond DAF. Isolated liver gunshot injuries: nonoperative management is feasible?. *Rev. Col. Bras. Cir.* 2015;42(4):238-243.
7. Kozar RA, Moore FA, Cothren CC, Moore EE, Sena M, Bulger EM, Miller CC, Eastridge B, Acheson E, Brundage SI, Tataria M, McCarthy M, Holcomb JB. Risk factors for hepatic morbidity following nonoperative management: multicenter study. *Arch Surg.* 2006 May;141(5):451-8.
8. Trunkey DD, Shires GT, Mc Clelland R. Gestão de trauma hepático em 811 pacientes consecutivos. *Ann Surg.* 1974; 179 (5): 722-8.