


**EVALUATION OF HISTOLOGICAL CHANGES IN THE UTERUS OF RATS  
TREATED WITH ALGINATE FILM CONTAINING 17-B ESTRADIOL  
NANOPARTICLES****AVALIAÇÃO DAS ALTERAÇÕES HISTOLÓGICAS NO ÚTERO DE RATAS  
TRATADAS COM FILME DE ALGINATO CONTENDO NANOPARTÍCULAS DE  
17-B-ESTRADIOL****EVALUACIÓN DE LOS CAMBIOS HISTOLÓGICOS EN EL ÚTERO DE RATAS  
TRATADAS CON PELÍCULA DE ALGINATO QUE CONTIENE  
NANOPARTÍCULAS DE 17-B ESTRADIOL** <https://doi.org/10.56238/sevened2025.021-026>

**Adriana Yuri Koga<sup>1</sup>, Edmar Miyoshi<sup>2</sup>, João Pedro Gambetta Polay<sup>3</sup>, Bianca Cristina Cardoso<sup>4</sup>, Paulo Vitor Farago<sup>5</sup> and Leandro Cavalcante Lipinski<sup>6</sup>**

**ABSTRACT**

**OBJECTIVE:** This study aims to investigate the effect of film containing 17- $\beta$  estradiol nanoparticles on uterine tissue. The primary focus is on assessing their potential as precise hormonal therapy for skin lesions in oophorectomized rats.

**METHODS:** The research involved the development of an alginate film containing 17- $\beta$  estradiol nanoparticles. The animal assay was conducted on oophorectomized rats with dorsal skin lesions measuring 4 cm<sup>2</sup>. The rats were divided into three groups: one treated with the alginate film, the second with a film containing conventional 17- $\beta$  estradiol, and the third with a film containing 17- $\beta$  estradiol nanoparticles. Macroscopic evaluation of lesion retraction was performed, and uterine samples were stained with hematoxylin and eosin on days 7, 14, and 21.

**RESULTS:** The results showed no significant differences in the lesion retraction area among the three groups. Qualitatively, no notable uterine alterations were observed in the

<sup>1</sup> Post-Graduate Program of Health Sciences, State University of Ponta Grossa, Ponta Grossa 84030-900, Brazil  
E-mail: adri\_yuriko@hotmail.com

ORCID: <https://orcid.org/0000-0002-9690-4287>

<sup>2</sup> Post-Graduate Program of Biomedical Science, State University of Ponta Grossa, Ponta Grossa 84030-900, Brazil

E-mail: edmar@uepg.br

ORCID: <https://orcid.org/0000-0001-6159-0532>

<sup>3</sup> Medicine degree, State University of Ponta Grossa, Ponta Grossa 84030-900, Brazil

E-mail: polayjp@gmail.com

ORCID: <https://orcid.org/0000-0003-0170-1469>

<sup>4</sup> Medicine degree, State University of Ponta Grossa, Ponta Grossa 84030-900, Brazil

E-mail: bia\_onika@hotmail.com

ORCID: <https://orcid.org/0009-0007-4101-8329>

<sup>5</sup> Post-Graduate Program of Health Sciences, State University of Ponta Grossa, Ponta Grossa 84030-900, Brazil

E-mail: pvfarago@gmail.com

ORCID: <https://orcid.org/0000-0002-9934-4027>

<sup>6</sup> Post-Graduate Program of Health Sciences, State University of Ponta Grossa, Ponta Grossa 84030-900, Brazil

E-mail: lclipinski@uepg.br

ORCID: <https://orcid.org/0000-0001-5662-622X>

estrogen-treated groups and the control group, indicating the absence of hyperplasia or malignancies. However, there were statistical differences in endometrial layer thickness, primarily related to the conventional 17- $\beta$  estradiol group. Myometrial thickness analysis also showed alterations related to the nanoparticles treatment compared to the control. **CONCLUSION:** The incorporation of 17- $\beta$  estradiol nanoparticles into the alginate film, administered topically, demonstrated minimal uterine changes. This finding underscores the potential of these nanoparticles as precise hormonal therapy with reduced systemic impact when used in the treatment of skin lesions in oophorectomized rats.

**Keywords:** Healing. Nanotechnology. Estrogen. Uterus. Hormone Therapy.

## RESUMO

**OBJETIVO:** Este estudo tem como objetivo investigar o efeito do filme contendo nanopartículas de 17- $\beta$ -estradiol no tecido uterino. O foco principal é avaliar seu potencial como terapia hormonal precisa para lesões cutâneas em ratas ooforectomizadas.

**MÉTODOS:** a pesquisa envolveu o desenvolvimento de um filme de alginato contendo nanopartículas de 17- $\beta$ -estradiol. O ensaio em animais foi realizado em ratas ooforectomizadas com lesões cutâneas dorsais de 4 cm<sup>2</sup>. As ratas foram divididas em três grupos: um tratado com o filme de alginato, o segundo com um filme contendo 17- $\beta$ -estradiol convencional e o terceiro com um filme contendo nanopartículas de 17- $\beta$ -estradiol. Foi realizada uma avaliação macroscópica da retração da lesão e as amostras uterinas foram coradas com hematoxilina e eosina nos dias 7, 14 e 21.

**RESULTADOS:** Os resultados não mostraram diferenças significativas na área de retração da lesão entre os três grupos. Qualitativamente, não foram observadas alterações uterinas notáveis nos grupos tratados com estrogênio e no grupo controle, indicando a ausência de hiperplasia ou malignidade. No entanto, houve diferenças estatísticas na espessura da camada endometrial, principalmente em relação ao grupo do 17- $\beta$ -estradiol convencional. A análise da espessura do miométrio também mostrou alterações relacionadas ao tratamento com nanopartículas em comparação com o controle.

**CONCLUSÃO:** A incorporação de nanopartículas de 17- $\beta$ -estradiol no filme de alginato, administrado topicamente, demonstrou alterações uterinas mínimas. Esse achado ressalta o potencial dessas nanopartículas como terapia hormonal precisa com impacto sistêmico reduzido quando usadas no tratamento de lesões cutâneas em ratas ooforectomizadas.

**Palavras-chave:** Cura. Nanotecnologia. Estrogênio. Útero. Terapia hormonal.

## RESUMEN

**OBJETIVO:** Este estudio pretende investigar el efecto de las nanopartículas de 17- $\beta$  estradiol en el tejido uterino. El objetivo principal es evaluar su potencial como terapia hormonal precisa para las lesiones cutáneas en ratas ooforectomizadas.

**MÉTODOS:** La investigación consistió en el desarrollo de una película de alginato que contiene nanopartículas de 17- $\beta$  estradiol. El ensayo con animales se realizó en ratas ooforectomizadas con lesiones cutáneas dorsales de 4 cm<sup>2</sup>. Las ratas se dividieron en tres grupos: uno tratado con la película de alginato, el segundo con una película que contenía 17- $\beta$  estradiol convencional y el tercero con una película que contenía nanopartículas de 17- $\beta$  estradiol. Se realizó una evaluación macroscópica de la retracción de la lesión, y las muestras uterinas se tiñeron con hematoxilina y eosina los días 7, 14 y 21.

**RESULTADOS:** Los resultados no mostraron diferencias significativas en el área de retracción de la lesión entre los tres grupos. Cualitativamente, no se observaron alteraciones uterinas notables en los grupos tratados con estrógenos y en el grupo de control, lo que indicaba la ausencia de hiperplasia o neoplasias malignas. Sin embargo, hubo diferencias estadísticas en el grosor de la capa endometrial, principalmente relacionadas con el grupo de estradiol 17- $\beta$  convencional. El análisis del grosor del

miometrio también mostró alteraciones relacionadas con el tratamiento con nanopartículas en comparación con el control.

**CONCLUSIÓN:** La incorporación de nanopartículas de 17- $\beta$  estradiol en la película de alginato, administrada por vía tópica, demostró cambios uterinos mínimos. Este hallazgo subraya el potencial de estas nanopartículas como terapia hormonal precisa con un impacto sistémico reducido cuando se utilizan en el tratamiento de lesiones cutáneas en ratas ooforectomizadas.

**Palabras clave:** Curación. Nanotecnología. Estrógenos. Útero. Terapia Hormonal.

## INTRODUCTION

The aging process promotes various physiological hormonal changes in the body. For women, menopause typically occurs between the ages of 45 and 55, marked by a decline in endogenous estrogen production. Consequently, delayed scarring can be related to the reduction in the steroid hormone<sup>1,2</sup>.

Nanoparticles offer an alternative to assist the healing process. In the clinical-laboratory context, nanoparticles are small particles on a nanometric scale ( $10^{-9}$  meters), designed for medical applications like diagnosis, treatment, and drug delivery. This technology provides unique properties that can be harnessed to enhance effectiveness and safety in medicinal therapy<sup>3</sup>.

The topical administration of drugs in nanoparticulate form has advantages in treating lesions, including minimal systemic effects. The key characteristics of these compounds should involve factors such as easy application, a consistent release rate of the active ingredient, and the absence of first-pass metabolism<sup>4,5</sup>.

The formulation with 17- $\beta$  estradiol (E2), the primary estrogen predominantly produced by the ovarian follicle and directly related to the reproductive cycle, may offer advantages in lesion treatment. Emphasizing topical application, 17- $\beta$  estradiol in its active form exhibits favorable effects such as stimulating epithelialization, proteolytic enzymatic action, and assisting in the inflammatory phase of wound healing<sup>6,7,8</sup>.

Moreover, estrogen plays a direct role in uterus, given the expression of estrogen receptors in endometrial cells, stimulating epithelial and stromal cell proliferation, leading to an increase in endometrial thickness, particularly during the proliferative phase of the menstrual cycle<sup>9</sup>.

Estrogen is also associated with the development of secondary sexual characteristics, increased body metabolism, fat deposition, and bone stimulation. However, excessive estrogen exposure can lead to undesirable effects, including morphofunctional uterine alterations as dysplasia and an increased risk of endometrial cancer<sup>9</sup>.

Analyzing topical therapy is a significant field of study, examining the delivery of 17- $\beta$  estradiol to tissues in this form, while also assessing systemic repercussions. Hence, hormone administration in nanoparticles, compared to its conventional form, is essential in terms of bioavailability and the ability to target treatment to specific body locations, potentially minimizing side effects<sup>10-12</sup>.

In this perspective, considering the effects of estrogen on cutaneous healing and the overall organism, it is of interest to measure the relationship between the risk and benefit of topical therapy containing 17- $\beta$  estradiol, analyzing potential systemic repercussions as

adverse events in an animal trial. Therefore, this study aims to assess possible changes in uterine tissue in rats treated with alginate film containing 17- $\beta$  estradiol nanoparticles.

## METHODS

### OBTAINING POLYMERIC NANOCAPSULES CONTAINING E2

According to the methodology available in literature<sup>13</sup>, the process involved the preparation of nanocapsule suspensions using 100 mg of Poly $\epsilon$ -caprolactone dissolved in 30 mL of acetone. This was combined with 0.077 g of Span<sup>®</sup> 80, 50 mg of 17- $\beta$  estradiol (E2), and 0.33 g of medium-chain triglycerides, with stirring for 10 minutes. The aqueous phase comprised 0.077 g of Tween<sup>®</sup> 80 and 53 mL of distilled water. The organic phase was gradually added to the aqueous phase with constant magnetic stirring at 40°C. The resulting nanoemulsion was stirred for an additional 10 minutes. The organic solvent was removed by evaporation under reduced pressure at 40°C, yielding a concentrated 10 mL sample.

### OBTAINING FILMS FOR TOPICAL APPLICATION

Therapeutic adhesive films were formulated from a solution containing 4.5 g of alginate and 12 g of glycerin solubilized in 300 mL of distilled water, with constant stirring. This resulted in 12 plates, each containing 25 mL of the solution. Three types of films were obtained: the control, consisting only of alginate; the second contained alginate with the addition of conventional E2 (0,06%), named ECF 0,06; and the third, alginate with nanoparticulate E2 (0,06%), named ENF 0,06.

### ANIMAL ASSAY

Forty-five female Wistar rats weighing approximately 250 g were utilized, housed in plastic cages with Nutival<sup>®</sup> feed and water ad libitum, at a controlled temperature ( $22 \pm 2^\circ\text{C}$ ), and a 12-hour light/dark cycle. Sample size calculation considered the mean and standard deviation of data found in the literature, with a test power of 95%, and an additional 10% was added to the total for any losses during the experiment.

### OOPHORECTOMY AND SKIN LESION

Animals underwent bilateral oophorectomy following a fasting period of 2 hours without water and 4 hours without food. Anesthesia was induced with intraperitoneal injections of ketamine hydrochloride (40 mg/kg) and xylazine hydrochloride (5 mg/kg). Ovaries were clamped with hemostatic forceps and ligated with absorbable 4-0 thread for

gonad removal. The wounds were sutured, and fentanyl citrate (2 mg/kg) was administered for analgesia and anesthetic recovery. After 45 days of bilateral oophorectomy, 4 cm<sup>2</sup> square lesions were created in the cervicolombar region using the same preoperative anesthetic protocols and postoperative analgesia as oophorectomy. Skin lesions remained open for the experiment.

## TREATMENT

The therapeutic adhesive was applied immediately after creating the lesions, with each group receiving their respective treatment. After 24 hours, each adhesive was replaced in the same location.

## EVALUATION OF WOUND RETRACTION

Animals were anesthetized with inhaled isoflurane and positioned under a standardized photographic support. Lesions were photographed immediately after the procedure (time 0) and on the 7th, 14th, and 21st days after the lesion. The Image J program was used to measure the retraction area.

## EUTHANASIA

After 7, 14, and 21 days, five animals from each group were euthanized with an intraperitoneal injection of an overdose of ketamine and xylazine. Perilesional skin and uterus were collected, along with blood extraction through cardiac puncture.

## HISTOLOGICAL ANALYSIS

The uterus was collected during euthanasia, fixed with 10% (v/v) formalin, dehydrated, embedded with paraffin, and sectioned with a 3μm microtome. Hematoxylin and Eosin were used for staining, and sections were photographed for analysis of qualitative changes in each layer. The Image J software was used for myometrial and endometrial thickness analysis. Perimetrium analysis was not considered. Mean and standard deviation were calculated for statistical analysis.

## STATISTICAL ANALYSIS

Lesion area analysis, qualitative exploration, and uterine thickness measurement were performed by two independent evaluators. Statistical evaluation was done using GraphPad Prism 6 software with analysis of variance (ANOVA) for multiple comparisons and the Turkey test, maintaining a 95% confidence interval ( $p \leq 0.05$ ).

## RESULTS

### WOUND RETRACTION

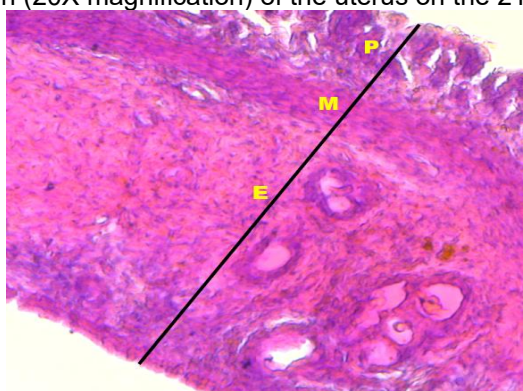
The study's results on wound retraction processes did not reveal statistical differences among the analyzed groups, potentially linked to the small lesion area. Histological evaluation is crucial to supplement these findings, detailing the presence of myofibroblasts and collagen deposition.

### UTERINE QUALITATIVE ANALYSIS

Microscopic visualization of the uterus stained with Hematoxylin and Eosin did not reveal qualitative changes related to abnormal cell proliferation, metaplasia, or oncogenic lesions on the 7th, 14th, and 21st days in both the control and treated groups.

In the groups treated with topical estrogen film, besides the absence of atypias in uterine tissue, there were no variations compared to the control group, and each uterine layer could be distinguished. The histological image of a representative sample from the EN 0,06 group, considering the 21st treatment day, is illustrated in Figure 1.

**Figure 1:** Photomicrograph (20X magnification) of the uterus on the 21sts day of ENF 0,06 group.



**Source:**The author. E: Endometrium. M: Myometrium. P: Perimetrium.

### UTERINE LAYER THICKNESS

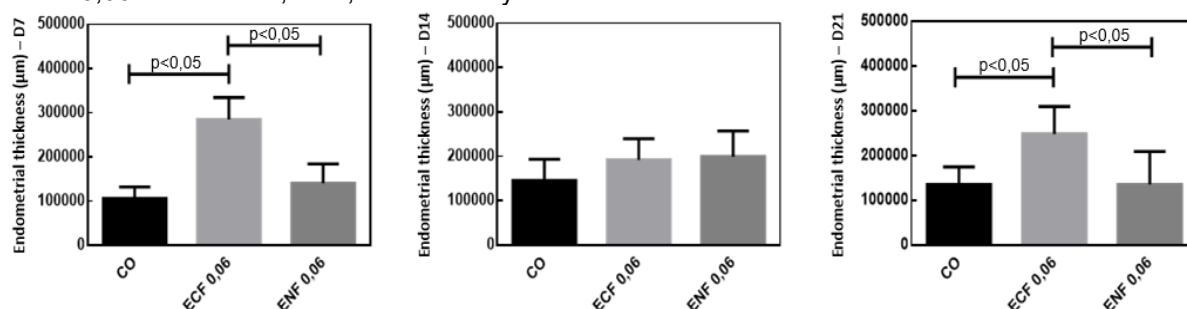
The quantitative evaluation of endometrial dimensions across the 7th, 14th, and 21st days is visually represented in the comprehensive graphical depiction provided in Figure 2. On the initial assessment at the 7th day of treatment, the cohort subjected to nanoparticulate estrogen manifested endometrial values closely aligned with those of the control group. Both of these values were significantly lower when juxtaposed with the corresponding metric observed in the group treated with conventional estrogen.

Transitioning to the 14th day, a discernible convergence in endometrial measurements across the various treatment groups is discerned. The 21st day, reveals that



the film incorporating 17- $\beta$  estradiol in its conventional form displayed a heightened endometrial thickness, surpassing not only the control group but also the group treated with nanoparticle-based estrogen. This distinction reached statistical significance, emphasizing the nuanced and time-dependent impact of different estrogen formulations on endometrial dynamics.

**Figure 2:** Comparative measurements of endometrial thickness ( $\mu\text{m}$ ) between the Control Group, ECF 0,06 and ENF 0,06 over the 7th, 14th, and 21st day.



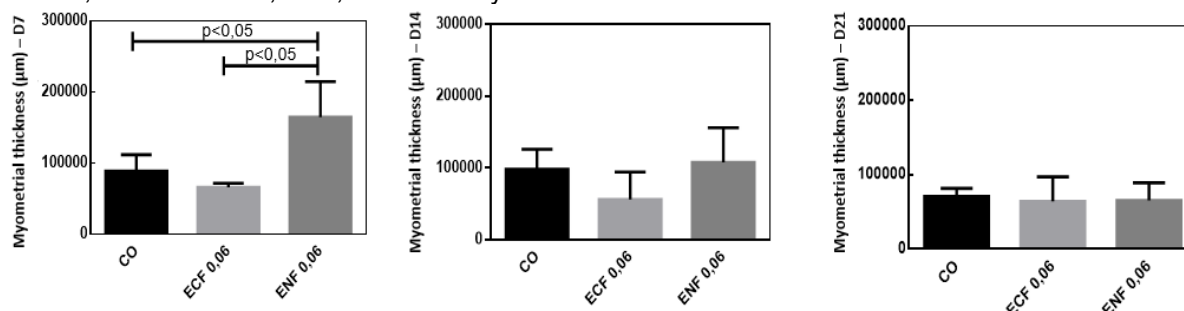
Myometrial tissue, a critical component of the uterus, demonstrates a notable sensitivity to estrogen, rendering histological analysis an apt approach for discerning the impacts of estrogen nanoparticles. The elucidation of inter-group disparities is depicted in Figure 3. Notably, after seven days of treatment, rats subjected to nanoparticle administration exhibited a larger myometrium in comparison to both the control group and those treated with the conventional form of estrogen, presenting statistical significance.

On the 14th day, the values pertaining to the group treated with nanoparticulate estrogen approached with the control group, albeit surpassing those of the group treated with the conventional form. This trend continued on the 21st day of treatment, wherein comparable measurements were observed across all groups, indicating an absence of statistically significant differences.

The temporal evolution of myometrial responses to estrogen, particularly when delivered through nanoparticle formulations, underscores the dynamic nature of such treatments and warrants further investigation for a comprehensive understanding of their implications.



**Figure 3:** Comparative measurements of myometrial thickness ( $\mu\text{m}$ ) between the Control Group, ECF 0,06 and ENF 0,06 over the 7th, 14th, and 21st day.



## DISCUSSION

Alginate films demonstrate promising wound healing properties when applied independently, attributed to their biocompatibility, the ability to maintain a moist wound environment, and controlled release of growth factors<sup>10-12</sup>. Conversely, estrogen exhibits similar characteristics by modulating the inflammatory response, stimulating collagen production, and promoting tissue neovascularization. This is underscored by the increased likelihood of hypertrophic scars and keloids during menopause<sup>1,2,10-12</sup>.

Wound retraction directly correlates with fibroblast activity, elongated mesenchymal cells found in various tissues. These cells play a vital role in collagen production (types I and III) and processes like tissue regeneration, stem cell maintenance, wound healing, and lesion repair. In the retraction phase, fibroblasts transform into myofibroblasts after the initial inflammatory phase, playing a direct role in this process<sup>1,2,10-12</sup>.

In many organs, tissue injury activates local fibrocytes, which, in the presence of growth factors from macrophages, differentiate into contractile myofibroblasts. These cells express smooth muscle  $\alpha$ -actin ( $\alpha$ -SMA), enabling contraction and enzyme production for extracellular matrix degradation, crucial in regulating repair mechanisms. The interactions of myofibroblasts with the extracellular matrix impact tissue mechanical properties, and their persistence may lead to excessive scar fibrosis, compromising organ function<sup>1,2,10-12</sup>.

Hormonal drugs, widely used in clinical practice, can cause undesired systemic alterations. Such changes may be related to side effects; therefore, these medications must undergo thorough risk-benefit evaluation before prescription<sup>11,14-16</sup>.

Endometrial hyperplasia can result from non-opposed estrogen therapy, as well as endometrial cancer. Moreover, Hormone Replacement Therapy, prescribed during menopause, may increase the risk of breast cancer and abnormal uterine bleeding as side effects. Additionally, prolonged use of GnRH antagonists can lead to uterine atrophy due to the suppression of sex hormones<sup>15,16</sup>.

Estrogenic activity in the uterus primarily occurs through binding to estrogen nuclear receptors ER $\alpha$  and ER $\beta$ . In the endometrium, the predominant is ER $\alpha$ , which, in the presence of estrogen, stimulates the proliferation of stromal cells during the proliferative phase<sup>9</sup>.

The difference in endometrial measurements may be related to the ability of nanoparticles to provide controlled release and a more targeted effect, which, in this case, is the cutaneous scar tissue rather than the endometrium<sup>10-12</sup>. The results demonstrated that conventional form treatment has a greater stimulus on the endometrial tissue, suggesting a greater predisposition to significant changes such as abnormal cell proliferation.

Changes in female sex hormones may be related to the development of leiomyomas, as estrogen and progesterone have the effect of increasing progesterone receptors and proliferating neoplastic cells, respectively<sup>14,15</sup>. It is worth noting that in the qualitative analysis, no histological changes suggestive of abnormal alterations were observed in the myometrial layer. In this perspective, this result may be related to the isolated use of estrogen, employed at a low concentration and controlled release.

The programmed and targeted release of estrogen can avoid constant and high stimuli throughout the treatment. This characteristic is capable of preventing abnormal proliferations and pathological thickening in the myometrial layer over the days<sup>10-12</sup>.

## CONCLUSION

The use of nanotechnology is a promising alternative for the treatment of cutaneous lesions, as the nanoparticles enriched with 17- $\beta$  estradiol at a concentration of 0,06%, administered in the form of a topical film, did not exhibit harmful characteristics to uterine tissue, especially on the 21st day of treatment. Thus, morphofunctional uterine changes were not observed in this study.

In this regard, the results of these studies emphasize the therapeutic potential of the film containing 17- $\beta$  estradiol nanoparticles. The ability to provide more precise treatments, with less impact on estrogen-sensitive tissues, represents a significant advancement in the field of hormonal drug therapy.

## ETHICS COMMITTEE APPROVAL

Ethics committee approval was received for this study from State University of Ponta Grossa Animal Research Ethics Committee (approval date: 10.02.22; approval number: 21.000062988-0)

## REFERENCES

1. Mukai K, Nakajima Y, Asano K, Nakatani T. Topical estrogen application to wounds promotes delayed cutaneous wound healing in 80-week-old female mice. *PLOS ONE* 2019;4(11):e0225880.
2. Rajan S, Kreatsoulas C. A review of menopausal hormone therapy: recalibrating the balance of benefit and risk. *Polish Archives of Internal Medicine* 2019;129(4):276-80.
3. Saeednia L, Yao L, Asmatulu R. Chitosan and fullerene hybrid hydrogel for drug delivery system with enhanced antitumor cell effects. *Materials Today: Proceedings* 2022;71:130–7.
4. Tocco I, Zavan B, Bassetto F, Vindigni V. Nanotechnology-Based Therapies for Skin Wound Regeneration. *Journal of Nanomaterials* 2012;2012:1–11.
5. Raszevska-Famielec M, Flieger J. Nanoparticles for Topical Application in the Treatment of Skin Dysfunctions-An Overview of Dermo-Cosmetic and Dermatological Products. *Int J Mol Sci* 2022;23(24):15980.
6. Brufani, M. Rizzi N, Meda C, Filocamo L, Ceccacci F, D'Aiuto V, Bartoli G, La Bella A, Migneco LM, Bettolo RM, Leonelli F, Ciana P, Maggi A. Novel Locally Active Estrogens Accelerate Cutaneous Wound Healing-Part 2. *Scientific Reports* 2017;7(1):2510.
7. Lobo RA. Menopause and Aging. *Yen and Jaffe's Reproductive Endocrinology*. Elsevier 2019;9:322-56.
8. Di Florio DN, Sin J, Coronado MJ, Atwal PS, Fairweather D. Sex differences in inflammation, redox biology, mitochondria and autoimmunity. *Redox Biol* 2020;31:101482.
9. Aplin JD. Uterus—Endometrium. 2. Ed. *Encyclopedia of Reproduction*. Elsevier 2018.
10. Ilves M, Palomäki J, Vippola M, Lehto M, Savolainen K, Savinko T, Alenius H. Topically applied ZnO nanoparticles suppress allergen induced skin inflammation but induce vigorous IgE production in the atopic dermatitis mouse model. *Part Fibre Toxicol* 2014;14:11-38.
11. Goyal R, Macri LK, Kaplan HM, Kohn J. Nanoparticles and nanofibers for topical drug delivery. *J Control Release* 2016;28(240):77-92.
12. Fuentes N, Silveyra P. Estrogen receptor signaling mechanisms. *Adv Protein Chem Struct Biol* 2019;116:135-69.
13. Koga AY. Desenvolvimento, caracterização e avaliação da atividade cicatrizante de nanopartículas contendo 17- $\beta$ -estradiol e/ou óxido de zinco [dissertação]. Ponta Grossa: Universidade Estadual de Ponta Grossa, 2021.
14. Bulun SE, Moravek MB, Yin P, Ono M, Coon JS 5th, Dyson MT, Navarro A, Marsh EE, Zhao H, Maruyama T, Chakravarti D, Kim JJ, Wei JJ. Uterine Leiomyoma Stem Cells: Linking Progesterone to Growth. *Semin Reprod Med* 2015;33(5):357-65.
15. Moroni R, Vieira C, Ferriani R, Candido-Dos-Reis F, Brito L. Pharmacological treatment of uterine fibroids. *Ann Med Health Sci Res* 2014;4(3):S185-92.

16. Nees LK, Heublein S, Steinmacher S, Juhasz-Böss I, Brucker S, Tempfer CB, Wallwiener M. Endometrial hyperplasia as a risk factor of endometrial cancer. Arch Gynecol Obstet 2022;306(2):407-421.
17. Pan M, Zhou J, Pan X, Wang J, Qi Q, Wang L. Drugs for the treatment of postmenopausal symptoms: Hormonal and non-hormonal therapy. Life Sci 2023;1(312):121255.